

RADICAL CYSTECTOMY IN THE MALE

9

EXPOSURE

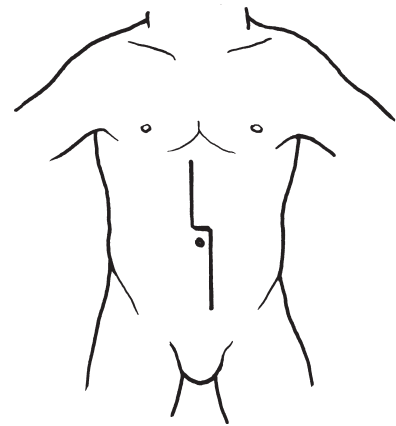
FIGS. 9-1 AND 9-2. The midline incision should incorporate the dissection of the urachus from the umbilicus.

FIG. 9-3. Proper bowel mobilization and packing for good exposure are essential in this operation. The lines of Toldt lateral to the colon are divided on both sides. On the *right side*, this incision extends around the cecum up to the mesenteric root toward the ligament of Treitz. On the *left side*, the descending colon and the sigmoid colon are mobilized, and a tunnel

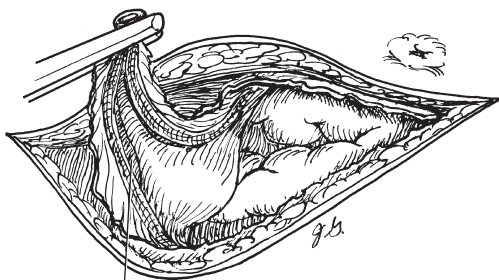
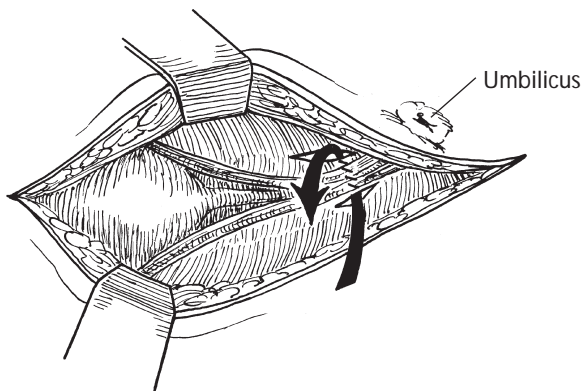
behind the sigmoid colon is immediately created with blunt dissection in preparation for the left ureteral mobilization to the right side.

Both ureters should be isolated with vessel loops.

Three dry laparotomy pads—one on each gutter (1 and 2) and one in the middle (3)—cover the bowel, and this in turn is covered by a dry towel (4). The dry towel is “unrolled” down over the three laparotomy pads and tucked up to each lateral gutter to prevent the bowel from slipping into the operative field.

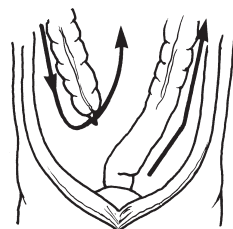


9-1



Urachus
dissected free

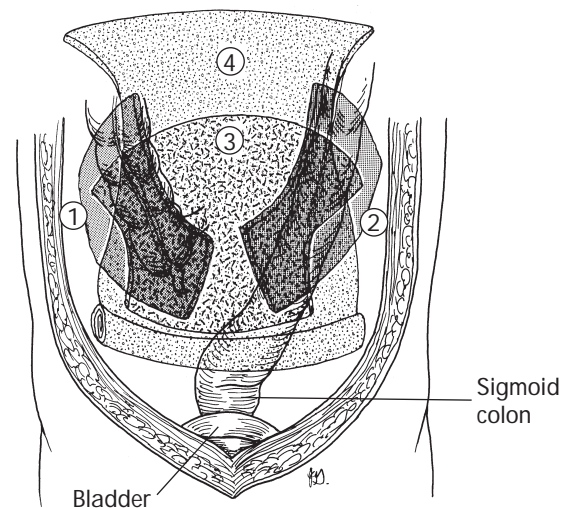
9-2



Incision of parietal peritoneum
for bowel mobilization

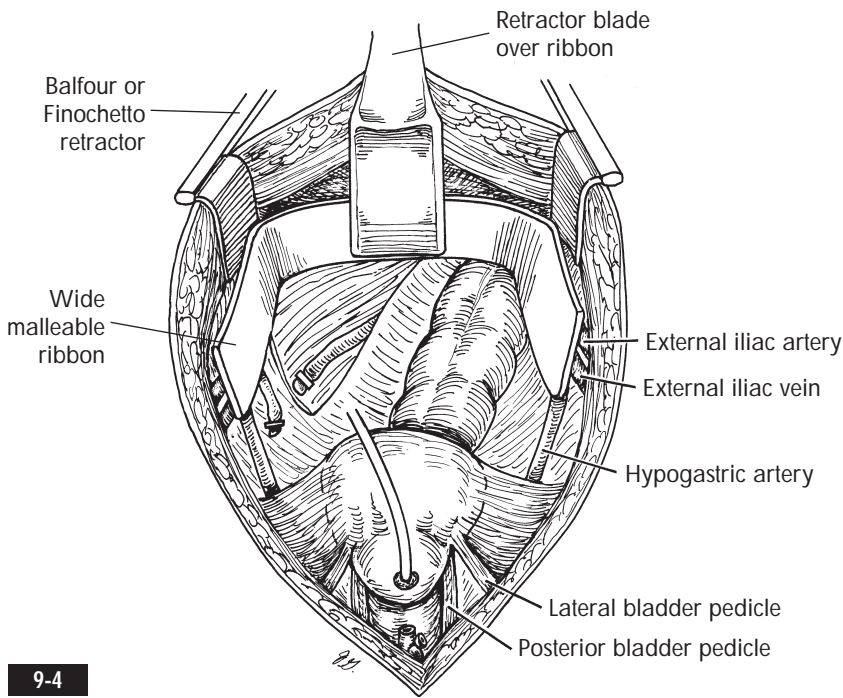
9-3

Laparotomy Pads and
Towel Packing of Bowel

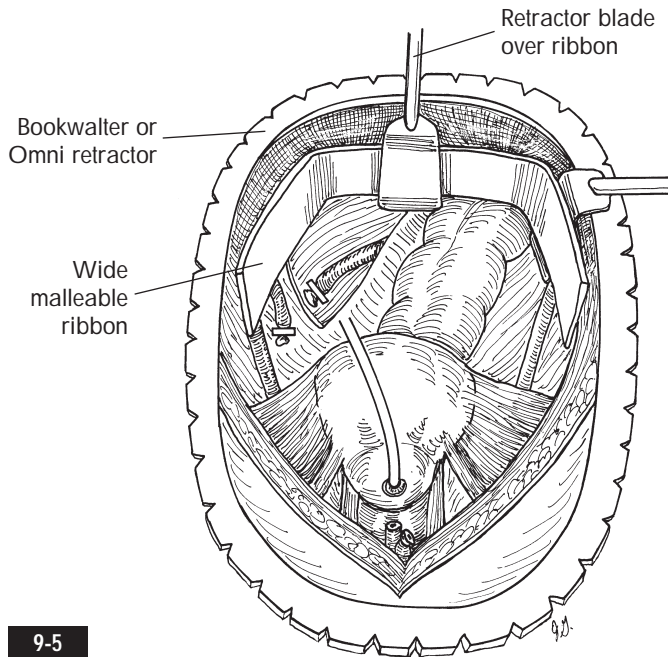


Bladder

Sigmoid
colon



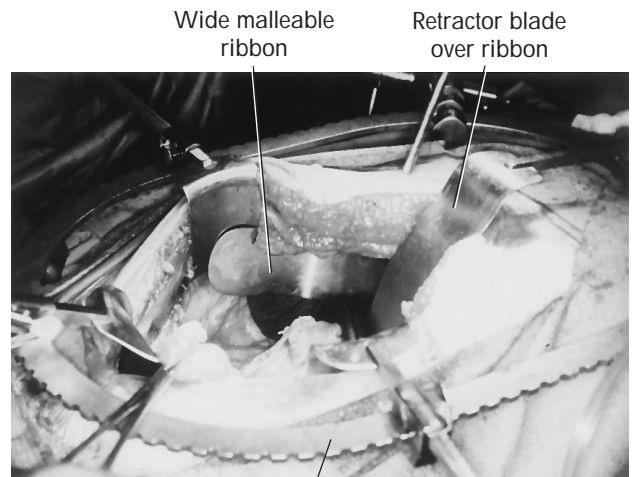
9-4



9-5

FIGS. 9-4, 9-5, AND 9-6. With a large Bookwalter, Balfour Grieshe, Finochetto, or Omni retractor in place, the surgeon can place a wide, malleable ribbon in the shape of a half-rectangle or semi-circle configuration into the operative field to keep the bowel packing cephalad. The illustrations show a later stage of the operation, but the exposure, in which the ribbon with the retractor is incorporated, facilitates the entire pelvic dissection.

After the lymphadenectomy, the ureters are divided and clipped at the proximal opening. This maneuver permits the ureters to dilate, facilitating the ureterointestinal anastomosis. Frozen section biopsy of the distal ureters is performed to determine cancer involvement.



9-6

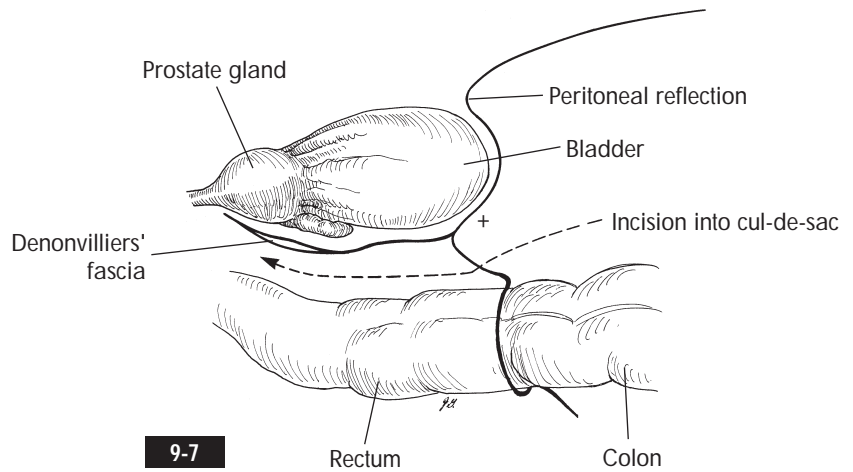
PROXIMAL POSTERIOR DISSECTION AFTER LYMPHADENECTOMY AND URETERAL DIVISION

FIG. 9-7. We prefer first to divide the posterior peritoneum (cul-de-sac) and establish the dissection plane between the rectum and the bladder before dividing the four pedicles. It is critical to incise the peritoneal reflection at the cul-de-sac on the rectal side rather than on the bladder side. This ensures that a proper dissection plane is established between the rectum on one side and the bladder, prostate gland, and Denonvilliers' fascia on the other side (*arrow*).

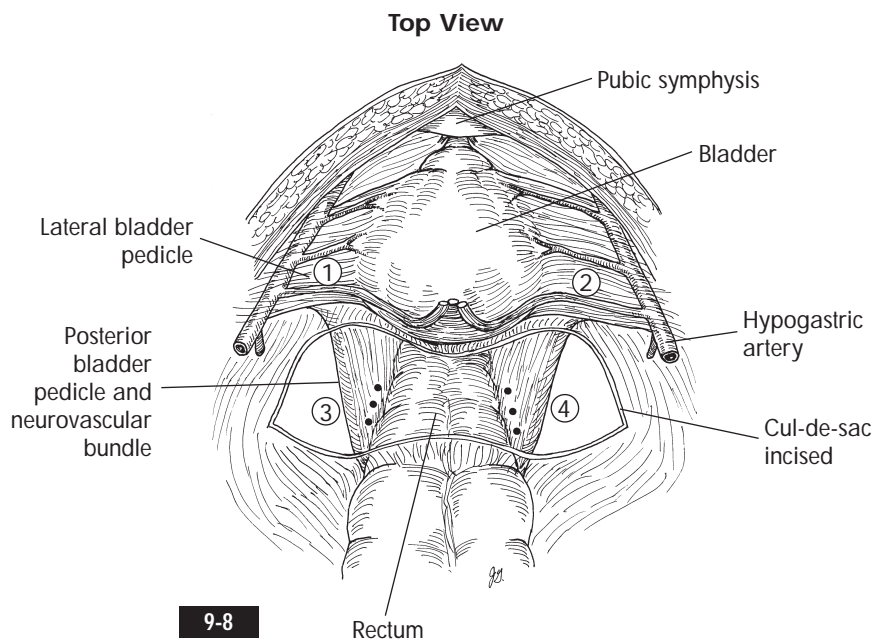
After dividing the peritoneum, the surgeon uses blunt dissection to establish a definite space between the prostate/bladder and the rectum. The surgeon should be able to palpate the Foley catheter balloon inside the bladder.

FIGS. 9-8 AND 9-9. By performing this dissection, the surgeon can now identify the lateral (1 and 2 in Fig. 9-8) and posterior (3 and 4 in Fig. 9-8) bladder pedicles on both sides.

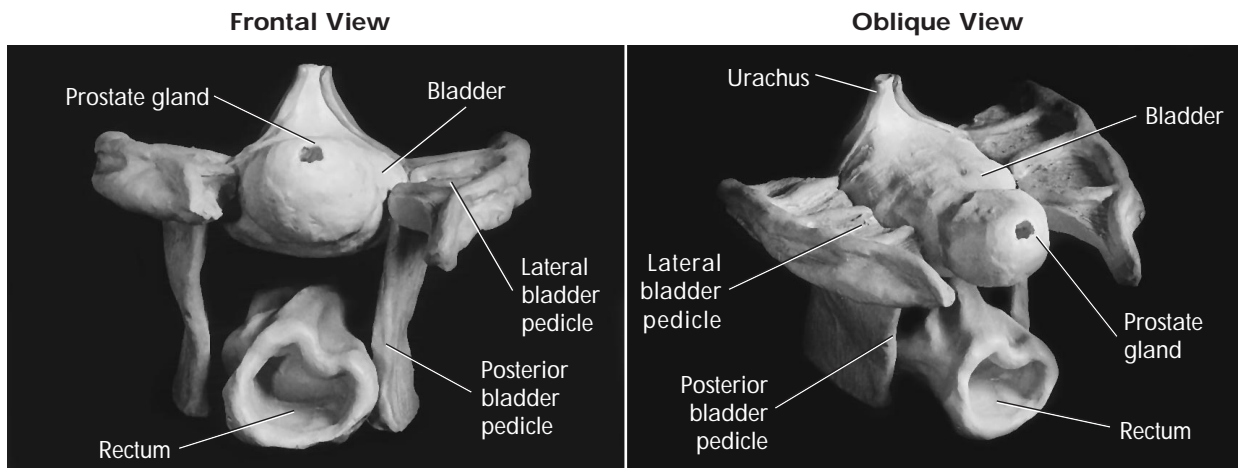
The neurovascular bundles for potency are located in the posterior pedicles at the level of the seminal vesicles (*dots* on posterior pedicles in Fig. 9-8). The Foley catheter balloon is palpated at the same level.¹



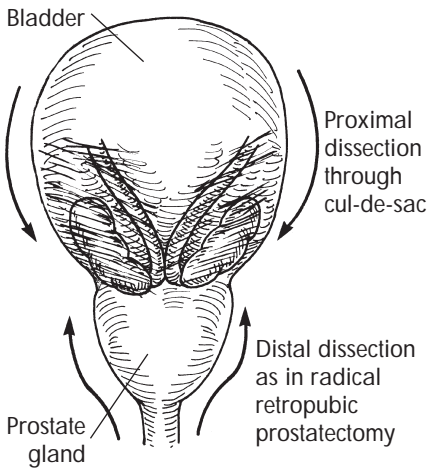
9-7



9-8



9-9



9-10

DISTAL /ANTERIOR DISSECTION

FIG. 9-10. The surgeon focuses now on the distal/anterior end at the prostatic apex and performs the same maneuvers as in radical retropubic prostatectomy (see p. 170).²

FIGS. 9-11 AND 9-12. The surgeon opens the endopelvic fascia bilaterally, divides the puboprostatic ligaments if wide, and then ligates and divides the dorsal venous complex. Alternatively, the surgeon can incorporate a tie (1-0 Vicryl) around the dorsal venous complex and the puboprostatic ligaments as one unit and divide the structures proximal to the tie (see p. 178).

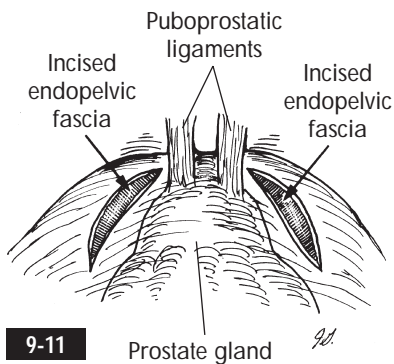
The urethra is isolated and two ties (0 silk) are placed, securing the urethra to the Foley catheter proximally. The urethra and Foley catheter are divided distal to the

ties. Urethrectomy is performed simultaneously from below or postponed.

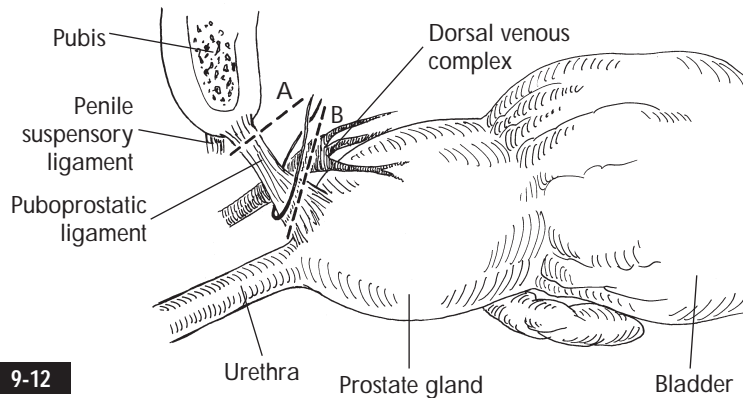
The free end of the cut Foley catheter is retracted up, thereby retracting the prostate gland cephalad and exposing Denonvilliers' fascia and the seminal vesicles beneath. The lateral prostatic pedicles should be divided.

FIG. 9-13. Using both hands, the surgeon can now feel a thin web of tissues separating the proximal and distal dissections. This thin web is punctured with the surgeon's fingers. It is important to puncture the thin layer of tissues *closest* to the prostate gland and bladder side to avoid injury to the rectum (see p. 268).

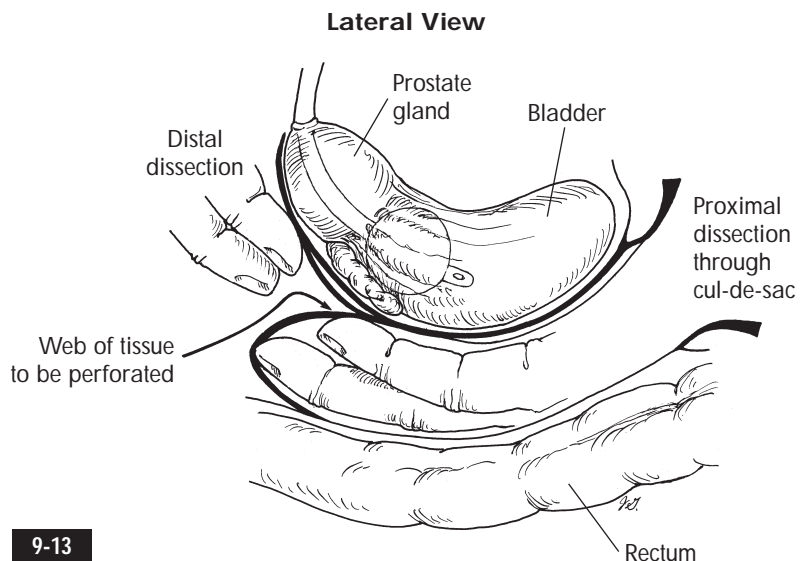
The surgeon can now lift the prostate gland and bladder, defining the bladder pedicles for division.



9-11



9-12



9-13

TRADITIONAL DIVISION OF LATERAL AND POSTERIOR BLADDER PEDICLES

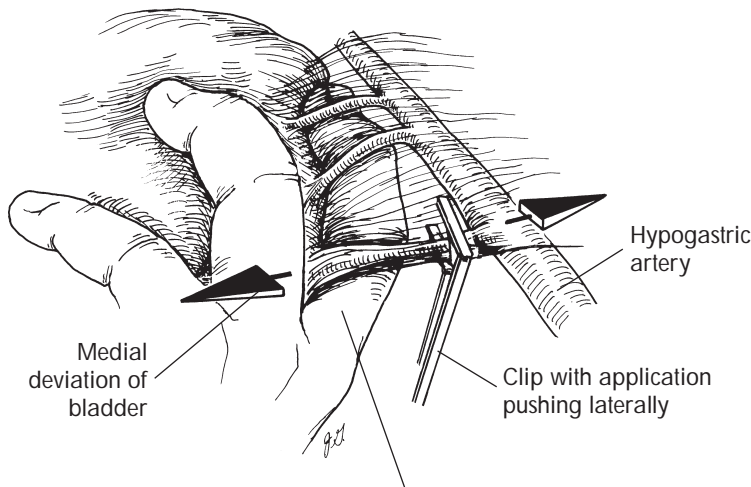
The right-handed surgeon is positioned at the patient's left side for the entire operation.

FIG. 9-14. Using the left hand to hold the bladder and rectum medially, the surgeon can slide the index finger and middle finger adjacent to the right hypogastric artery. Both the index finger and the middle finger pull the bladder and rectum medially, thereby exposing the right lateral pedicle. If the lateral pedicle is thick and fatty, the surgeon can use a finger-pinching maneuver whereby the thumb compresses the fatty tissue against the index and middle fingers to "thin out" the pedicle for easier ligation and division.

If not concerned with potency, the surgeon can ligate the entire hypogastric artery distal to the superior gluteal artery. If the goal is to preserve potency and the tumor does not invade the lateral walls of the bladder, the surgeon can divide the obliterated umbilical artery and the vesical arteries and preserve the main hypogastric artery.

FIG. 9-15. Optimal clipping means the placement of two clips 1 cm apart on the proximal end, with a 1 cm margin on the free end to avoid clip slippage. The surgeon uses the left hand to mobilize the bladder and rectum medially while using the right-angle clip applicator to ligate the right lateral bladder pedicle.

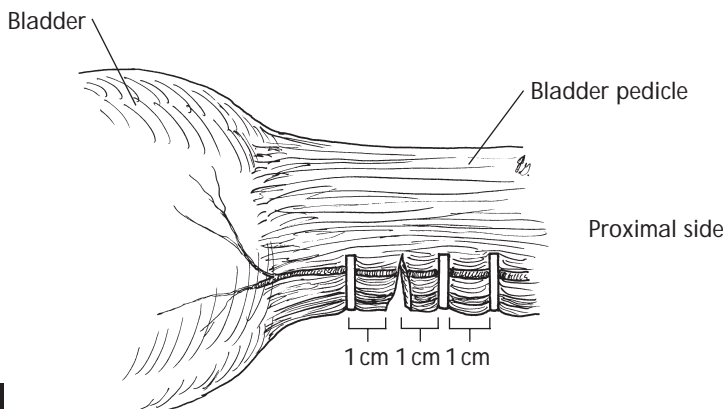
Division of Lateral Bladder Pedicle



Middle finger above and index finger below lateral bladder pedicle

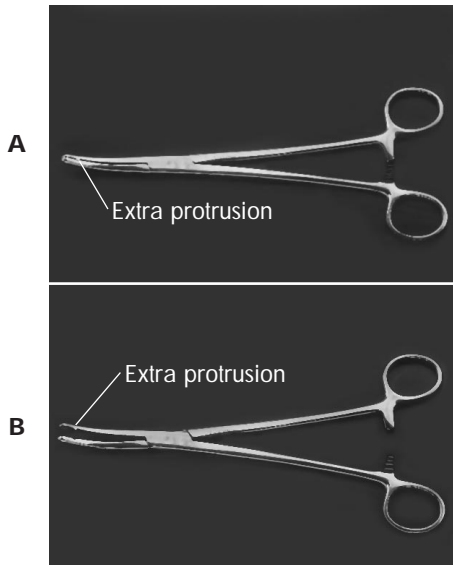
9-14

1 cm Rule with Two Clips on Proximal Side

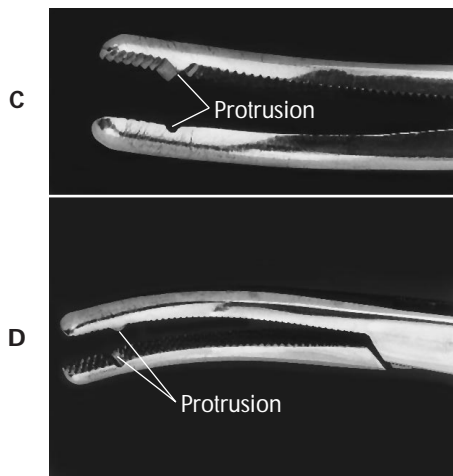


9-15

Haney or Ballantine Clamp

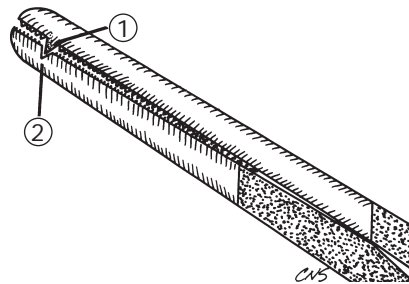


Tip of Haney or Ballantine Clamp

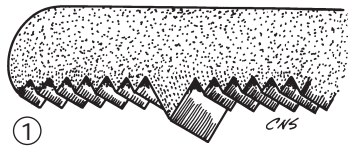


9-16

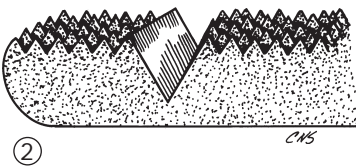
Jaws of Haney Clamp



Top jaw



Bottom jaw



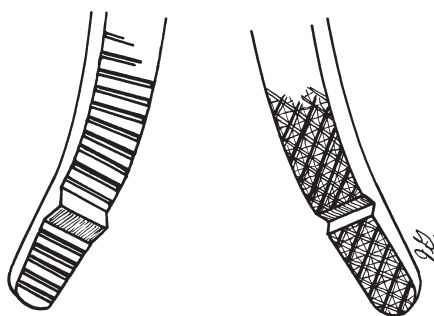
9-17

FIGS. 9-16, 9-17, AND 9-18. If the anatomic pelvis is narrow and the tumor is large with minimal space for maneuverability, the surgeon can use Haney or Ballantine clamps for pedicle division. These clamps can incorporate thick pedicles and have a tooth in the middle to prevent slippage. A pulley stitch (0 silk) can be used to ligate the divided pedicles.

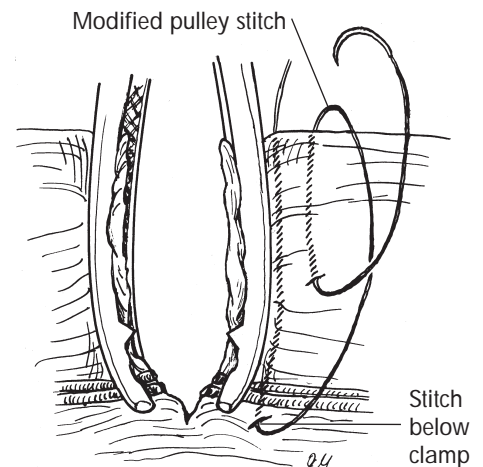
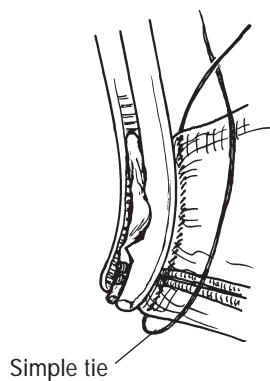
Using the same technique, the surgeon divides the posterior pedicles after lateral pedicle division is completed.

FIGS. 9-19, 9-20, AND 9-21. The posterior bladder pedicles should be divided as close as possible to the bladder side to preserve the neurovascular bundles. Note the position of the neurovascular bundles in relation to the seminal vesicles.

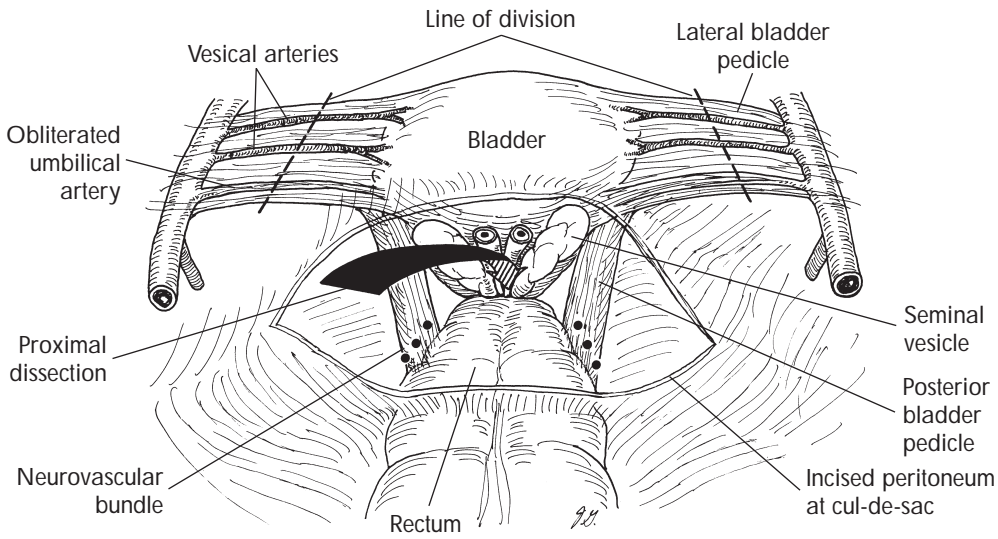
Use of Haney or Ballantine Clamp for Pedicle Division



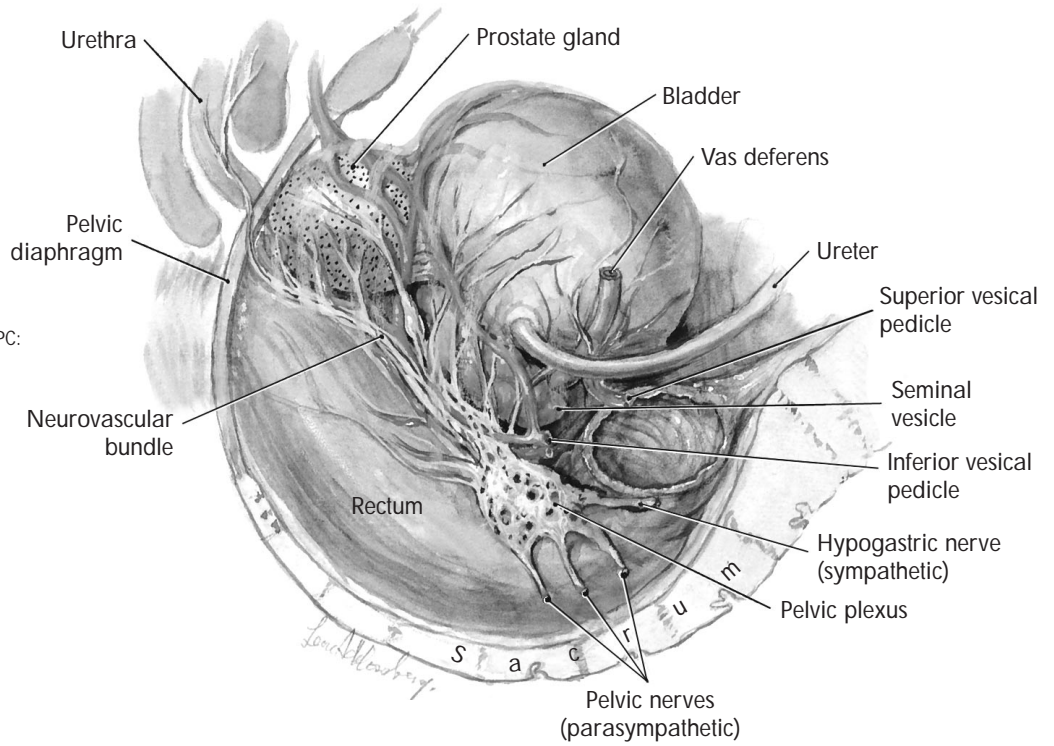
9-18



Top View



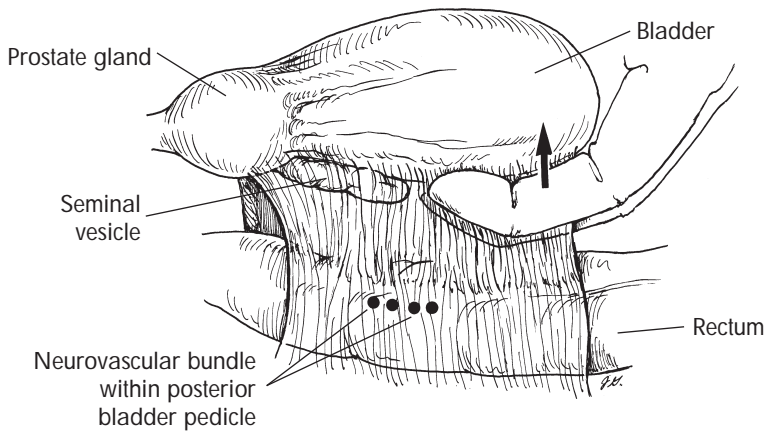
9-19



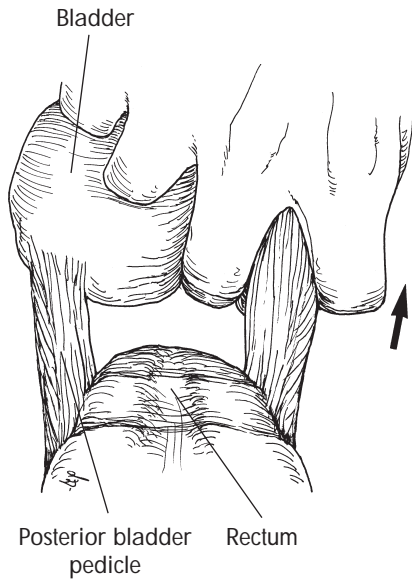
From Schlegel P, Walsh PC: *J Urol* 138:1402, 1987.

9-20

Lateral View



9-21



9-22

FIG. 9-22. It is easiest first to ligate and divide the right posterior pedicle completely and then to approach the left side by simply lifting up the free prostate gland and bladder.

STAPLER DIVISION OF BLADDER PEDICLES

The clear advantage of stapler division is the time-saving and blood-saving factor.³

Once the prostatic pedicles have been divided from the distal dissection, the surgeon should have enough maneuverability to insert the Endo GIA 60 stapler (U.S. Surgical, Norwalk, Conn.) with the 4.8 mm staple cartridge (green) or the GIA 60 stapler. We prefer the six rows of staples of the Endo GIA 60 to the four rows of the GIA 60.

FIG. 9-23. Finger-pinching the bundled lateral and posterior pedicles as previously described will thin out the fatty components of the pedicles and facilitate placement and engagement of the stapler.

FIGS. 9-24 AND 9-25. The Endo GIA 60 or GIA 60 is placed and en-

gaged with the surgeon's fingers beneath it to prevent injury to the rectum. The stapler lip should extend 2 cm beyond the pedicle when engaged.

The surgeon should now check again for optimal placement of the stapler. It should be lateral to the bladder but medial enough to protect the rectal vasculature and neurovascular bundles. If the position is unsatisfactory, the surgeon should disengage and reposition the jaws.

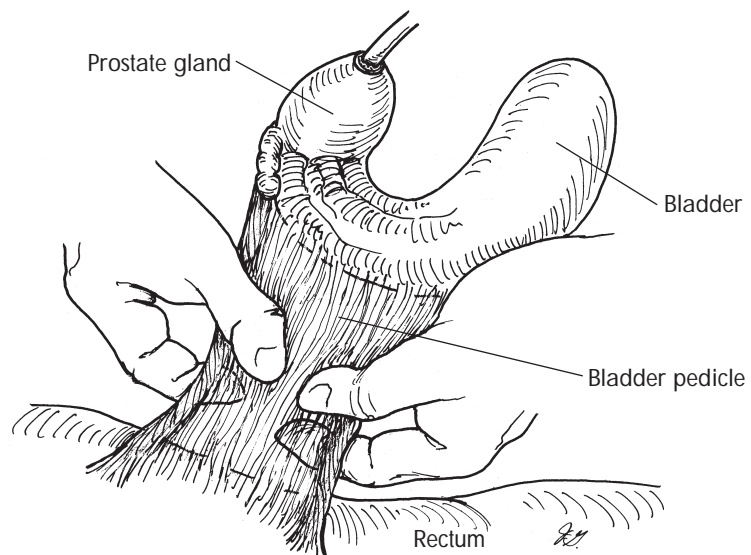
The gas-powered Endo GIA 60 with 4.8 mm staples (green cartridge) will discharge four times with a fresh cartridge. It is important to engage the *red* button to prevent loss of the gas power.

The GIA 60 can be used as many times as needed with fresh cartridges.

FIGS. 9-26 AND 9-27. In general, two discharges are necessary to divide the bundled lateral and posterior pedicles together. Small residual tissues can be cut and ligated.

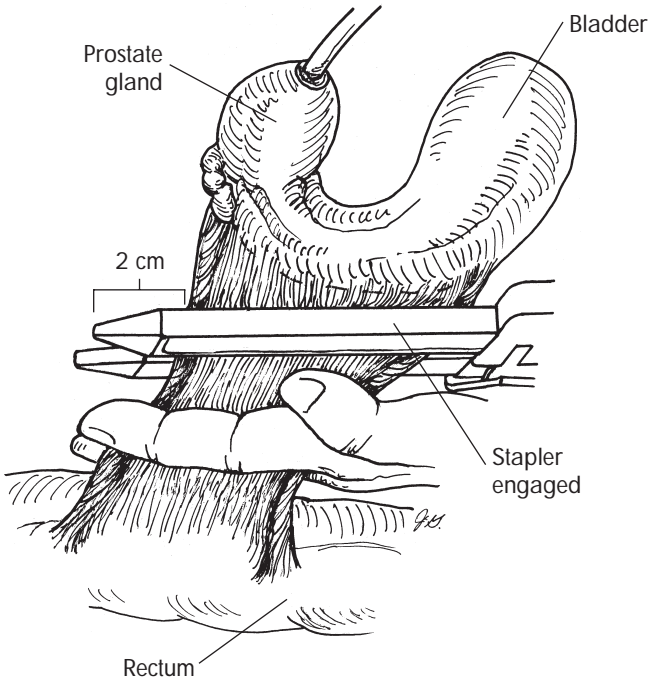
The surgeon should always check the stapled lines for persistent bleeding and oversee anything oozing.

Finger-Pinching of Bladder Pedicle



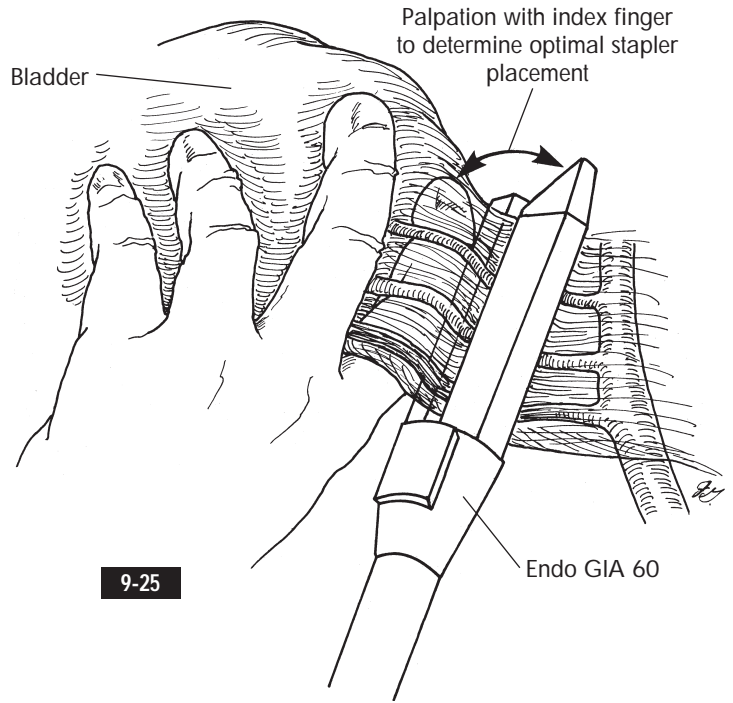
9-23

Stapling with GIA 60 for Bladder Pedicle Division



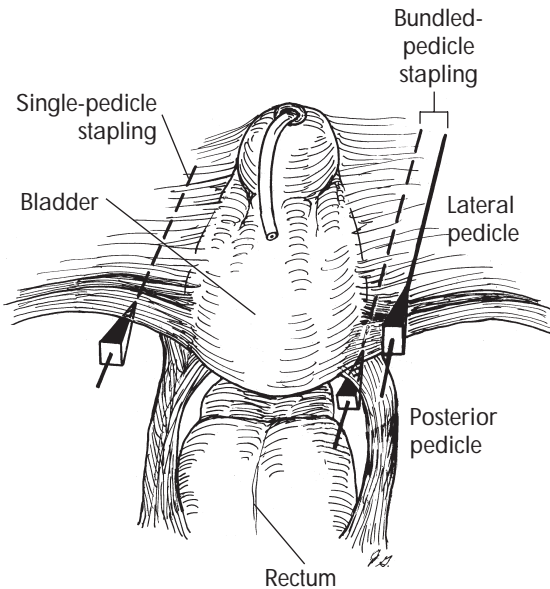
9-24

Stapling Lateral Bladder Pedicle with Endo GIA 60



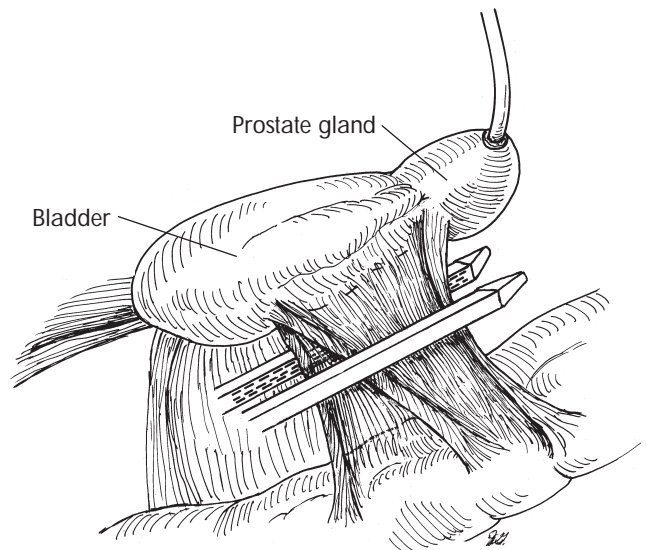
9-25

Pedicle Division



9-26

Bundled-Pedicle Stapling



9-27

KEY POINTS

- Bowel mobilization and packing are performed.
- The ureters are isolated with vessel loops.
- A Bookwalter, Balfour Greishe, Finochetto, or Omni retractor is placed with a folded malleable ribbon into the operative field.
- After lymphadenectomy, the hypogastric artery may be ligated distal to the superior gluteal artery if there is no concern with potency.
- The ureters are clipped and divided, and the distal margins are sent for biopsy.
- A dissection plane and space are developed between the bladder/prostate gland and the rectum.
- The neurovascular bundles are located in the posterior bladder pedicles at the level of the tips of the seminal vesicles. If the Foley catheter is pulled taut distally, the surgeon can palpate the Foley balloon through the bladder. This is approximately the same level as the location of the proximal seminal vesicles.
- Distal dissection of the prostate gland is performed as in a radical retropubic prostatectomy.
- The prostatic pedicles are divided.
- The proximal and distal dissections are joined, leaving two pedicles on each side of the bladder. The web of tissue separating the two dissections should be di-

vided or punctured on the prostate gland/bladder side rather than on the rectal side.

- The lateral and posterior pedicles are divided separately or in a bundled fashion.
- Division is performed by Endo GIA 60 stapler application with a 4.8 mm staple cartridge (green) or by the use of clips or Haney or Ballantine clamps.

POTENTIAL PROBLEMS

- *Rupture of hypogastric veins during lymphadenectomy:* Obtain distal/proximal vascular control and perform suture ligation → if necessary, ligate the entire vessel
- *Difficulty in establishing posterior dissection plane between rectum and bladder:* Start the anterior dissection first
- *Pelvis is too small and pedicle ligation and division are difficult:* Use Haney clamps with modified pulley stitches
- *Pelvis is too small to extract large bladder tumor:* Consider partial pubectomy
- *Bleeding from dorsal venous complex:* Perform stitch ligation → use urethral Foley balloon (inflated to 40 ml) as tamponade
- *Difficulty with ligation and division of posterior pedicles:* Ligate and divide the right side first
- *Rectal injury:* Close the rectal tear in two layers → perform loop colostomy (see Chapter 27)

REFERENCES

- 1 Schlegel PN, Walsh PC: Neuroanatomical approach to radical cystoprostatectomy with preservation of sexual function, *J Urol* 138:1402, 1987.
- 2 Burgers JK, Brendler CB: Anatomic radical cystoprostatectomy, *Urol Clin North Am* 18(4):659, 1991.
- 3 Chung S et al: Bladder pedicle stapling in radical cystectomy, *Contemp Urol* January 1996.

SUGGESTED READINGS

- Skinner DG: Radical cystectomy. In Crawford ED, Borden TA, editors: *Genitourinary cancer surgery*, Philadelphia, 1982, Lea & Febiger, pp 207-217.
- Skinner DG, Lieskovsky G: Technique of radical cystectomy. In Skinner DG, Lieskovsky G, editors: *Diagnosis and therapy of genitourinary tumors*, Philadelphia, 1988, WB Saunders, pp 607-621.