Critical Operative Maneuvers in Urologic Surgery

George W. Yu
Harry C. Miller

INDEX

Critical Operative Maneuvers in Urologic Surgery

RICHARD E. WILSON
1929-1989
Peter Bent Brigham Hospital
Harvard Medical School

Gifted with superb operative skills combined with solid
clinical judgment, he remained unassuming, modest, and
ever preoccupied with the many tasks at hand.
We will always remember him for his generosity
in sharing his knowledge, his expertise,
and his passion with everyone who was
as motivated and committed
to surgery as he.

Critical Operative Maneuvers in Urologic Surgery

George W. Yu, MD
Clinical Professor of Urology
George Washington University Medical Center
Washington, D.C.

Harry C. Miller, MD
Professor and Chief of Urology
George Washington University Medical Center
Washington, D.C.

with 742 illustrations

Mosby

St. Louis Baltimore Boston Carlsbad Chicago Naples New York Philadelphia Portland
London Madrid Mexico City Singapore Sydney Tokyo Toronto Wiesbaden

Mosby
Dedicated to Publishing Excellence

A Times Mirror Company

Publisher and Vice President: Anne S. Patterson
Editor: Susie Baxter
Developmental Editor: Anne Gunter
Project Manager: Linda McKinley
Editing and Production: Top Graphics
Design Manager: Liz Young
Designer: Teresa Breckwoldt
Manufacturing Supervisor: Karen Lewis

Printed in the United States of America
Composition by Top Graphics
Printing / binding by Maple-Vail

Mosby–Year Book, Inc.
11830 Westline Industrial Drive
St. Louis, Missouri 63146

Library of Congress Cataloging in Publication Data
Yu, George W.
Critical operative maneuvers in urologic surgery / George W. Yu, Harry C. Miller.
p. cm.
Includes bibliographical references and index.
ISBN 0-8016-7681-9
1. Genitourinary organs—Surgery—Atlases. 2. Surgery, Operative—Atlases. I. Miller, Harry C. II. Title.
[DNLM: 1. Urologic Diseases—surgery—atlases. 2. Prostatic Diseases—surgery—atlases. 3. Surgery, Operative—methods—atlases. WJ 17 Y94c 1996]
RD571.Y8 1996
617.4'6—dc20
DNLM / DLC
for Library of Congress 95-25267
CIP

96 97 98 99 00 / 9 8 7 6 5 4 3 2 1

TO

our patients

who have trusted us through the years

our teachers

who were generous to share their experiences

our colleagues

who continue to teach and share with us

our residents

who bring fresh ideas that challenge old concepts

our loved ones

who have sustained us

PREFACE

In most procedures there are a few *distinct steps and maneuvers* critical to the success of the operation. Because it is necessary for authors of survey texts and general atlases to cover a broad and sequential base of information, they are often unable to devote sufficient space and attention to the elaboration of these critical maneuvers. Yet it is these practical points that become the "pearls" of operative surgery, timeless and worthy of being passed on to each generation of surgeons. Where there is insufficient coverage given to these specific important maneuvers in other texts, we have elaborated upon them using greater detail and numerous illustrations. Consequently, this book should be used as a companion to other texts.

We have selected a collection of these "pearls" and although the descriptions are sequential, we have omitted many steps of each operation with the assumption that surgeons will bring to the reading of this text a basic understanding of the operations as well as some operating room experience with the specific procedures discussed.

Thirty-one operations plus one chapter on rectal injury are presented. Our goal is to address the urologic surgeon who seeks the versatility to perform a wide variety of procedures, from excisional surgery to complex reconstructive surgery.

From our combined surgical experience of 50 years as well as our close association with each other in the operating suites of one institution, we have selected these procedures because they are the simplest and the most successful with the fewest complications and the lowest reoperation rate.

In the changing arena of health care, health issues and economic issues are inextricably wedded to each other. Facing an increasing work load but a decreasing operating load, the surgeon is still expected to perform surgery effectively, quickly, and cheaply while remaining accountable for long-term results. He or she is measured not just by traditional standards but by preoperative, intraoperative, and postoperative economic considerations. This is known as *economic credentialing.* The referral of complex cases to tertiary medical centers becomes more difficult as increasing economic pressures are brought to bear. The surgeon is expected to handle common surgical problems as well as the more complex varieties of surgery in order to maintain a *competitive edge.*

What we present in this book is what good surgeons do instinctively: long before an actual operation, he or she will explore a *mental and visual checklist* of the surgical procedure that lies ahead and will consider the potential for unique problems and their solutions.

This practical operative guide is totally "user friendly" for the busy, active urologic surgeon. The format and design of the book allow the reader to see illustrations and corresponding prose without the need to flip pages. The book lists key points and potential problems at the end of the chapters.

SPECIAL FEATURES

Thoracoabdominal Radical Nephrectomy and Retroperitoneal Lymph Node Dissection (Chapters 1 and 5)

These two chapters are more comprehensive with regard to anatomy and approaches to the high retroperitoneum than we have seen in any urologic text. The spatial relationship of the superior mesenteric artery, the pancreas, the duodenum, and the renal vasculature is clearly presented in two-dimensional artwork and photographs of three-dimensional models. The variation of the adrenal veins and the variations of the inferior mesenteric vein draining into the portal system are clearly presented. Both abdominal and thoracoabdominal approaches are explored for right and left tumors. Tumor vascular extensions into the infrahepatic vena cava are discussed, and the surgeon is given a clear strategy for dealing with liver and splenic injuries during operative procedures.

Radical Cystectomy in the Male and Female Patient (Chapters 9 and 10)

In the male patient, we describe a nerve-sparing (potency preservation) approach using the traditional proximal dissection through the vesicorectal junction as well as the distal dissection as done in the radical retropubic prostatectomy. The lateral and posterior pedicles are "bundled" together and stapled with the Endo GIA 60 (4.8 staples). These modifications have made a difficult operation simple and quick, with minimal blood loss. The average time required for the cystectomy part of the operation in our institution is 50 minutes, thus leaving more time for the reconstruction procedure.

In the female patient, we use a traditional proximal dissection through the pouch of Douglas but a distal vaginal dissection as a modification of the Raz operation. We often start with the patient in the lithotomy position for the distal vaginal dissection and then reposition to a flexed supine configuration for the formal cystectomy. Special considerations are included for posthysterectomy patients with distorted anatomy near the rectum; for sexually active women with limited disease, a vaginal dissection allows maximal preservation of the natural anatomy.

Urinary Continent Diversions—The Indiana Pouch and the Ileoneobladder (Hautmann Type) (Chapters 12 and 13)

We based our selection of the two continent diversions on several factors: time-tested proof of good long-term results, patients' ability to adapt quickly to the diversion and to use it with ease, simple operative procedure without use of nonorganic materials, few complications, and low reoperation rate.

The Indiana pouch with the detubularized colon has a good urinary storage capacity and the continence mechanism is excellent. We use a quick straight-needle sewing technique as well as speedy stapling with the absorbable GIA 75 to construct the pouch. The stapled ileal stoma tapered to a Fr 14 circumference has been the most successful formula for easy catheterization.

The ileoneobladder, procedure of choice at Memorial Sloan Kettering Hospital, was selected for its low rate of complications and reoperations. We agree with their philosophy. We have given special considerations to the more difficult left ureterointestinal anastomosis and the maneuvers to facilitate the approximation of the ileoneobladder to the urethral stump.

Comparisons of Stress Incontinence Operations and the Raz and Modified Burch Procedures (Chapters 14, 15, and 16)

We present a comparative chart and illustrations of the various operations for stress incontinence. We discuss the principle of correction of the hypermobility, the correction stitches placed at the bladder neck region, and a noncompression of the urethra by placement of lateral stitches as exemplified by the Raz procedure.

The modified Burch procedure, described by Tanagho, removes some of the misconceptions about this operative procedure. This operation is simple, it corrects small cystoceles simultaneously, and it rarely leads to surgical overcorrection with subsequent bladder instability and temporary urinary retention.

The same pelvic fascial dissection described in the Raz operation is adapted for the sling procedure utilizing a strip of rectus fascia or of inorganic material. A combination of the vaginal dissection (Raz) and the retropubic dissection (Burch) procedures is used for artificial sphincter placement. These two operations are used to correct Type III stress incontinence.

Radical Retropubic Prostatectomy and Radical Perineal Prostatectomy (Chapters 18 and 19)

At one time or another, all surgeons have encountered massive bleeding during the division of the dorsal venous complex in a radical retropubic prostatectomy. We present some consistently safe and reliable variations on the ligation and division of the venous complex. The dissection preserving the bladder neck, which is incorporated in our approach to this operation, has resulted in earlier patient continence recovery and fewer strictures.

The chapter on the radical perineal prostatectomy is one of the clearest descriptions we have seen. This operation, with a nerve-sparing modification, avoids the entire dorsal venous complex, which results in minimal blood loss and rapid patient recovery. The most difficult part of the operation is the takedown of the rectourethralis muscle. We have described a safe technique and have used photographs of three-dimensional models as well as traditional drawings.

Urethroplasty and the Use of Deepithelialization Technique (Chapters 22 and 23)

For both anterior and posterior urethroplasty, the principles of surgery described by Richard Turner-Warwick are timeless. This chapter has numerous illustrations and photographs of three-dimensional models to show these principles so that they are easily understood and are useful for the reconstructive surgeon. We have included the deepithelialization technique described by Durham Smith for surgery of hypospadias and have incorporated it into urethroplasties for stricture disease.

Rectal Injury in Urologic Surgery (Chapter 27)

Considering the fact that so much of the urologic surgeon's work is in the pelvis and perineum with

such intimate proximity to the rectum, we have included a discussion of the potential areas of injury, the maneuvers to avoid it, and the surgical maneuvers after a rectal injury.

• • •

This text contains 742 illustrations. They are based on the concept of *"SUBTRACTION"* which was described by Paul Ver Vais, eminent illustrator for *Urological Surgery* by Reuben Flocks (1957, with five subsequent reprintings). Ver Vais said that unlike aesthetic art, communicative art must *"SUBTRACT"* unnecessary elements in order to focus on the important points. The artwork is a cross between realistic and schematic. Proportions are changed to emphasize small areas. "Ghosting" or drawings showing layers are used to show different planes and tissues beneath the surface. Directional arrows are used to show the movement of the surgeon's hand during a maneuver.

For convenience, we have included a few outstanding illustrations from other texts.

In addition to traditional drawings, we have used halftone photographs of sculpted three-dimensional models to enhance comprehension. At present, we are also digitizing these three-dimensional models as a CD. The models provide a 180- to 360-degree view of the specific anatomy discussed in conjunction with selected traditional illustrations to enhance total visual comprehension. These innovations are unique, and credit should be given to Mosby Year–Book and especially to medical editor Susie Baxter and former medical editor David Marshall for their vision, their foresight, and their support.

We are grateful to American Medical Systems, Inc. (Pfizer); Bayer, Pharmaceutical Division; Merck, Human Division; Schering, Division of Oncology; T.A.P. Pharmaceuticals, Inc.; and U.S. Surgical, Inc., for their generous educational grants that supported in part the costs that are inherent in the production and publication of such a project as this.

We thank our working team, who demonstrated unbelievable "staying power" for making this publication a reality: Judy Guenther, the main illustrator; Deborah Banker, the sculptor; Kimberly Ernst, the photographer; Paul McGuire and Julian Gooding, the computer and video geniuses; Peggy Yoest and Terra S. Walters, the editors and administrators; and the reviewers, Dr. Simon Chung, Dr. John Danneberger, Dr. Frank Melograna, and Dr. Marguerite Lippert, for their dedication.

We hope this book will be helpful in your daily surgical practice.

George W. Yu, MD

Harry C. Miller, MD

It has been said that a picture may be worth a thousand words, but it is but a few words which bring focus to a picture.

Contents

Dr. Harry Miller
Former Chairman - Dept of Urology
George Washington University Medical Center

Dr. Thomas W. Jarrett
Chairman - Dept of Urology
George Washington University Medical Center

Dr. George W. Yu
Clinical Professor - Dept of Urology
George Washington University Medical Center
George W. Yu Foundation for Nutrition & Health

Formerly Mosby and now Harcourt Publishing have given us, George Yu and Harry Miller, all rights to the operative text **Critical Operative Maneuvers in Urologic Surgery with first edition in 1996.**

George Yu, Harry Miller, Tom Jarrett

By popular demand from so many surgeons who have requested for reprints, we can now give you the entire text for your use whether urologists, general surgeons, plastic surgeon or gynecologists etc.

Many surgeons worldwide expressed that it was the illustrations, which made our book so valuable and now we have the master copies to reproduce them **for your use at no cost to the public.**

What is unique and what can never be done again is that this operative textbook contains 742 illustrations packed into a 275-page publication. The cost of production of so many illustrations would have been cost prohibitive were it not for the author surgeon who drew the first illustration himself- and that is what surgeons want!

Since the book publication, many experienced surgeons have communicated their "pearls" of surgery and Harry and I only wish we could have included it in another edition of the book - which will never happen again.

The surgical craft is not "intellectual or academic" but truly "experiencial". Generations of surgeon pass on their skills and "know how's" to the next generation of younger surgeons much of which cannot be replicated from texts alone.

In my own training, my greatest gratitude goes to Richard Wilson of Harvard Peter Bent Brigham, Robert Jeffs and Patrick Walsh of Johns Hopkins Medical Center, Harry Miller of George Washington University Medical Center, Richard Turner Warwick of England and Ion Kiricuta of Romania and S. Irvin, missionary surgeon from Scotland.

In my recent visit with Richard Turner Warwick, we both believe that earlier continence could be achieved by preserving the proximal bladder internal sphincter in the radical prostatectomy whether done by open or robotic surgery. This is discussed in chapter 18, pages 184 and 185.

Whether performing laparoscopy, robotics, or open surgery, surgical positioning, exposures and anatomical landmarks are timeless and discussed in the text.

Important Chapters to review:

- Chapter 1, Thoraco-Abdominal Radical Nephrectomy
- Use of Omental flaps for revascularization
- Psoas – Hitch and Boari flaps to reapproximate kidney to bladder
- Use of GIA staplers to ligate and divided vascular pedicles of the bladder and uterus in radical cystectomy
- Reconstruction of Vaginal vault after exenteration surgery
- Preservation of internal proximal sphincter as well as external distal membraneous sphincter for improved continence after radical prostatectomy
- Urethroplasty pioneered by Richard Turner Warwick

The growing use of more minimally invasive procedures such as laparoscopy and robotic -assisted surgery means that, as surgeons, we have fewer opportunities to perform open surgery and consequently less skill with time. However, every surgeon, who is fully trained, must maintain operative skills to perform open surgery when no other method is possible without endangering the patient.

Dr. Tom Jarrett, Chairman of Urology, George Washington University Medical Center and myself, George Yu, felt it would be useful if we could combine Chapter 1, Thoraco-abdominal Right Radical Nephrectomy with an actual video of the entire operation to enrich the didactic information from the textbook.

To our colleagues and future surgeons,

George Yu, Harry Miller, Tom Jarrett

THORACOABDOMINAL RADICAL NEPHRECTOMY: SPLENIC AND LIVER INJURY

1

LATERAL POSITION AND FLANK INCISION

FIG. 1-1. The lateral positioning of the flank incision provides the easiest access to the kidney in the retroperitoneum. However, if a large left hilar or upper pole renal mass exists, the surgeon may find that the orientation of the midline vasculature is obscured when the patient is in the lateral position.

Although the superior mesenteric artery lies superior to the renal vein and the renal artery lies posterior and inferior to the renal vein, there have been reports of experienced surgeons ligating and dividing the superior mesenteric artery, mistaking it for the left renal artery, during a left radical nephrectomy.[1,2]

In addition to the confusion of vascular orientation in large renal tumors, dissection of the renal hilum for good vascular control is difficult.

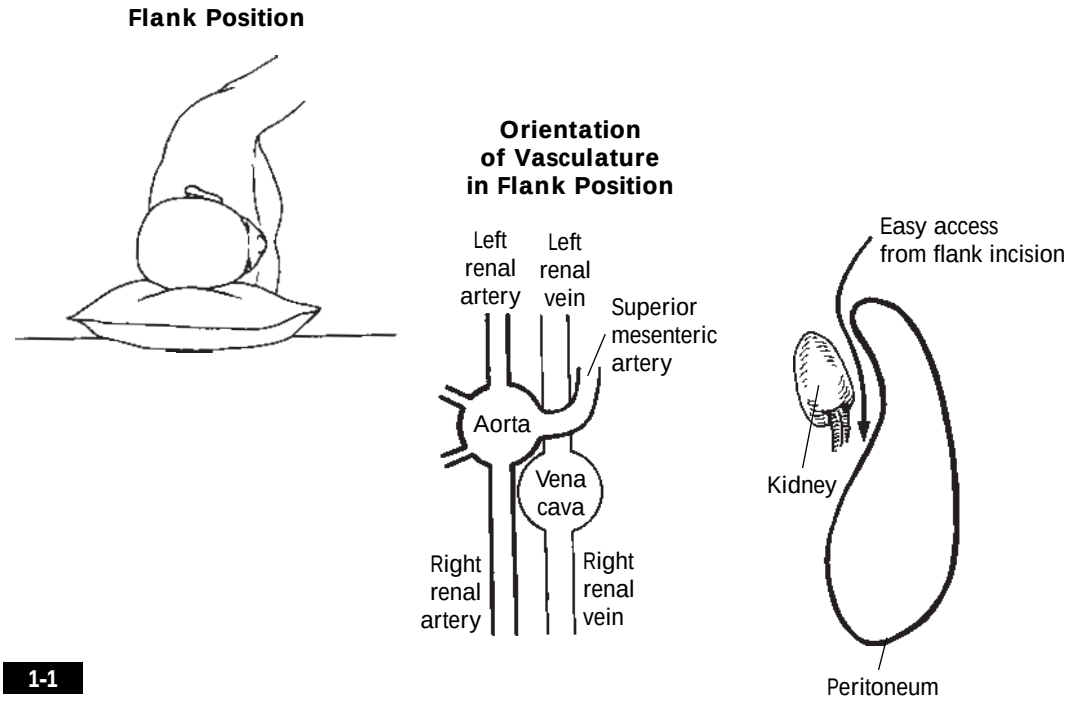

1-1

Supine Position

Orientation of Vasculature in Supine Position

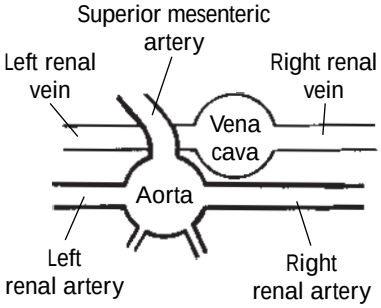

1-2

SUPINE POSITION AND MIDLINE INCISION

FIG. 1-2. The supine position with a midline incision provides good exposure and orientation of the midline great vessels and major branches. However, if the incision is not carried up to the xiphoid process or higher, resection of large medial or superior pole renal masses may be difficult.

With the patient in a supine position, the superior pole of the kidney is angled posteriorly, and therefore resection of a large superior renal mass is difficult.

FIG. 1-3. The best compromise is to have the chest and upper abdomen positioned at a 45-degree angle from the operating table and the lower abdomen placed as flat as possible in a supine position—a torque configuration. A long sandbag behind the back maintains this position. The best positioning is achieved when the break of the table is in line with the anterior superior iliac spine.

The 45-degree–angled position provides easy access to the upper pole of the kidney and retroperitoneum, yet the near-supine position of the lower abdomen affords good orientation and allows optimal control of the midline vasculature.

Specifically, for large left-sided tumors, a more exaggerated medial reflection of the left colon and transverse colon helps the surgeon to identify the superior mesenteric artery from the renal pedicle. The surgeon frees the posterior parietal peritoneum along the line of Toldt from the sigmoid colon all the way around the splenocolic ligament and part of the transverse colon.

CHEVRON INCISION AND SUBCOSTAL WITH EXTENDED-T INCISION

FIGS. 1-4 AND 1-5. Whether using a thoracoabdominal, chevron, or subcostal with an extended-T incision, the surgeon attains good access to the high retroperitoneum by the following maneuver. The principal objectives of patient positioning involve the following:

1. 45-degree angle of the chest and upper abdomen
2. As much supine position as possible in the lower abdomen
3. Flexion of the table at the anatomic landmark of the anterior superior iliac spine

45-Degree Position

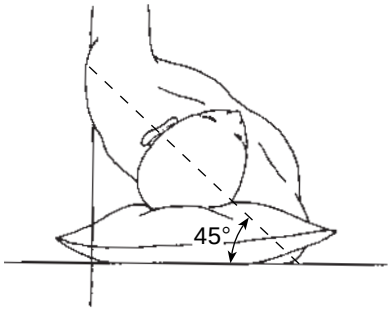

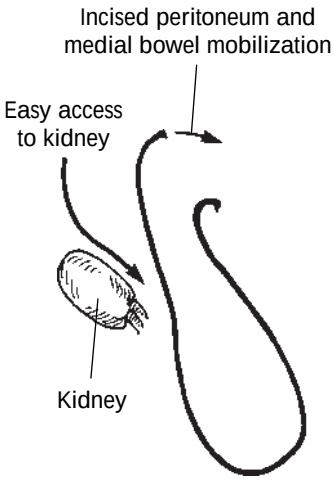

Orientation of Vasculature in 45-Degree Position

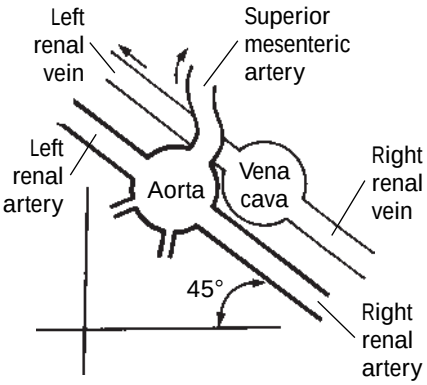

1-3

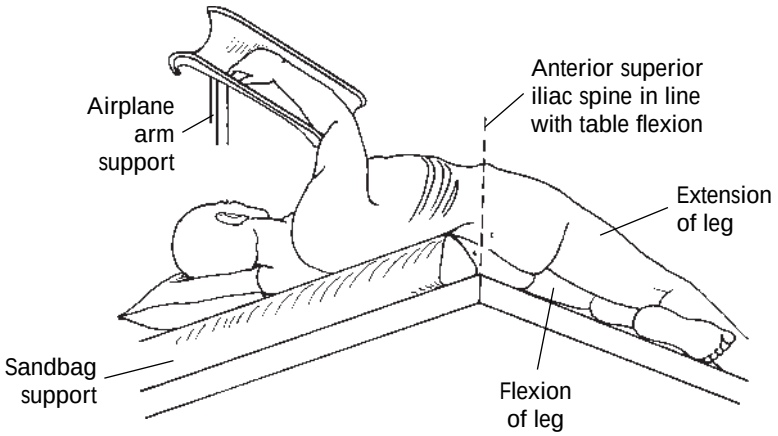
Airplane arm support
Anterior superior iliac spine in line with table flexion
Extension of leg
Sandbag support
Flexion of leg

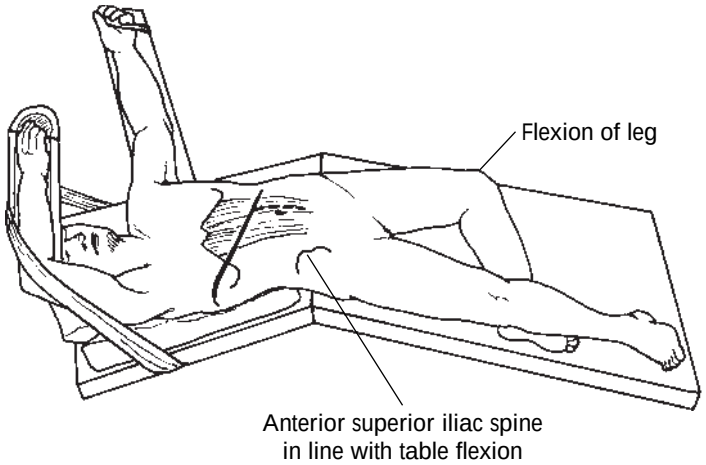
Flexion of leg
Anterior superior iliac spine in line with table flexion

1-4

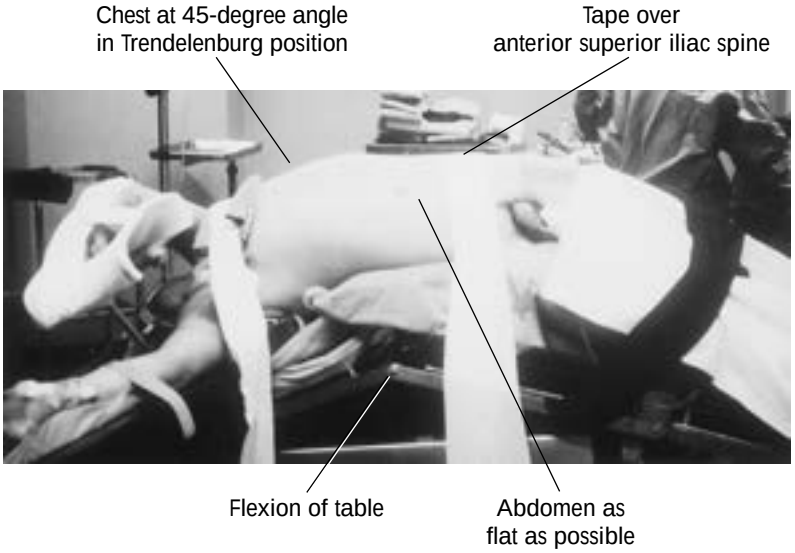
Chest at 45-degree angle in Trendelenburg position
Tape over anterior superior iliac spine
Flexion of table
Abdomen as flat as possible

1-5

Chevron Incision

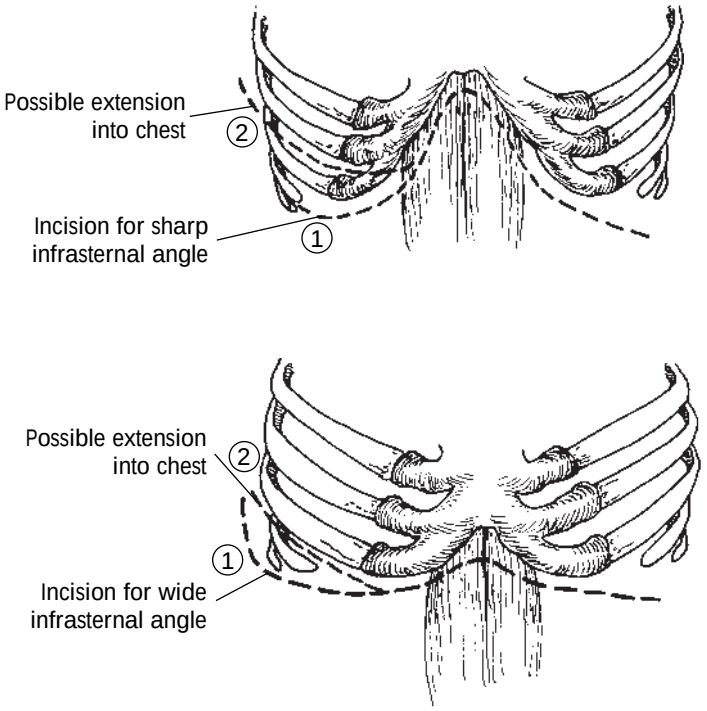

1-6

FIGS. 1-6 AND 1-7. If a chevron or subcostal with an extended-T incision is chosen,[3] the surgeon should ensure that the incision extends laterally past both rectus abdominis muscles and superiorly to the xiphoid process. Especially in patients with sharply angled costal margins, this extension superiorly allows good exposure of the vena cava and of the aorta and its major branches. The surgeon should be prepared to extend these incisions into the pleural cavity if needed *(2)*.

THORACOABDOMINAL INCISION

The thoracoabdominal incision provides the best exposure for high retroperitoneal dissections. This incision is especially suited for right-sided hilar or upper renal tumors associated with a large liver.

FIGS. 1-8 AND 1-9. Beginning at the eighth or ninth rib interspace, the surgeon makes an incision from the posterior axillary line all the way across the cartilage and past both rectus abdominis muscles in a straight diagonal line. This incision not only provides excellent exposure but also contains the bowel mobilized medially. We

Subcostal with Extended-T Incision

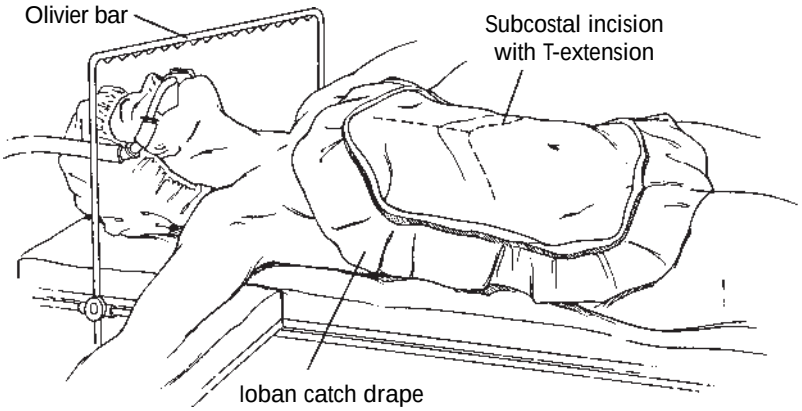

From Marsh CL: *Contemp Urol* 6:15, 1994.

1-7

have not found the combination of a diagonal incision and a vertical extension to be helpful.

FIG. 1-10. After the peritoneum is opened, the pleural cavity is opened through the eighth or ninth intercostal space and the surgeon resects a segment of the costal cartilage arch to connect the peritoneum and pleural cavity.

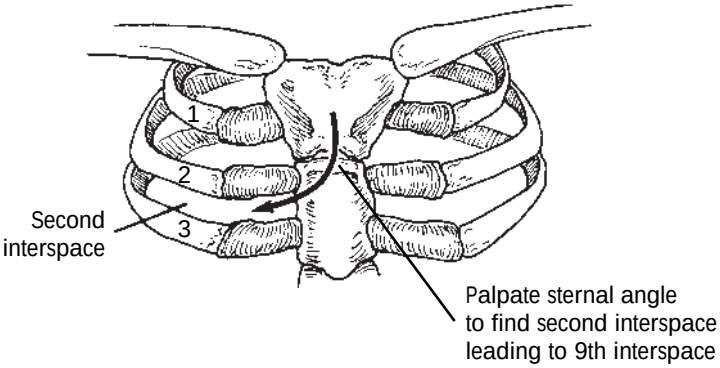

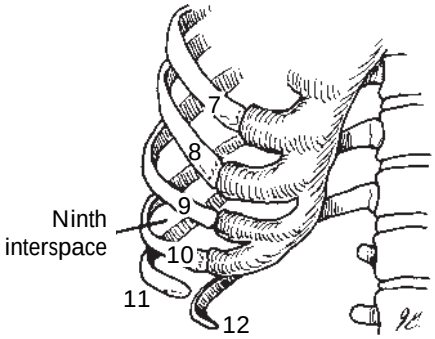

1-8

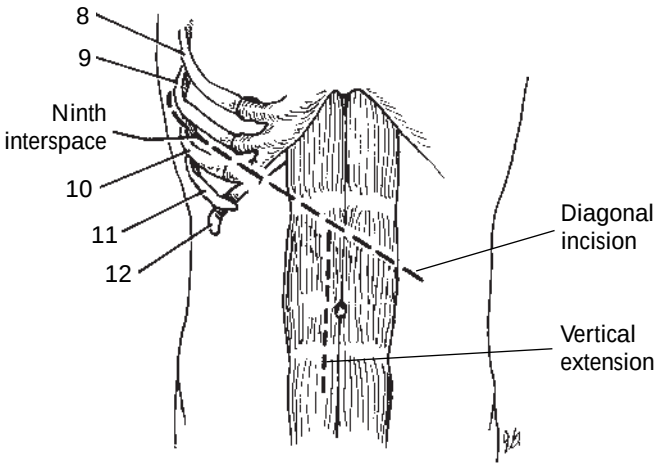

1-9

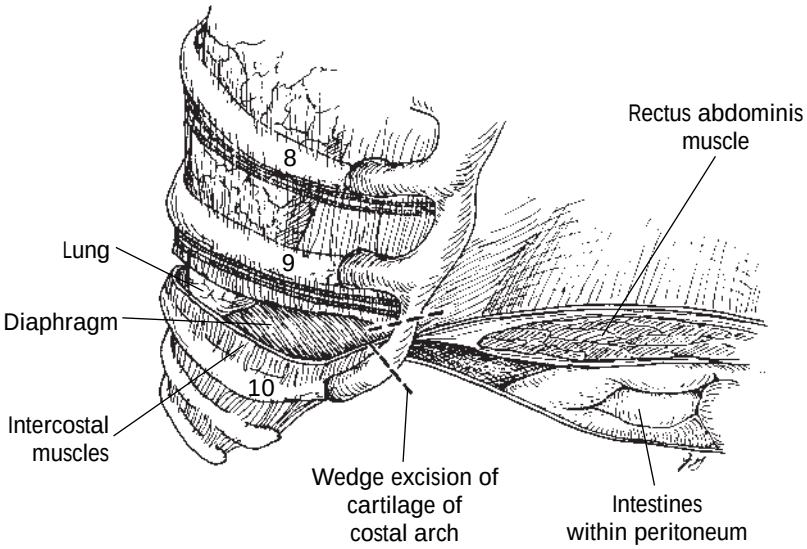

1-10

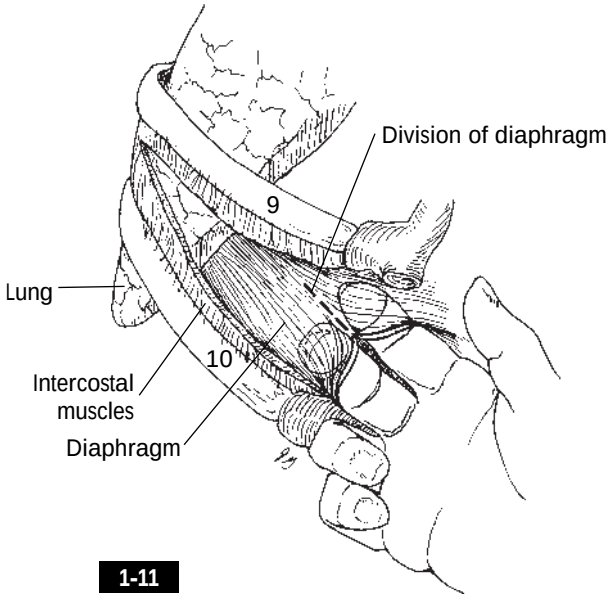

1-11

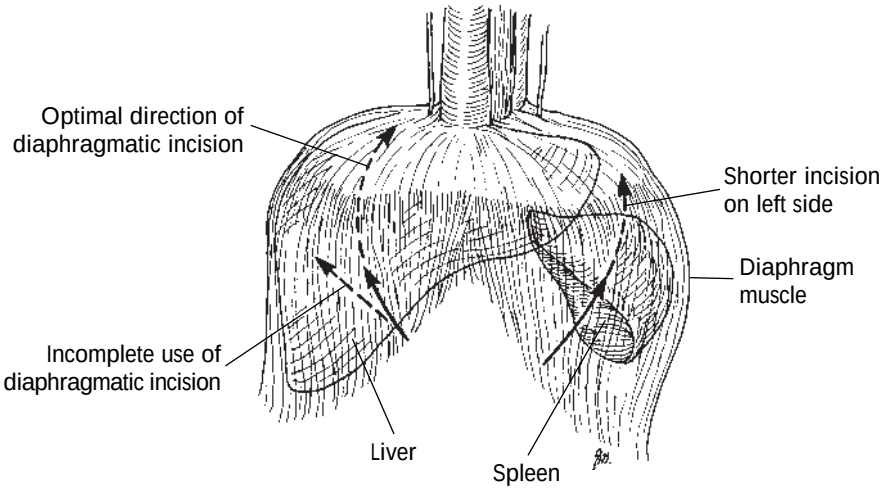

1-12

View From Below Diaphragm Muscle **View From Above Diaphragm Muscle**

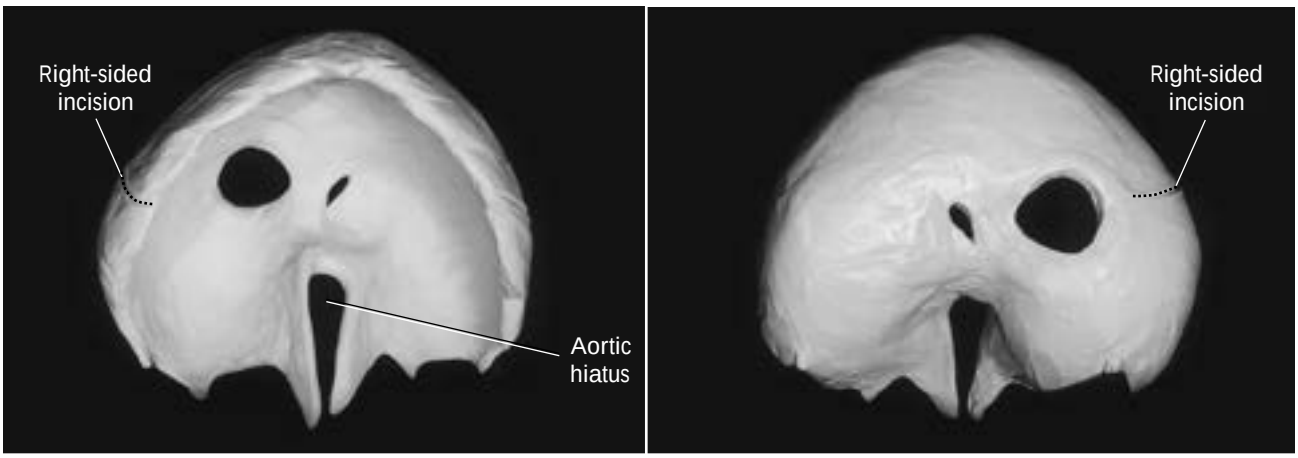

1-13

FIGS. 1-11, 1-12, AND 1-13. The most common error in dividing the diaphragm is to cut too laterally. The surgeon's goal is to split the diaphragm such that the liver and spleen can be mobilized partially or entirely into the pleural cavity when the patient is in the Trendelenburg position.

The diaphragmatic incision should be a semicircle aiming toward the great vessels and the crus of the diaphragm.

FIGS. 1-14 AND 1-15. Using Babcock clamps for traction, the surgeon should divide only one third of the total incision first and then finish the division after the Finochetto retractor is positioned between the ribs to provide a better exposure.

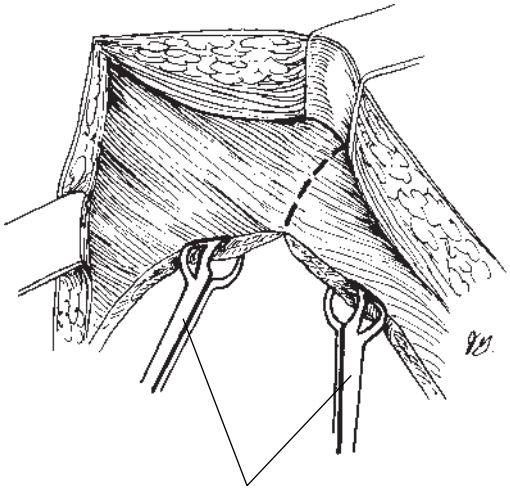

Diaphragm on traction for division

1-14

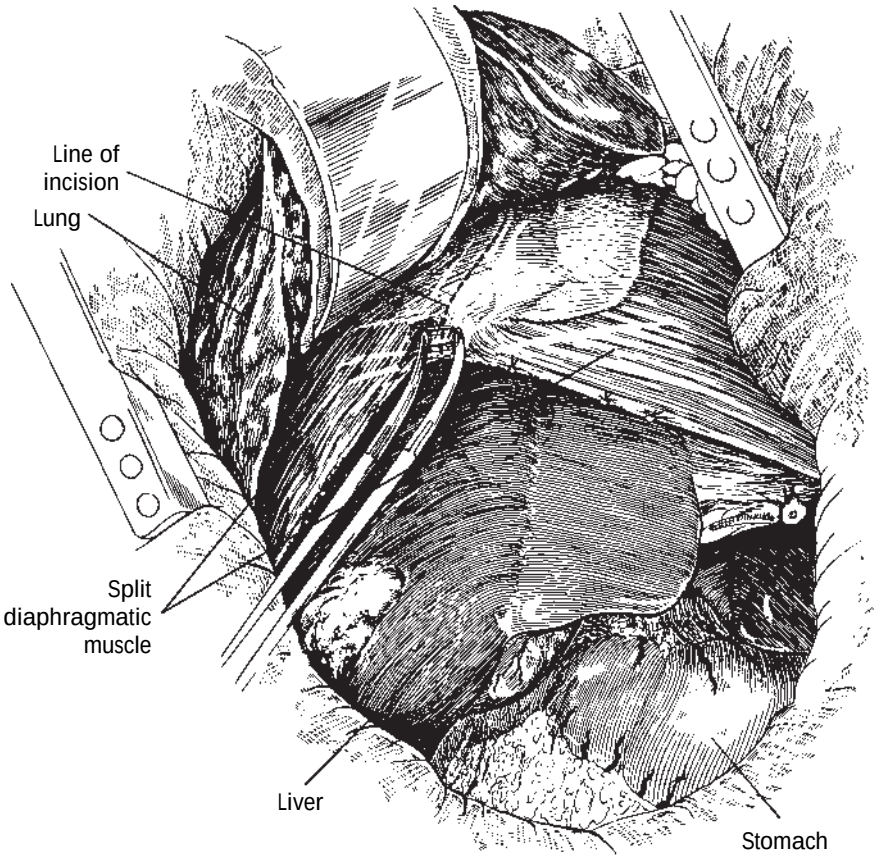

From Zollinger RM Jr, Zollinger RM: *Atlas of surgical operations,* ed 6, New York, 1989, Macmillan.

1-15

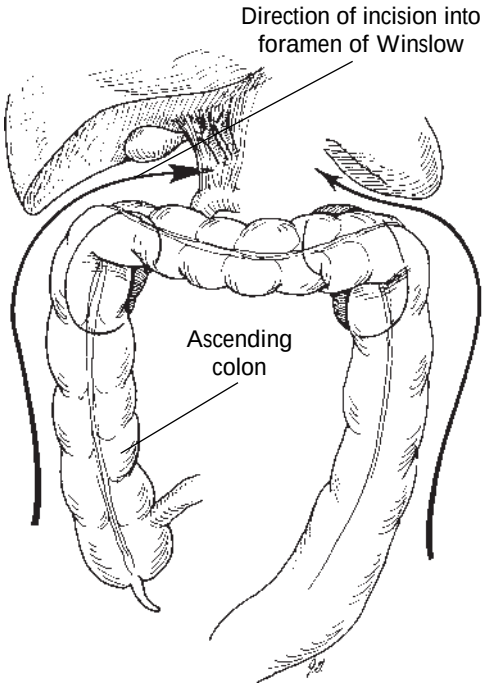

1-16

RIGHT RENAL CANCER

FIG. 1-16. Immediately after completing one third of the diaphragmatic incision, the surgeon divides the parietal peritoneum along the avascular line of Toldt lateral to the ascending colon.

The incision should be carried from around the cecum to the foramen of Winslow. The incision from the hepatic flexure to the foramen should be made only after the Finochetto retractor has been positioned.

If the surgeon places two dry laparotomy pads against the ribs, the Finochetto retractor will not slip when the wound is further opened.

The Finochetto retractor is first partially opened.

The surgeon completes the diaphragmatic incision, aiming toward the great vessels and avoiding major branches of the phrenic nerve within the central tendon.

The incision from the hepatic flexure along the lateral colonic wall should be continued above the transverse colon and behind the porta hepatis at the foramen of Winslow. This parietal peritoneal incision allows maximal bowel mobilization and reflection.[4,5]

FIGS. 1-17 AND 1-18. In cases of accidental liver hemorrhage from lacerations, the Pringle maneuver is useful to reduce bleeding.[6-8] The surgeon places the left index finger into the foramen of Winslow and compresses the tissues anterior to it with the thumb, essentially obstructing the bile duct, portal vein, and hepatic artery (portal triad). This same maneuver can be done with vascular clamps.

FIG. 1-19. Before reflecting the colon medially, the surgeon should first take down the three ligaments of the liver: the falciform ligaments in the midline *(1)*, the right triangular ligament off the back muscles and diaphragm *(2)*, and part of the left triangular ligament *(3)*. In rare situations a part of the right coronary ligament *(4)* also needs to be divided.

Pringle Maneuver: Compression of Porta Hepatis

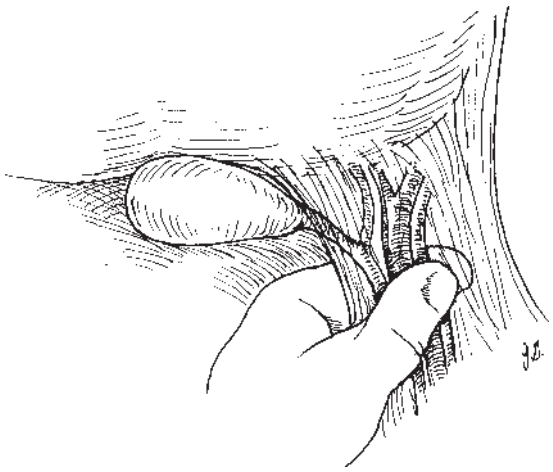

1-17

Cross-Clamping of Porta Hepatis

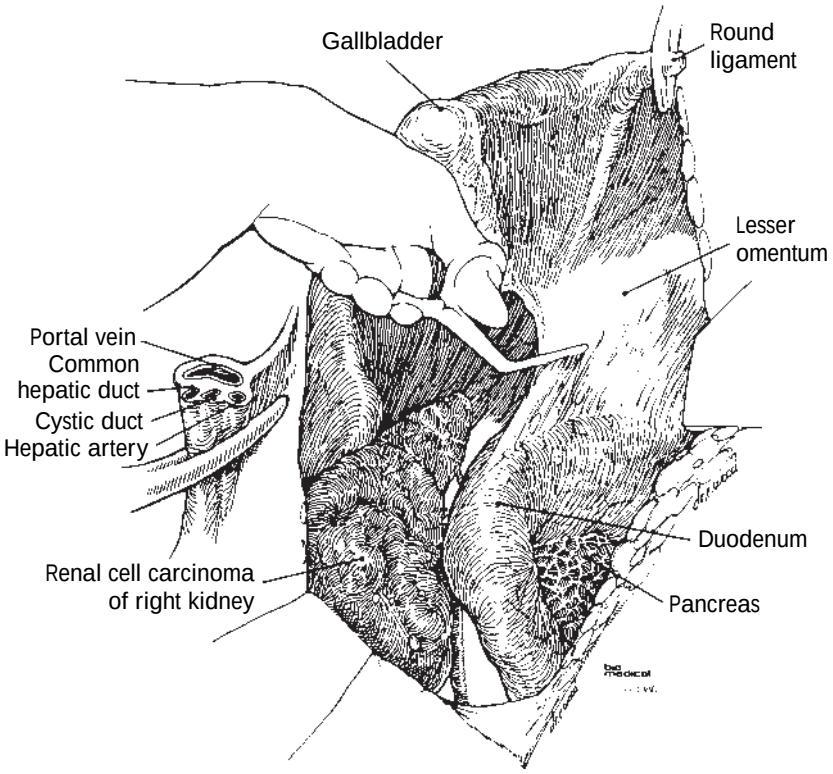

From Crawford ED, Borden TA, editors: *Genitourinary cancer surgery,* Philadelphia, 1982, Lea & Febiger.

1-18

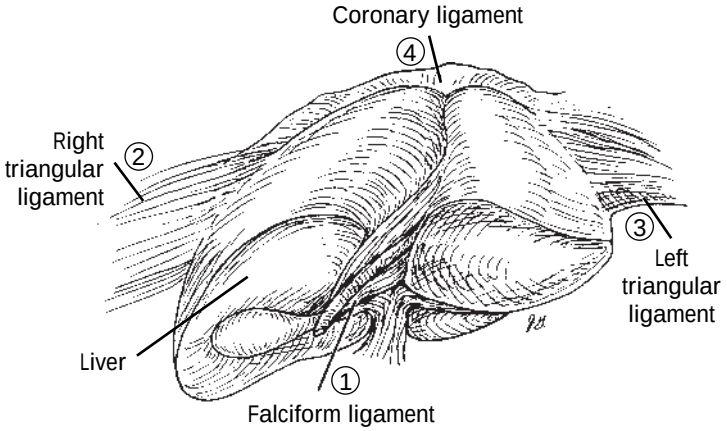

1-19

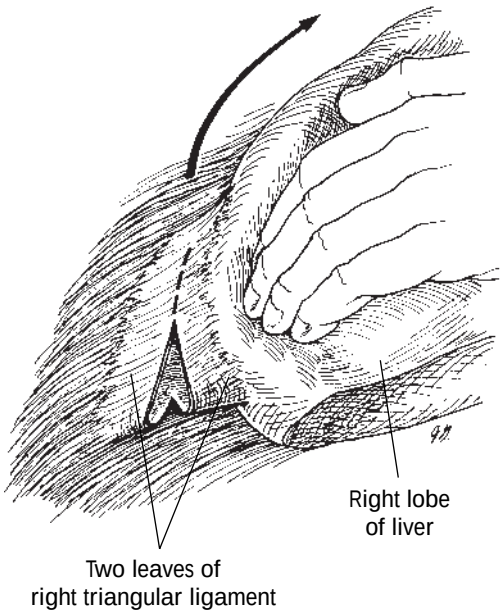

1-20

FIG. 1-20. The division of the right triangular ligament with its two leaves may need to extend toward the coronary ligament if the right lobe of the liver is large.

FIG. 1-21. Once these three liver ligaments are free and with the Finochetto retractor completely opened, the patient is placed in the Trendelenburg position. The liver can now be delivered and mobilized into the pleural cavity.

FIGS. 1-22 AND 1-23. Depending on the liver configuration, the surgeon should be able to mobilize part if not most of the liver into the chest. This maneuver provides the best exposure of the high retroperitoneal region on the right side.

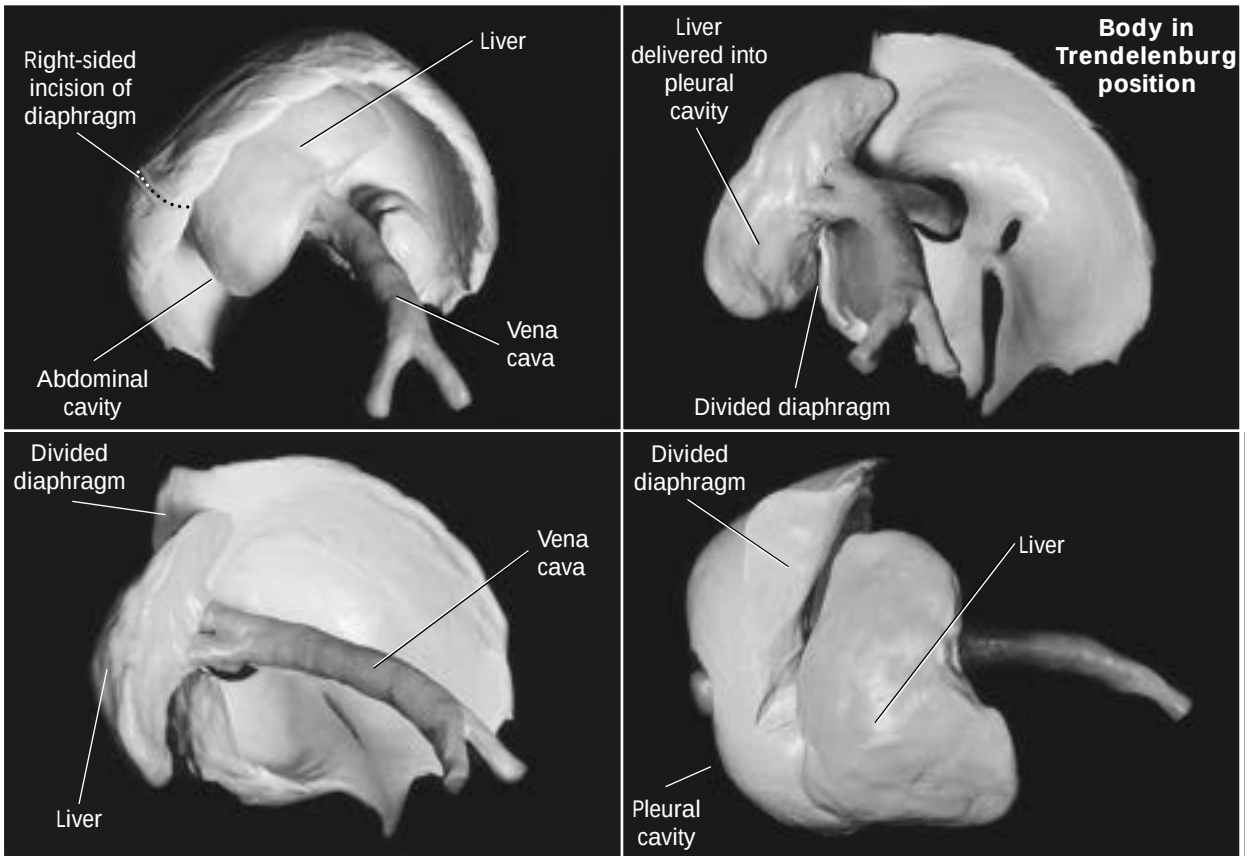

1-21

Liver Mobilized into Pleural Cavity with Patient in Trendelenburg Position

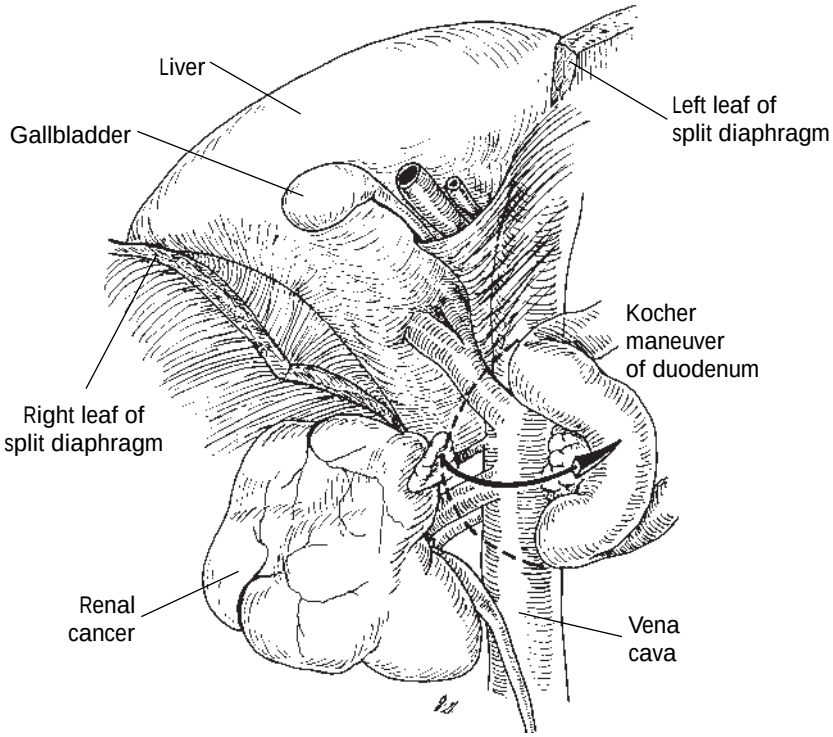

1-22

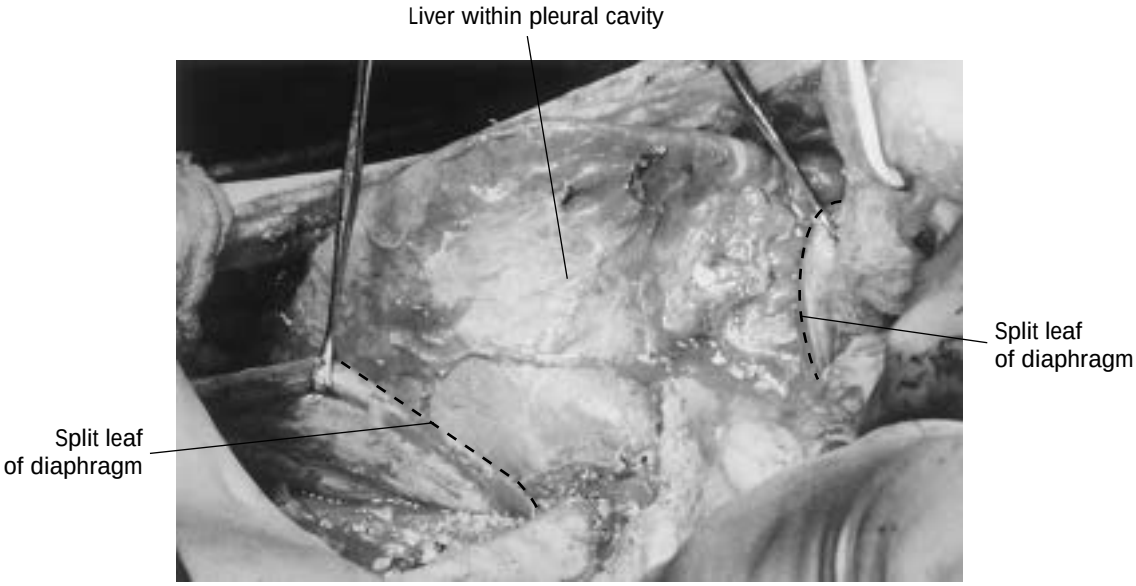

1-23

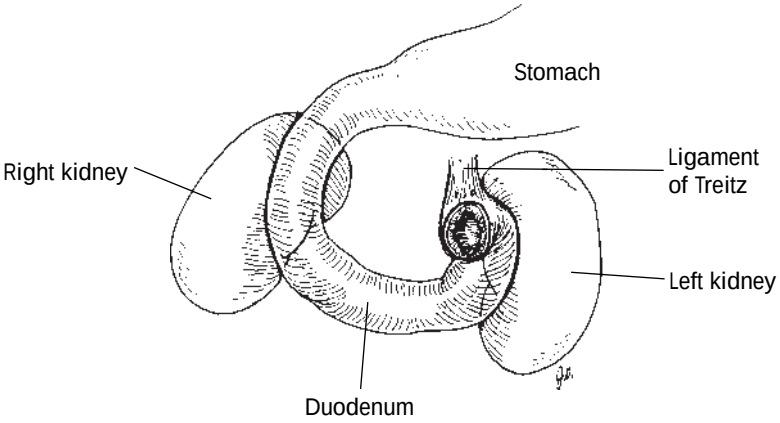

1-24

Kocher Maneuver

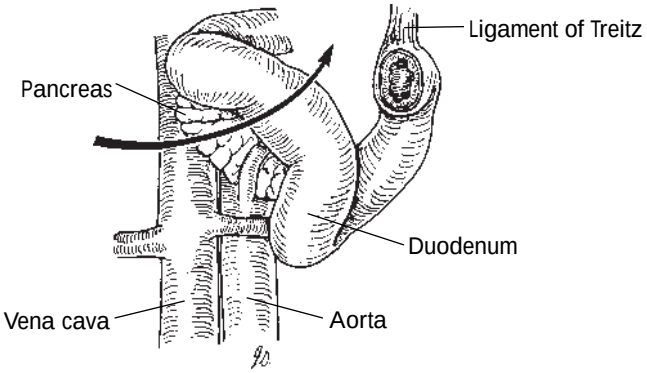

1-25

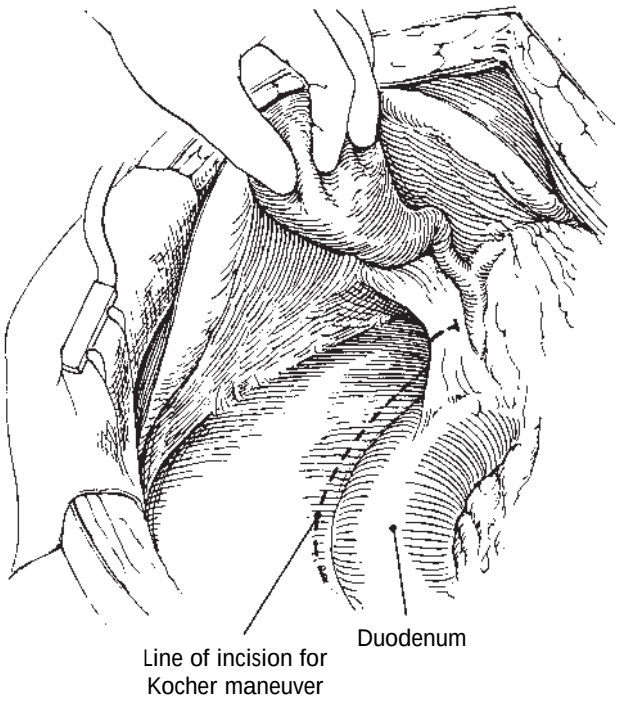

From Crawford ED, Borden TA, editors: *Genitourinary cancer surgery,* Philadelphia, 1982, Lea & Febiger.

1-26

FIGS. 1-24, 1-25, AND 1-26. The surgeon should perform a standard Kocher maneuver of the duodenum, reflecting the duodenum medially, thus exposing the renal pedicle and part of the vena cava.

FIG. 1-27. The vena cava at the renal pedicle has three important branches:

1 Renal vein
2 Gonadal vein inferiorly
3 Adrenal vein superiorly

Of the three, the most troublesome for potential bleeding is the adrenal vein. A torn adrenal vein is the most common bleeding site in right radical nephrectomy.

FIG. 1-28. The adrenal vein can be of a large caliber **(A),** can have a short segment to the vena cava **(B),** can be in the retrocaval position **(C),** or can be in a high position relative to the renal vein **(D).**

Even if there is easy access for isolation of the renal artery and vein, the surgeon should take ev-

Frontal View

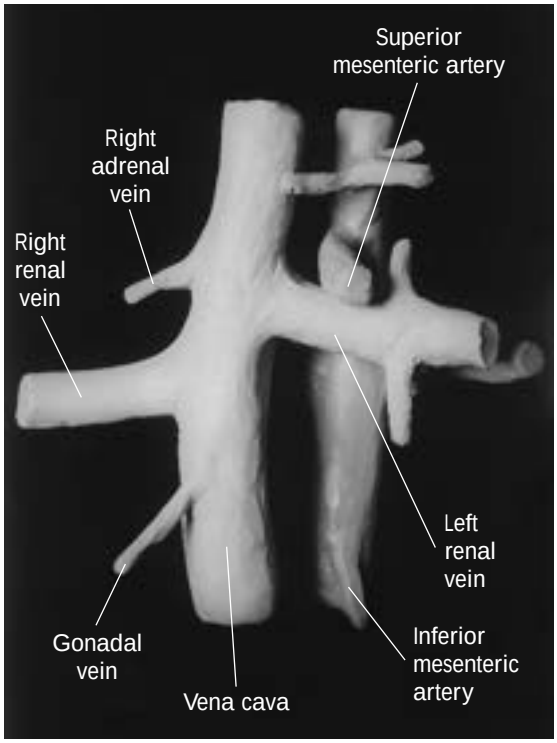

1-27

ery opportunity to control and divide the adrenal vein as soon as possible.

If the renal artery is identified and isolated, the surgeon should ligate it (using 0 silk) as soon as possible to decrease the size of the renal mass immediately.

Even though the venous system is exposed more easily than the arterial system, the surgeon should *never* ligate the renal vein first. The kidney can literally expand and rupture its precarious neovasculature. The order of ligation should be (1) renal artery, (2) renal vein, and then (3) ureter.

TUMOR THROMBUS

FIG. 1-29. Montie[9] has classified tumor thrombus based on the extent of intracaval involvement:

Level I: tumor thrombus extends less than 2 cm from the renal ostia

Level II: tumor thrombus extends greater than 2 cm from the renal ostia yet remains below the hepatic veins

Level III: tumor thrombus involves the hepatic veins but does not extend to the diaphragm

Level IV: tumor thrombus is supradiaphragmatic or atrial

The majority of cases of tumor thrombus with renal vein and vena cava involvement (greater than 60%) are at the renal and infrahepatic levels (levels I and II). This discussion is limited to these more common situations and recommends the current best operative references for intrahepatic, suprahepatic, and atrial tumor involvement; with venovenous bypass without heparinization; and with cardiopulmonary bypass with hypothermia.[6, 10-12]

Extraction of Tumor Thrombus from Renal Vein and Vena Cava

Most thrombi of renal carcinoma do not invade the wall of the renal vein or the vena cava and therefore can be removed without resection of the vascular walls.

Controlling the vena cava proximally and distally to the renal veins with Rummel vascular tourniquets or vessel loops without occluding the vessel is an invaluable safety measure in case of sudden hemorrhage.

FIG. 1-30. The Satinsky clamp or its equivalent is placed around the junction of the vena cava and the renal vein.

The renal vein incision should leave a proximal cuff intact with the vena cava. The tumor thrombus is gently teased out.

Variations of Adrenal Vein and Adrenal Gland

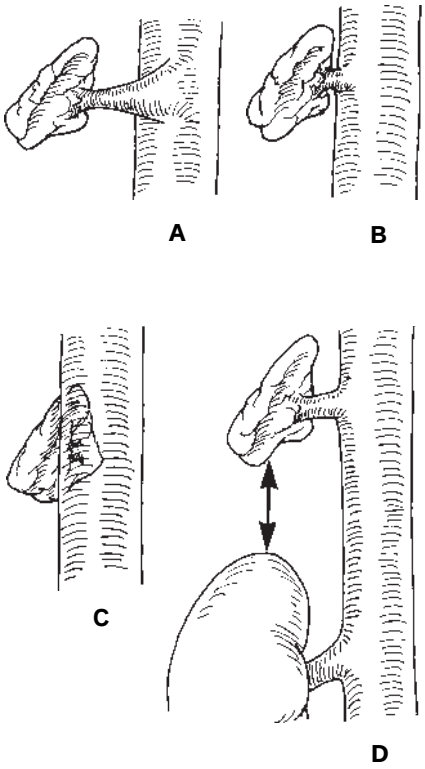

1-28

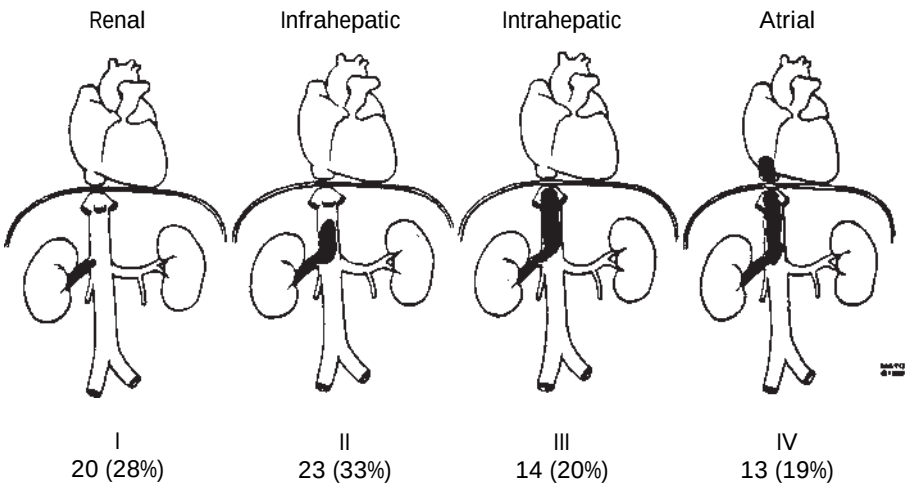

From Montie JE: Inferior vena cava tumor thrombectomy. In Montie JE, Pontes JE, Bukowski RM, editors: *Clinical management of renal cell carcinoma,* Chicago, 1990, Mosby.

1-29

Right Renal Vein with Tumor Thrombus

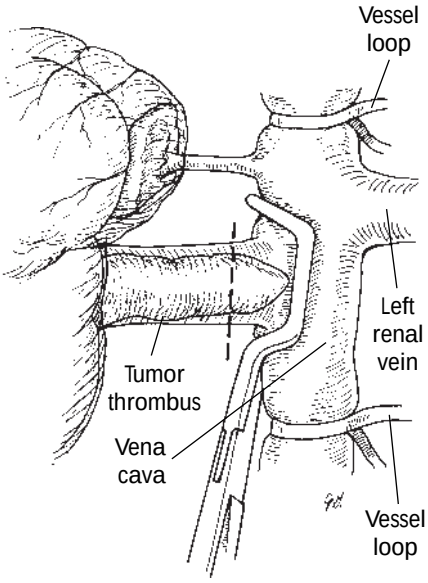

1-30

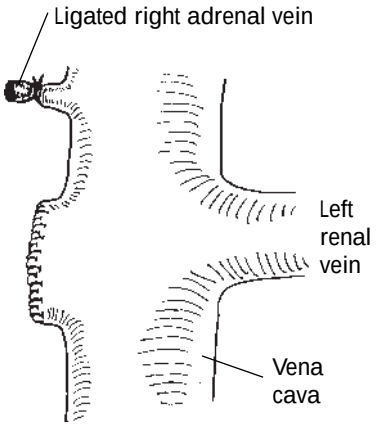

1-31

Renal Cancer with Large Tumor Thrombus Invading Renal Vein

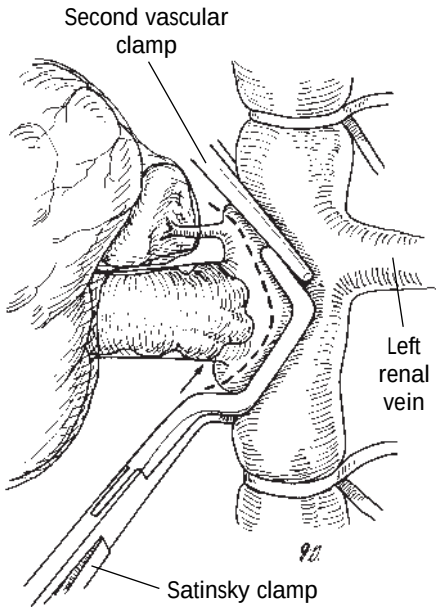

1-32

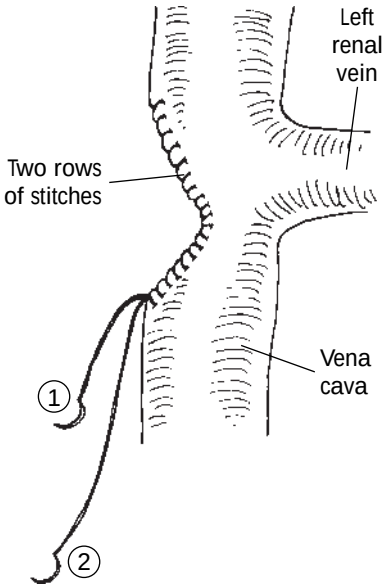

1-33

FIG. 1-31. The surgeon can close the venotomy with a double-arm stitch (4-0 Prolene), making two rows of a running stitch.

Rarely, the tumor thrombus has invaded the vascular walls.

FIG. 1-32. At times, a Satinsky clamp may be insufficient to go around a large, irregular configuration of a tumor thrombus, so an additional clamp is needed for complete occlusion.

To the extent possible, the surgeon should leave a part of the vena cava in continuity for venous flow return from the contralateral renal vein and lower vena cava.

The surgeon should wait after the clamps are placed and then check for hemodynamic changes by the blood pressure changes.

FIG. 1-33. Partial excision of the vena cava may be necessary with tumor invasion, and a double row of stitches for closure of the venotomy (4-0 Prolene double-arm sutures) should be performed. Small bleeding sites may be reinforced with an additional Prolene stitch.

Complete Occlusion of Vena Cava for Tumors Below Hepatic Veins

In situations in which complete occlusion of the vena cava is anticipated, the surgeon should first isolate the vena cava and ligate the lumbar veins in the region concerned.

FIG. 1-34. The usual collateral venous channels back to the heart are the azygos and hemiazygos veins. When these veins are obstructed by tumor involvement or scarring, then the inferior mesenteric vein becomes a main collateral channel and will be enlarged and dilated.

FIG. 1-35. If the tumor thrombus is higher than expected, it is important to first ligate and divide the small four to six veins to the caudate lobe of the liver. This maneuver gives the surgeon an extra 2 to 3 cm for more maneuverability during the vascular occlusion of the vena cava.

Posterior View of Retroperitoneal Anatomy

From Crawford ED, Das S: *Current genitourinary cancer surgery,* Philadelphia, 1990, Lea & Febiger.

1-34

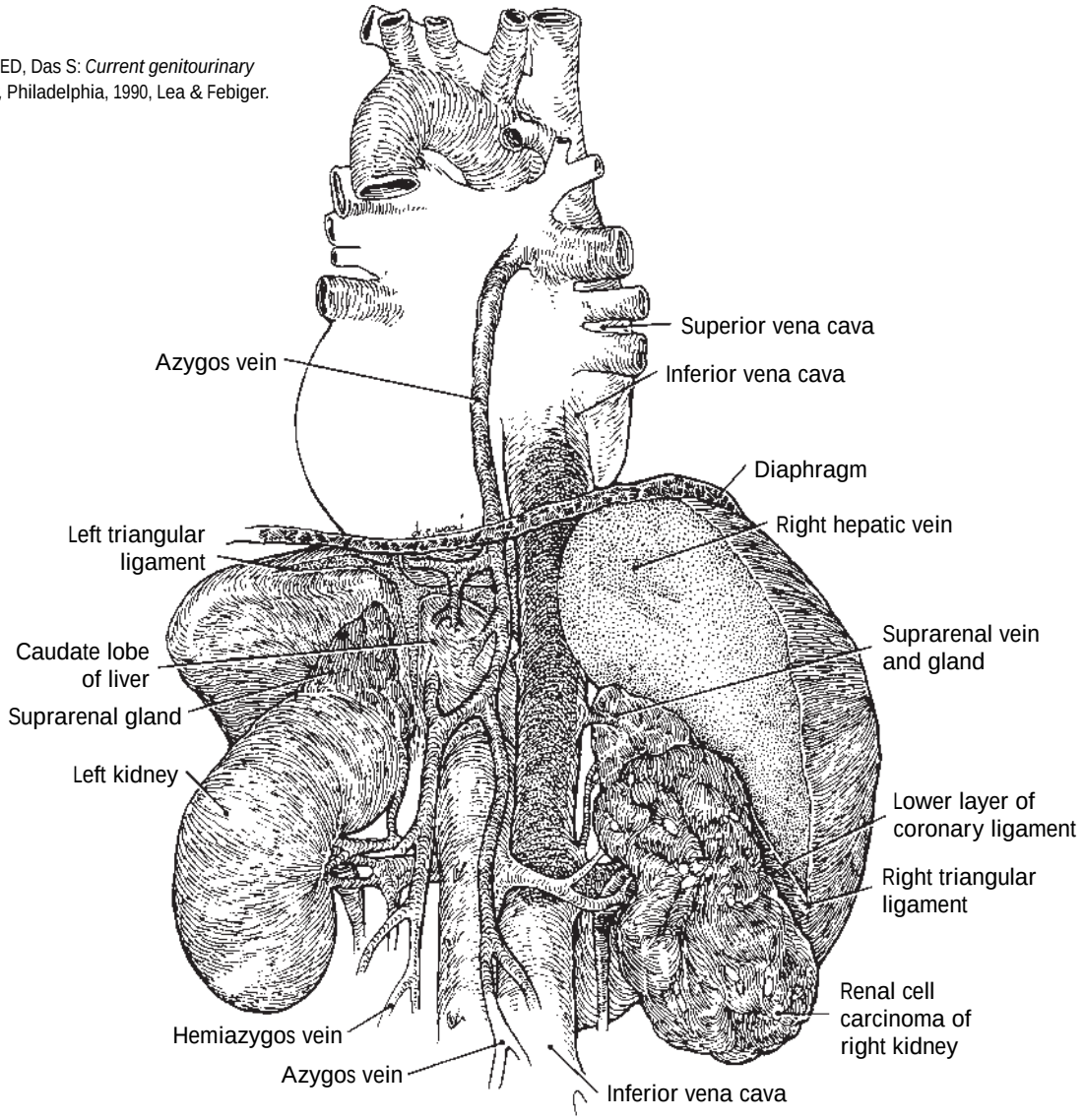

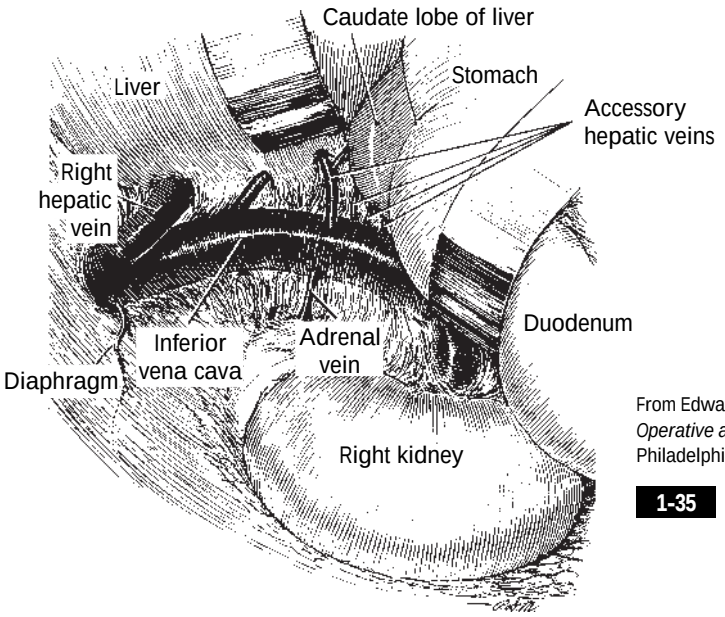

From Edwards EA, Malone PD, MacArthur JD: *Operative anatomy of abdomen and pelvis,* Philadelphia, 1975, Lea & Febiger.

1-35

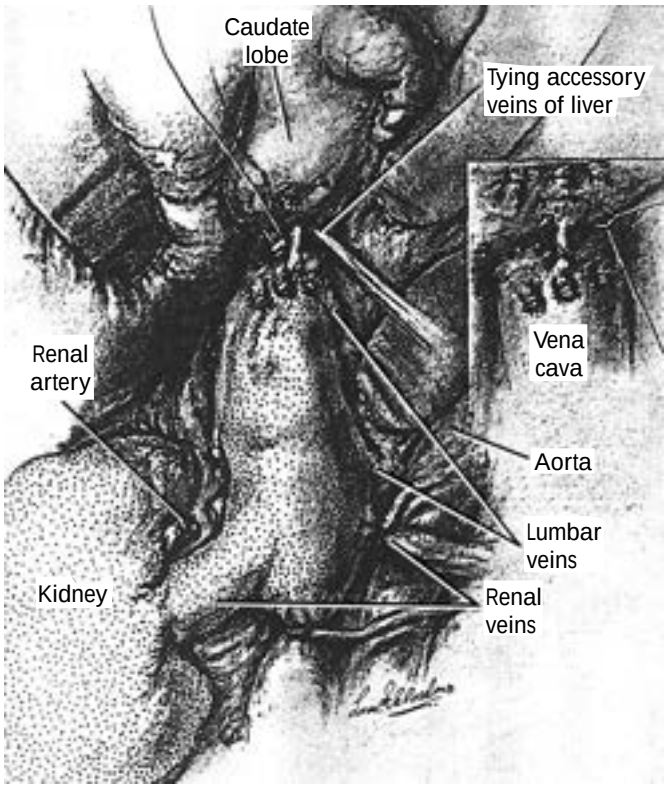

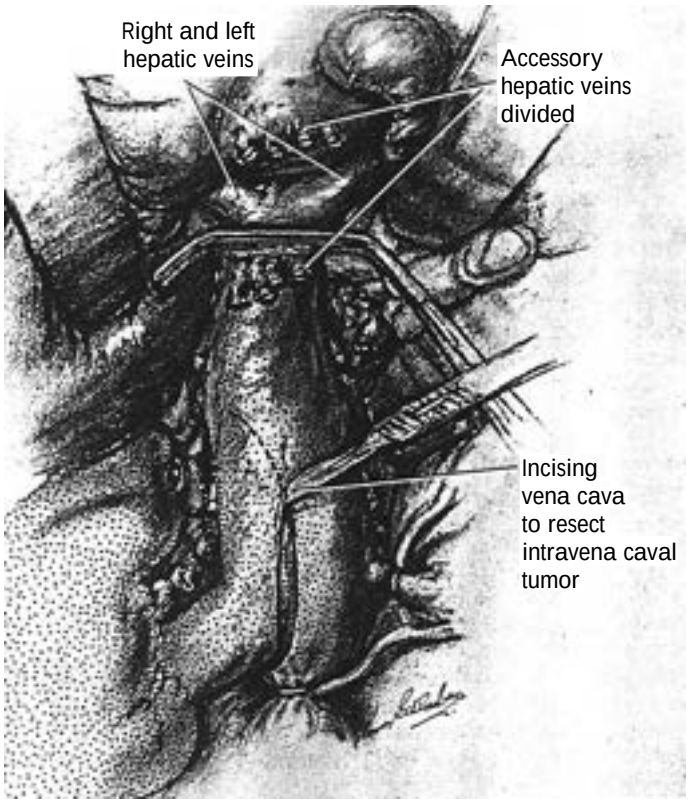

From Marshall FF et al: *J Urol* 139:1166, 1988.

1-36

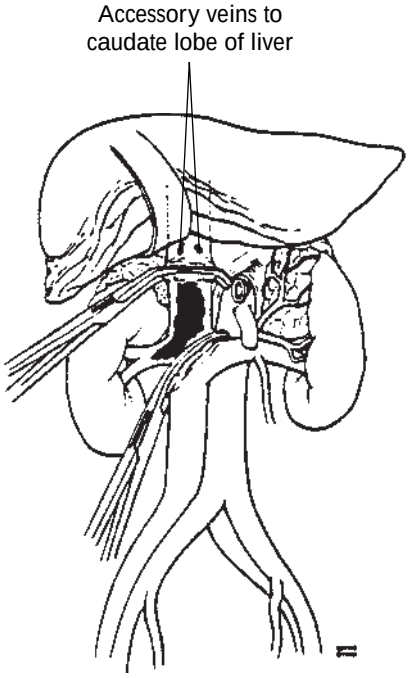

From Blute ML, Zincke H: Surgical management of renal cell carcinoma with intracaval involvement, *AUA Update Series,* lesson 17, vol XIII, 1994.

1-37

FIGS. 1-36 AND 1-37. The renal artery should be ligated as early as possible because the ligation will cause the renal tumor as well as the tumor thrombus to shrink. We prefer to use Rummel vascular tourniquets rather than vascular clamps whenever possible because they are more maneuverable and less traumatic to the vasculature.

The order of vascular occlusion should be as follows:

1. Ligation of veins to the hepatic veins.
2. Ligation of the renal artery.
3. Temporary occlusion of the vena cava proximally (cranial) and distally (caudad) and contralateral renal vein.

Closure of Cavotomy

FIG. 1-38. After the cavotomy and extraction of the tumor thrombus, the cavotomy can be reapproximated with a double-arm stitch (4-0 Prolene). When the cavotomy

is longer than the length of the Satinsky clamp, the surgeon may need to first reapproximate part of the venotomy and then apply the Satinsky clamp for closure of the remaining venotomy with the "venting" procedure. Reapproximation should be performed from cephalad to caudad.

Restoration of Vascular Continuity

The sequence of vascular restoration is important in the evacuation of trapped air and tumor and/or tissue debris before the systemic circulation is restored. The "venting" procedure is as follows:

1. Patient in 20-degree Trendelenburg position
2. Contralateral renal vein restoration
3. Aorta restoration if occluded
4. Distal (caudad) vena cava restoration with "venting" by temporary unclamping of the Satinsky clamp
5. Proximal (cranial) vena cava restoration with "venting"

The residual venotomy is then closed with two rows of double-arm stitches (4-0 Prolene).

LARGE RIGHT-SIDED RENAL CANCER

In situations in which safely identifying and isolating the renal pedicle and the adrenal vein are impossible, the surgeon should first mobilize the bowel as if to perform retroperitoneal lymph node dissection.

The surgeon should continue the right incision lateral to the ascending colon, come around the cecum, and up the mesentery to the ligament of Treitz.

The inferior mesenteric vein should be ligated and divided and the ligament of Treitz divided if necessary (see pp. 53-54). The bowel is placed in a bowel bag and reflected cephalad on the chest. This maneuver allows the surgeon to work right over the great vessels.

FIG. 1-39. As in a retroperitoneal lymph node dissection, the surgeon performs a split-and-roll maneuver over the vena cava and the aorta (see p. 58) and works laterally to expose the right renal artery, renal vein, and adrenal vein.

The surgeon should always tie the renal artery first and then the vein. The arterial occlusion often will decrease the volume of the renal mass. Double proximal ties (0 silk) and one distal tie are placed for both the artery and vein.

The adrenal vein should not be clipped but tied (3-0 or 4-0 silk).

Clips should not be used on the tumor side because they often slip and lead to back-bleeding.

Closure of Venotomy After Tumor Extraction

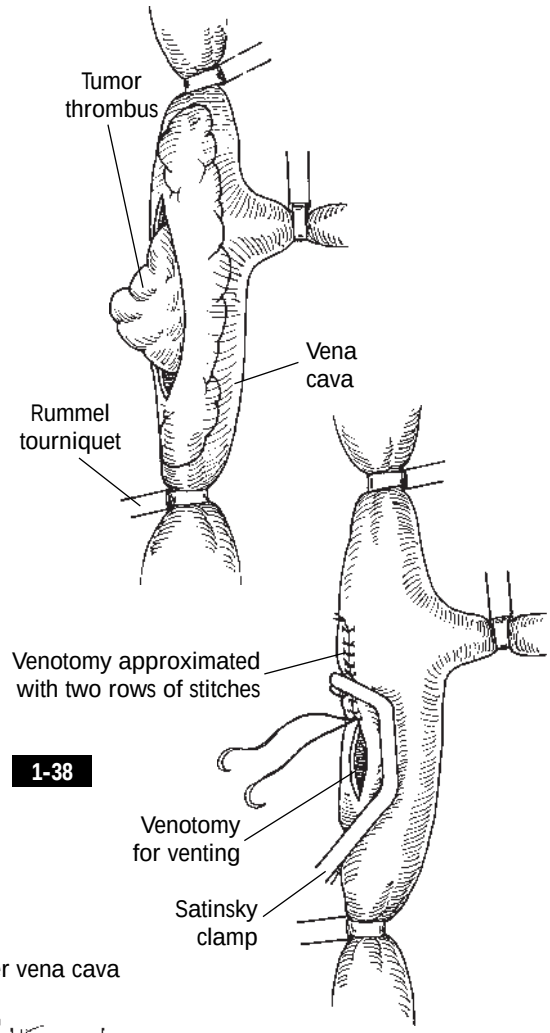

1-38

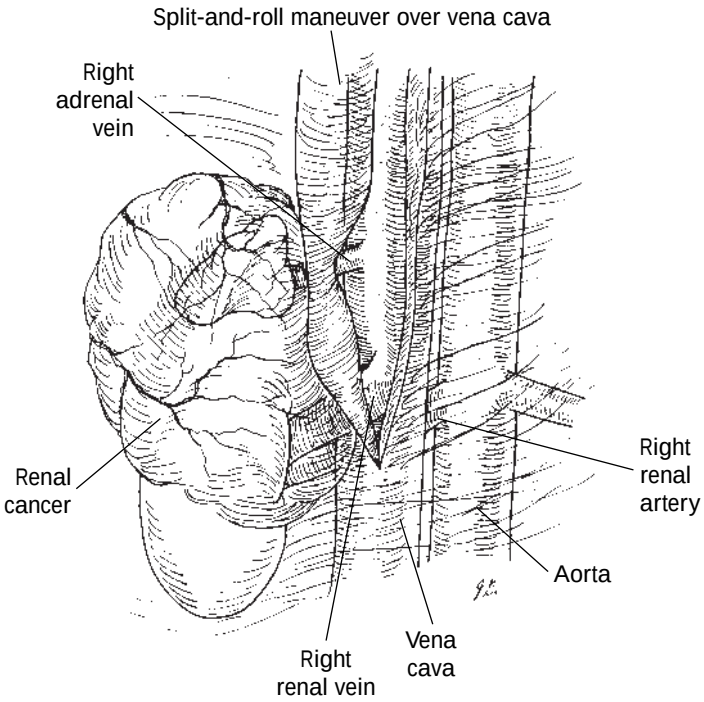

1-39

LEFT-SIDED RENAL CANCER

The surgeon incises the parietal peritoneum along the line of Toldt lateral to the descending colon from the sigmoid colon all the way up and around most of the splenocolic ligament.

Before the surgeon divides the splenocolic ligament, the Finochetto retractor is placed between two dry laparotomy pads against the ribs and opened. This maneuver provides excellent exposure for the proximal diaphragmatic division and the splenocolic ligament division.

Because the spleen is smaller than the liver, the diaphragmatic incision does not need to be as extensive as on the right side.

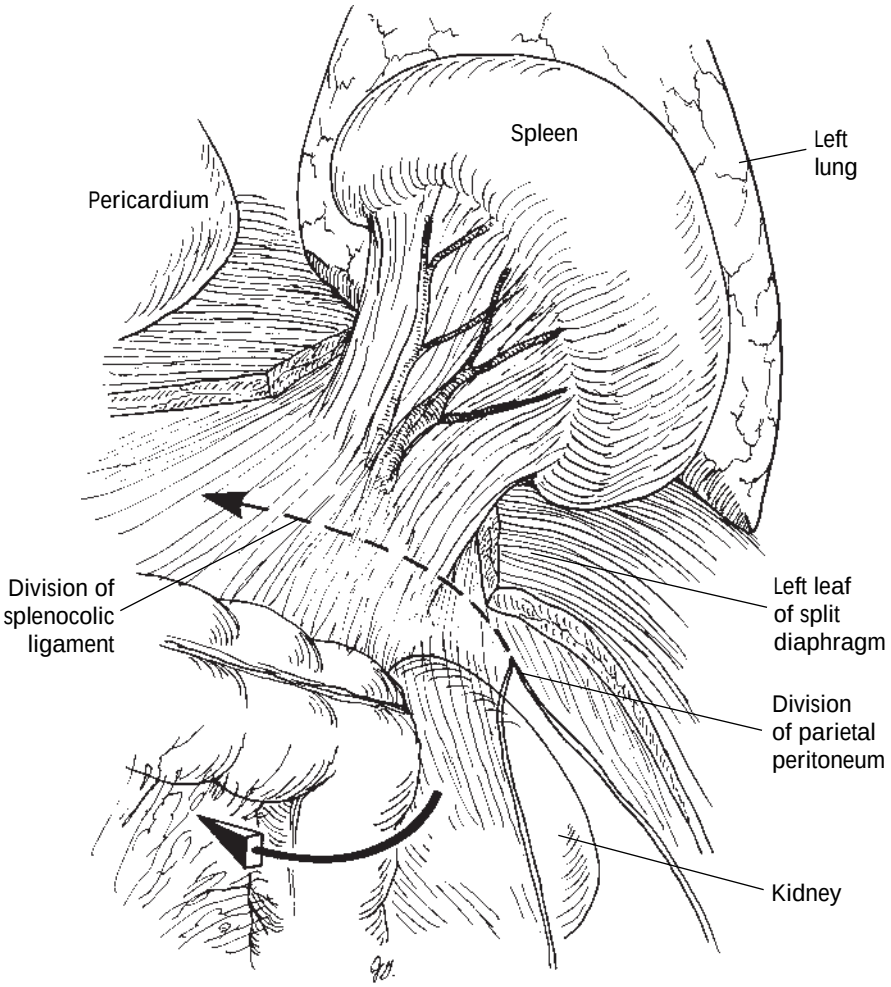

1-40

FIG. 1-40. The patient is positioned in the Trendelenburg position, and the spleen is delivered into the pleural cavity.

FIG. 1-41. We prefer first to dissect a plane between the kidney and the psoas muscle *(1)*, then isolate the ureter for later ligation and division, and then dissect a plane between the parietal peritoneum and the renal pedicle *(2)*.

FIG. 1-42. An alternative to placing the spleen into the pleural cavity is performing a medial splenopancreatic roll. This technique is especially useful in the case of large, upper pole tumors. The left gastric vessels and the inferior mesenteric vein are ligated, and circumferential dissection around the splenopancreatic segment is performed. This incision extends around the splenic pedicle and continues around the fundus of the stomach to a point near the esophageal hiatus **(A).** Using the spleen as a handle, the surgeon mobilizes the splenopancreatic segment, freeing its posterior attachments **(B).**

FIG. 1-43. This maneuver displaces the spleen and pancreas into a medial position, thus defining the plane between the Gerota's fascia and the peritoneum and exposing the renal pedicle and the entire retroperitoneum for surgery.[3]

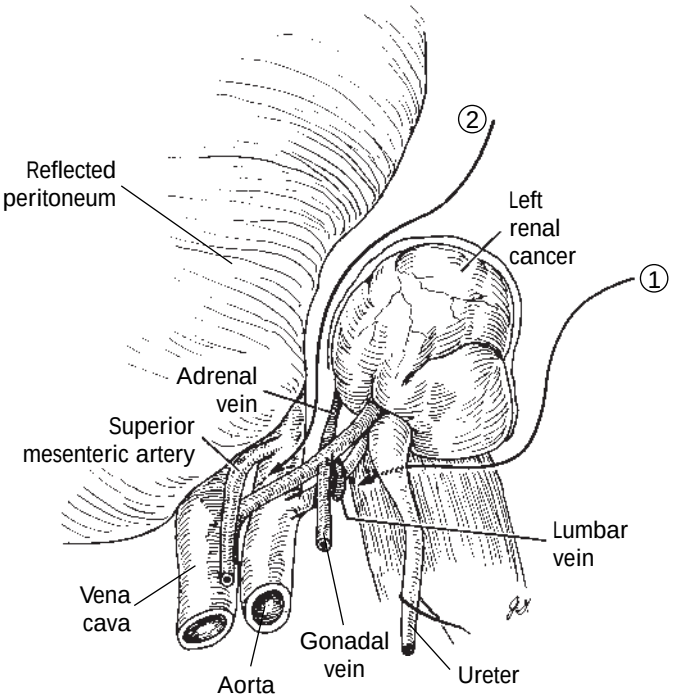

1-41

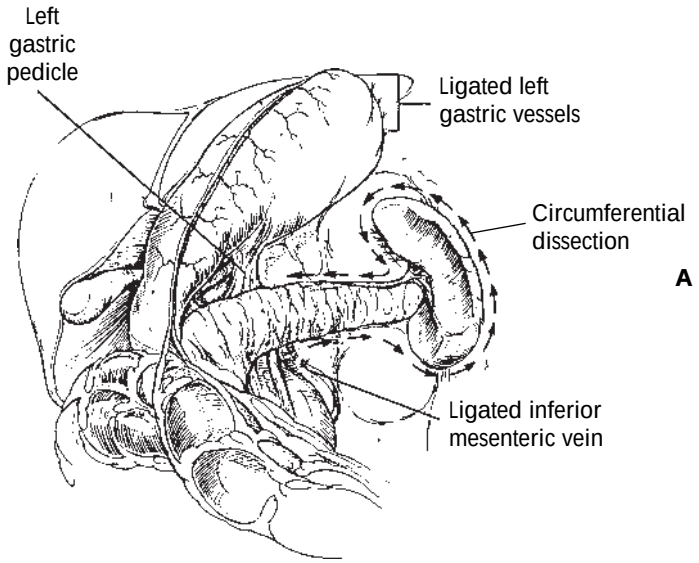

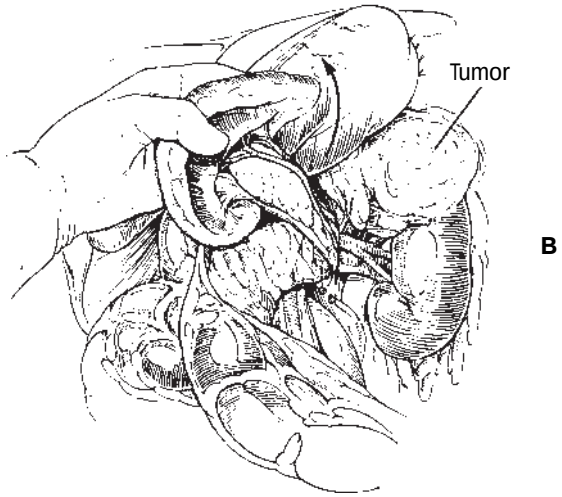

From Marsh CL: *Contemp Urol* 6(8):15-20, 1994.

1-42

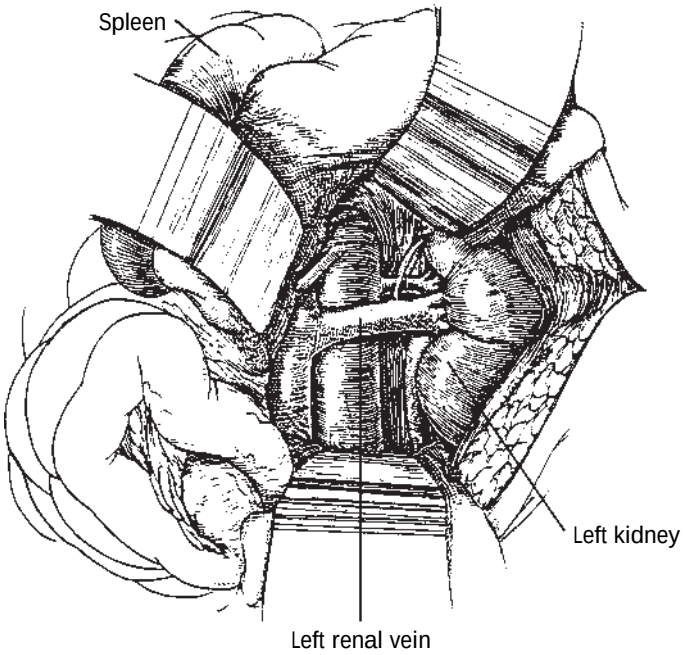

From Crawford ED, Borden TA, editors: *Genitourinary cancer surgery,* Philadelphia, 1982, Lea & Febiger.

1-43

Left Lateral View of Renal Vasculature

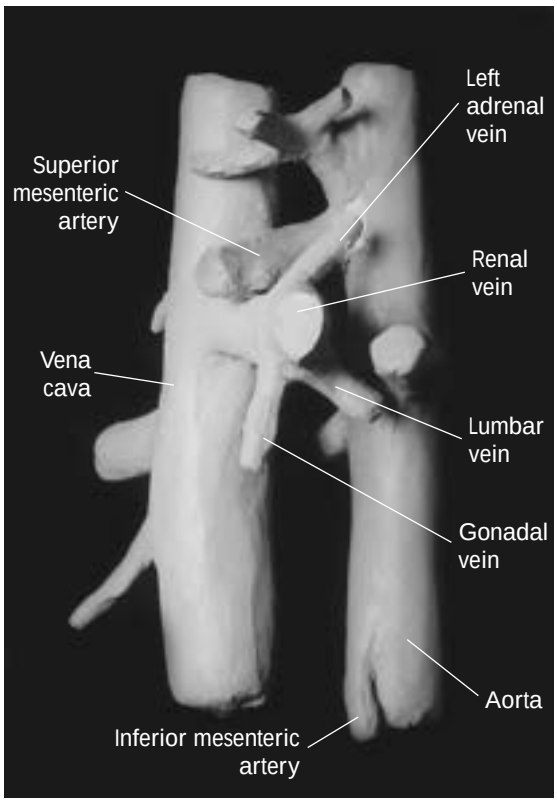

1-44

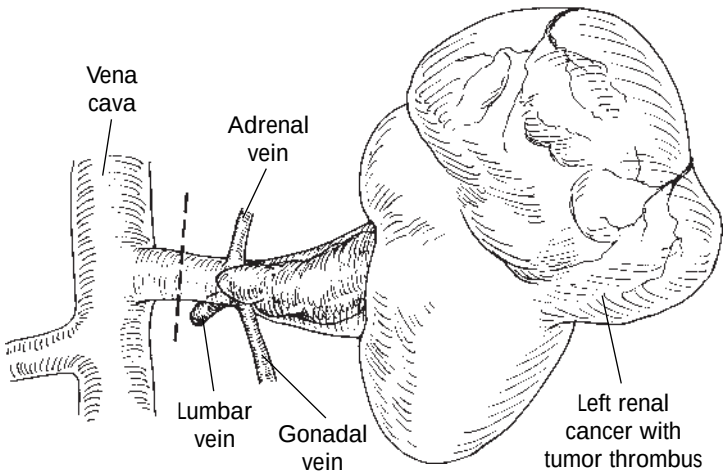

1-45

FIGS. 1-44 AND 1-45. On the left side, the venous tributaries from the renal vein are the following:

1 Gonadal vein
2 Adrenal vein
3 Lumbar vein

If all three tributaries from the renal vein have been divided, the surgeon's best option is to ligate and divide the renal vein more proximally or distally, especially in cases with a small tumor thrombus.

FIG. 1-46. Of the three, the lumbar vein is the most troublesome because it drains from the posterior aspect, often is not visualized, and can have anomalous anatomic variations.

It is wise first to ligate the adrenal vein, gonadal vein, and lumbar vein before performing the nephrectomy.

Again, the renal artery should always be ligated first to decrease the volume of renal mass.

Variations in Anatomy of Lumbar Vein

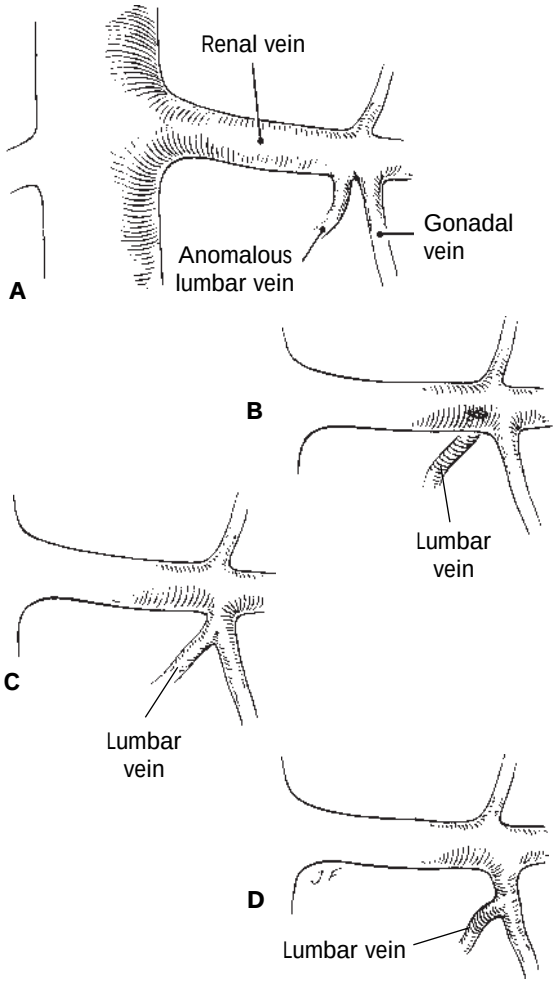

From Crawford ED, Borden TA, editors: *Genitourinary cancer surgery,* Philadelphia, 1982, Lea & Febiger.

1-46

MEDIAL LARGE LEFT RENAL CANCER

If the surgeon has difficulty even approaching the renal pedicle because of a large, medially placed cancer, an alternative maneuver should be used.

As on the right side, exposure should be gained by an incision carried from the foramen of Winslow around the ascending colon and cecum, and toward the ligament of Treitz.

FIGS. 1-47 THROUGH 1-50. With large left-sided renal tumors or retroperitoneal masses for which it is necessary to mobilize the superior mesenteric artery and part of the pancreas, the surgeon should divide the inferior mesenteric vein to gain the maximal exposure of the vasculature and the adjacent organs. This approach differs from the mesenteric incision, which is made medial to the inferior mesenteric artery and is used in cases of trauma.[13] The inferior mesenteric vein varies in its communication with the portal venous drainage and may act as a barrier for a full exposure of the great vessels and their major branches (more commonly configuration *1* than *2* in Fig. 1-49).

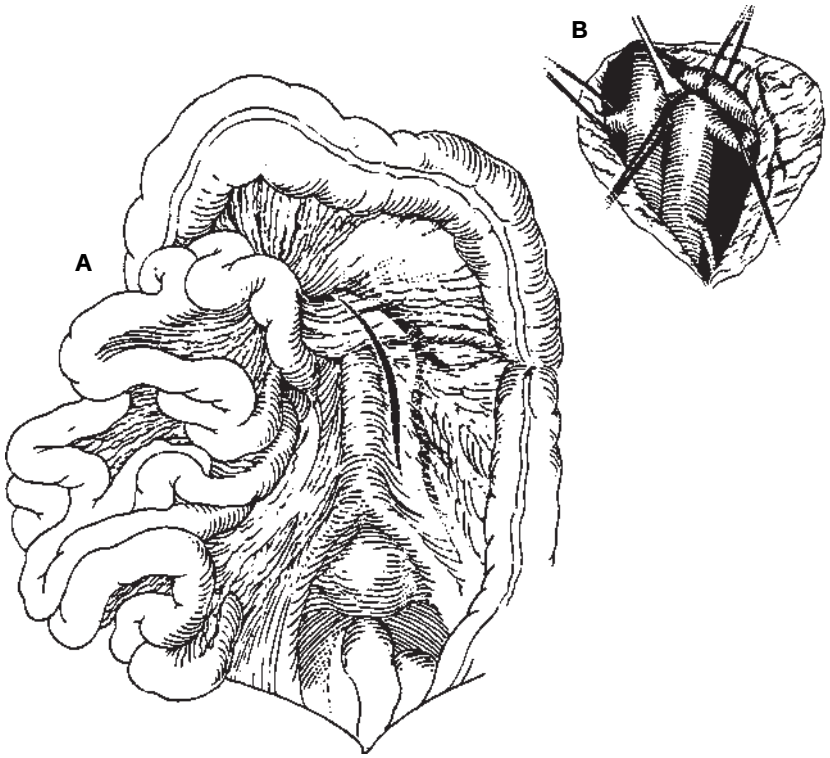

From McAninich JW, Carroll PR: *J Trauma* 22:285, 1982.

1-47

Variations in Anatomy of Inferior Mesenteric Vein

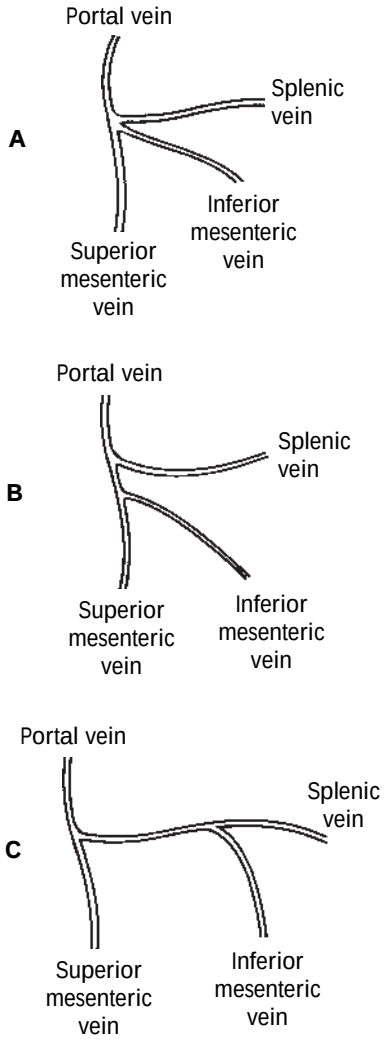

1-48

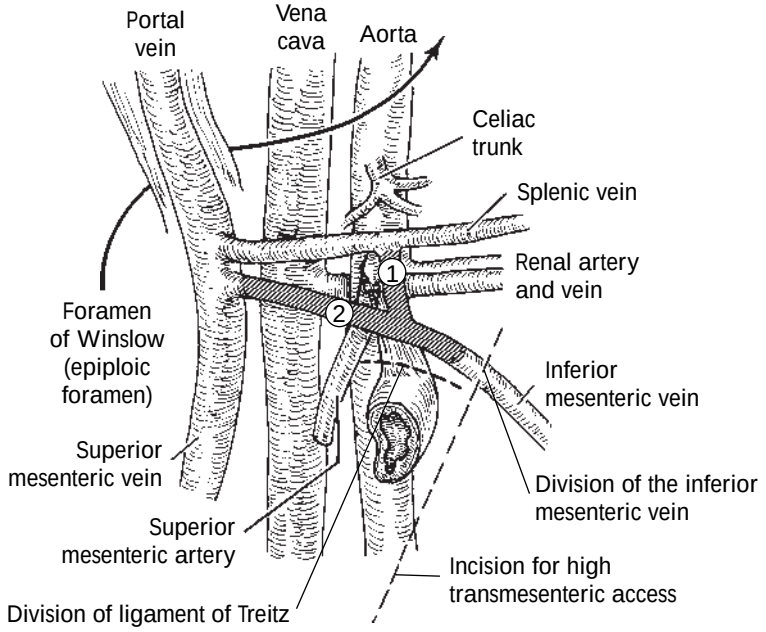

1, most common configuration of inferior mesenteric vein
2, possible configuration of inferior mesenteric vein

1-49

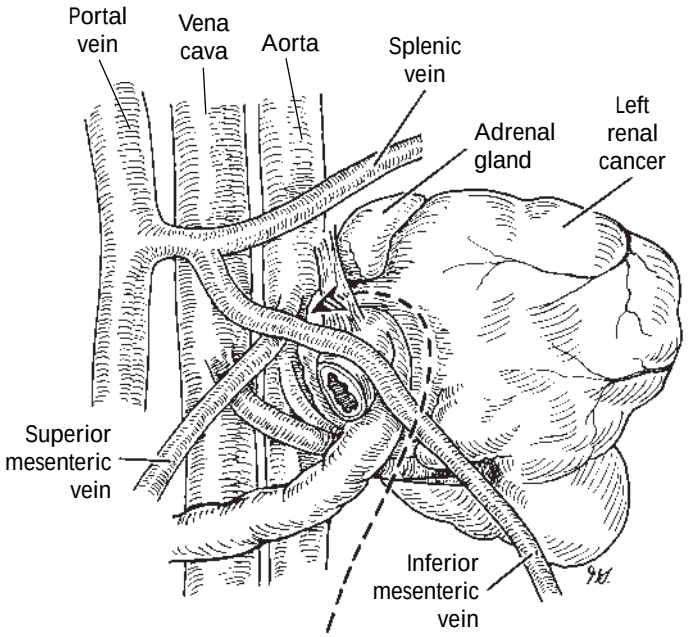

Transmesenteric access with division of the inferior mesenteric vein and ligament of Treitz in large, medially placed left renal cancer

1-50

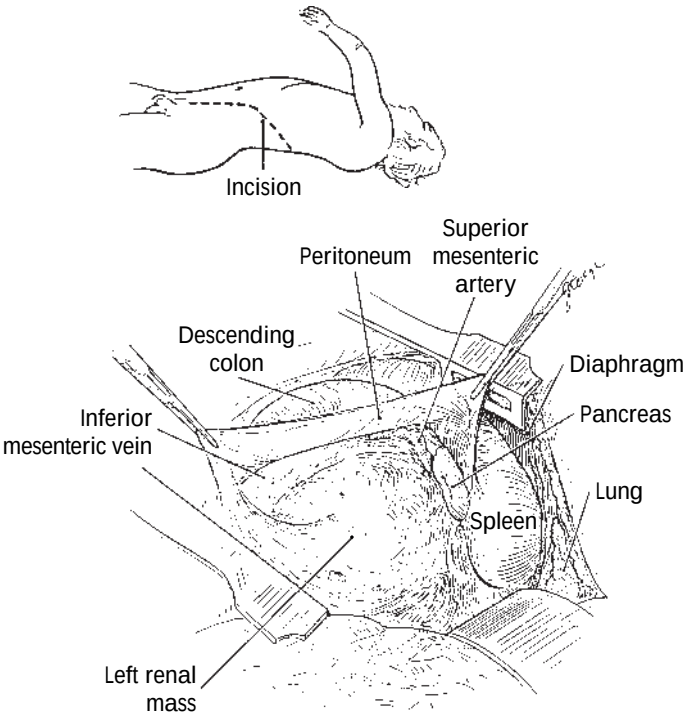

From Skinner DG: *Urol Clin North Am* 5:253, 1978.

1-51

Anterior View

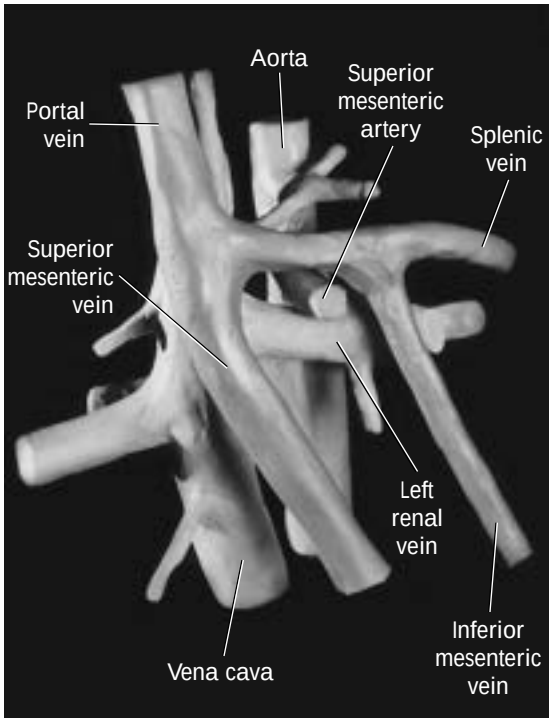

1-52

FIGS. 1-51 AND 1-52. By following the inferior mesenteric vein up to its junction with the splenic vein, the surgeon can identify the region of the superior mesenteric artery,[14] an important landmark for both right- and left-sided dissections. Once the inferior mesenteric vein and the ligament of Treitz are divided (there are small vessels within the ligament), the bowel is reflected cephalad.

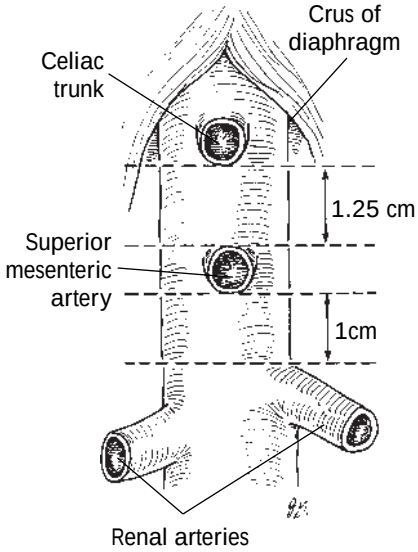

1-53

FIG. 1-53. The left renal artery is only 1 cm below the superior mesenteric artery.

SUPERIOR DISSECTION OF ADRENAL GLAND

For both left and right adrenal gland resection, the first maneuver is to ligate and divide the adrenal vein(s). The surgeon must slide the left fingers on either side of the adrenal gland and apply a downward traction while the right hand applies clips above the gland. The residual lymphatics and the ureter are divided to complete the excision of the renal mass.

CLOSURE OF DIAPHRAGM AND RIB REAPPROXIMATION

FIG. 1-54. The reapproximation of the diaphragm is best performed by a Teflon felt pledget "sandwiching" technique, whereby a mattress stitch (0 silk) and two felt pledgets sandwich the two leaves of the diaphragm. These pledgets are placed on the abdominal side rather than on the pleural side.

The ribs are reapproximated using two interrupted stitches (1-0 Prolene).

FIG. 1-55. One or two chest tubes are placed, and the more dependent tube suctions fluid and blood if the patient is placed in a semiupright position (head up 30 degrees) postoperatively.

LIVER INJURIES

When inadvertent blunt trauma to the liver occurs secondary to excessive pressure from a retractor blade, the following maneuvers are useful to stop liver hemorrhages:

1. The Pringle maneuver with finger compression anterior to the foramen of Winslow will occlude the hepatic artery[6] (see pp. 8-9).
2. The surgeon can manually compress the lacerated area.
3. Avitene placed between a Surgicel sandwich can be packed into the laceration with compression.
4. Fibrin glue (Hemaedics, Inc., Malibu, Calif.) can be used to occlude the wound.
5. The argon beam coagulator is a useful adjunct (Birtcher/Solos Medical Systems, Irvine, Calif.).
6. A Teflon felt pledget sandwiching technique applied to either side of the laceration usually occludes the bleeding edges.

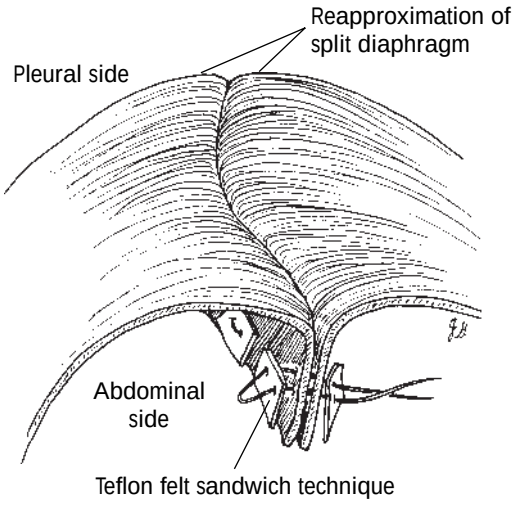

1-54

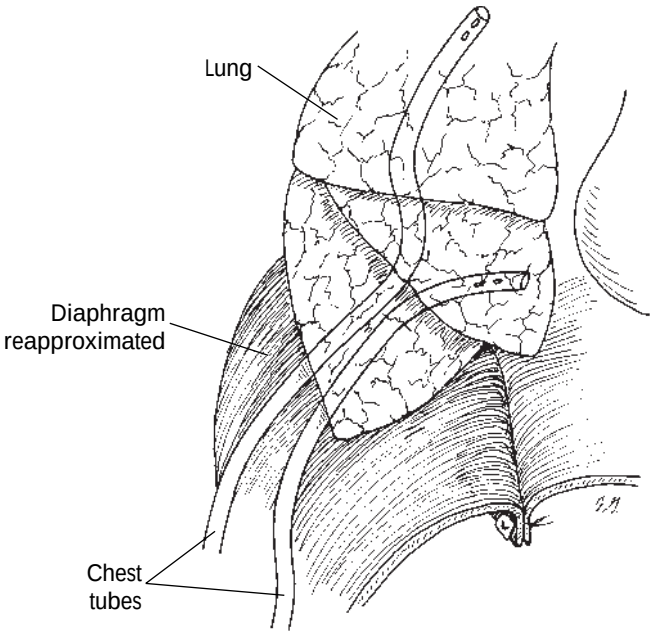

1-55

KEY POINTS

THORACOABDOMINAL INCISION

- An eighth or a ninth interspace incision is made from the posterior axillary line all the way across the contralateral rectus abdominis muscle.
- A straight diagonal incision is preferable to the combination of a diagonal incision with a vertical extension below.
- The diaphragm is split toward the great vessels, first without the retractor and then with the Finochetto retractor opened.
- The peritoneum is opened and nasal gastric tube is positioned.

RIGHT RENAL CANCER

- Incision and mobilization are performed along the line of Toldt up to the foramen of Winslow.
- The Finochetto retractor should be placed with a dry laparotomy pad on each side of the ribs to prevent slippage.
- Once the Finochetto retractor has been opened halfway, the diaphragm should be incised all the way to the central tendon, avoiding any major phrenic branches.
- The incision along the line of Toldt lateral to the colon is now extended medially into the foramen of Winslow.
- The three ligaments of the liver are divided.
- The patient is placed in the Trendelenburg position and the liver is mobilized into the pleural cavity.
- The surgeon first reflects the colon medially and then performs a Kocher maneuver of the duodenum.
- The vena cava and renal pedicle are exposed.
- It is important to divide the adrenal vein early.
- The renal artery is divided before the renal vein.
- The ureter and gonadal vessels are divided.
- Large tumor thrombus in the vena cava below the hepatic veins may require ligation of lumbar veins, veins to the caudate lobe of the liver, and complete occlusion of the vena cava.
- The order of restoration of venous continuity after vena cavotomy is important to avoid air and debris embolus.
- For large tumors in which exposing the renal pedicle is difficult, the incision must be continued around the cecum up the ligament of Treitz to gain medial access to the great vessels and their branches.
- A split-and-roll maneuver should be carried out over the vena cava to expose the renal vein and the adrenal vein and over the aorta to expose the renal pedicle.
- Arterial ligation, performed before venous occlusion, decreases the volume of the renal mass.
- The tissues holding the adrenal gland from above are clipped and divided from lateral to medial.

LEFT-SIDED RENAL CANCER

- Incision and mobilization are performed along the line of Toldt lateral to the descending colon up the splenocolic ligament.
- Before division of the splenocolic ligament, the Finochetto retractor is put in place with two dry laparotomy pads.
- Diaphragmatic division is completed but it does not extend to the central tendon.
- Division of the splenocolic ligament is performed.
- The patient is placed in the Trendelenburg position and the spleen is delivered into the pleural cavity.
- The left colon is reflected medially.
- The gonadal vein, adrenal vein, and lumbar vein are ligated and

divided before nephrectomy is performed.

- The renal artery and renal vein are isolated.
- With a large medial tumor, the incision is made on the line of Toldt lateral to the right colon and is carried from the ascending colon, around the cecum, and along the route of the mesentery.
- The aorta and the vena cava are exposed by a split-and-roll maneuver of the overlying tissue and the renal vein and artery are isolated from a medial approach.
- Closure of the diaphragm is performed with a pledget sandwiching technique.
- Chest tubes are placed and the ribs are reapproximated.

POTENTIAL PROBLEMS

- *Liver laceration:* Six options: perform Pringle maneuver, apply manual compression, apply compression with Surgicel, seal wound with fibrin glue, use argon beam coagulator, perform Teflon felt sandwich technique, or call for surgical consultation for possible partial liver resection
- *Splenic laceration:* Proceed as for liver laceration → if hemorrhage is severe, perform splenectomy
- *Inferior mesenteric artery injury*: Ligate and proceed with surgery
- *Adrenal vein and vena cava laceration:* Apply three-finger compression of proximal vena cava → clamp vena cava → close with running stitch (4-0 Prolene)
- *Difficult exposure of left renal pedicle because of large tumor:* Divide root of mesentery → divide inferior mesenteric vein → isolate great vessels → perform split-and-roll maneuver → identify superior mesenteric artery and pancreas → isolate and divide left renal artery and then renal vein
- *Diaphragm muscle torn in reapproximation:* Use Teflon felt pledget sandwich technique

SPLENIC HEMORRHAGE AND SPLENECTOMY

Vigorous retractor compression especially by the Harrington retractor can lead to contusions and lacerations of the liver, pancreas, and spleen. In most cases manual compression alone is sufficient to arrest small injuries. When splenic laceration results in more persistent bleeding, other maneuvers must be considered.

Minor Splenic Hemorrhage

If there is a small wedge of macerated spleen with a slow hemorrhage, the surgeon should first try manual compression.

An alternative is to insert a Surgicel sandwich with Avitene in between using manual compression.

FIG. 1-56. If the bleeding continues, the surgeon can apply synthetic hemostatic gauze or omentum over the defect and place mattress sutures (0 chromic) to secure it. Bolsters of hemostatic gauze can be inserted under the suture loops, or a compressive Teflon felt sandwich technique using a mattress stitch (0 chromic) can be performed. The hemostatic gauze or Teflon felt provides support on both sides of the organ and prevents the suture from tearing through the organ while providing compression. We use the sandwiching technique for splenic, liver, kidney, and diaphragmatic closures (see Fig. 1-54).

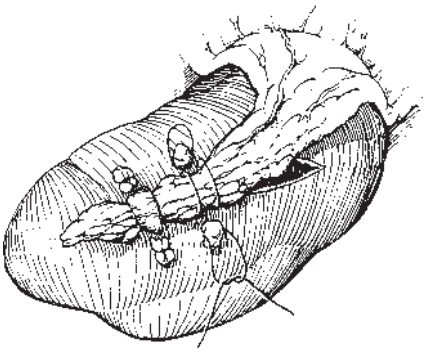

From Hinman F Jr: *Atlas of urologic surgery,* Philadelphia, 1989, WB Saunders.

1-56

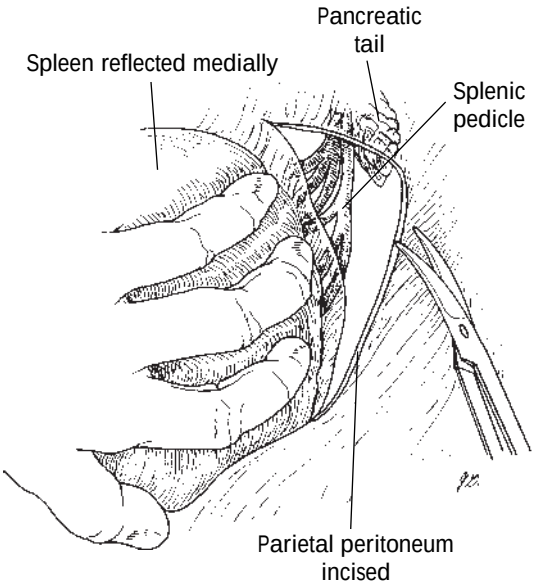

1-57

Massive Hemorrhage from Splenic Laceration

Posterior Approach

FIGS. 1-57 AND 1-58. When sudden splenic hemorrhage obliterates the operative field, the surgeon's first maneuver is to place the *left palm* over the spleen with the fingers as close to the pedicle as possible. The surgeon should rotate the spleen medially while compressing the organ.

Instead of using suctioning, the surgeon and assistant should literally *"scoop" the blood out* with dry laparotomy pads. This technique is the easiest and fastest way to clear the operative field of large amounts of blood that may be partially coagulated. Suctioning is useful only after the bulk of blood has been evacuated.

With the right hand, the surgeon can now divide the parietal peritoneal attachments inferiorly, laterally, and then superiorly and occasionally on the diaphragm. The lower pole is freed, if adherent.

As the spleen is rotated medially, the surgeon must be careful to expose the splenic pedicle while avoiding injury to the pancreatic tail.

The critical maneuver is to find *not* the branches but the more proximal main splenic artery and ligate it. This ligation will slow down the bleeding immediately as well as decrease the size of the spleen. The surgeon can then continue the posterior approach, divide the splenic vein, and complete the splenectomy.

Anterior Approach

If the posterior approach is difficult, the assistant's dominant hand can be placed over the region of the splenic pedicle and compression applied while the surgeon focuses on an anterior approach.

Even after ligation of the splenic artery from behind, in some situations access for the splenectomy is better using the anterior than the posterior approach.

FIGS. 1-58 AND 1-59. The gastrosplenic ligament, containing the left gastroepiploic artery and the short gastric arteries, is ligated and divided. This maneuver separates the stomach from the omentum.

The exposure should be such that the greater curvature of the stomach can be reflected cephalad, providing a window to the pancreas and the splenic pedicle.

Avoiding any injury to the pancreas, the surgeon then ligates and divides both the splenic artery and vein.

Spleen and Its Relations As Seen From Below

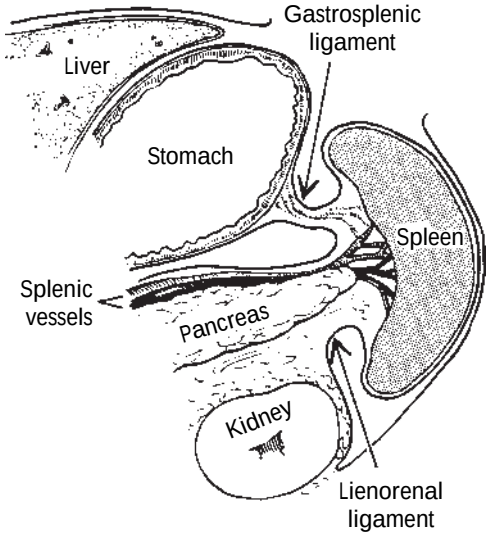

From Bowers WF, Hewlett TH, Thomas GJ: *Manual of surgical technique,* Springfield, Ill, 1963, Charles C Thomas.

1-58

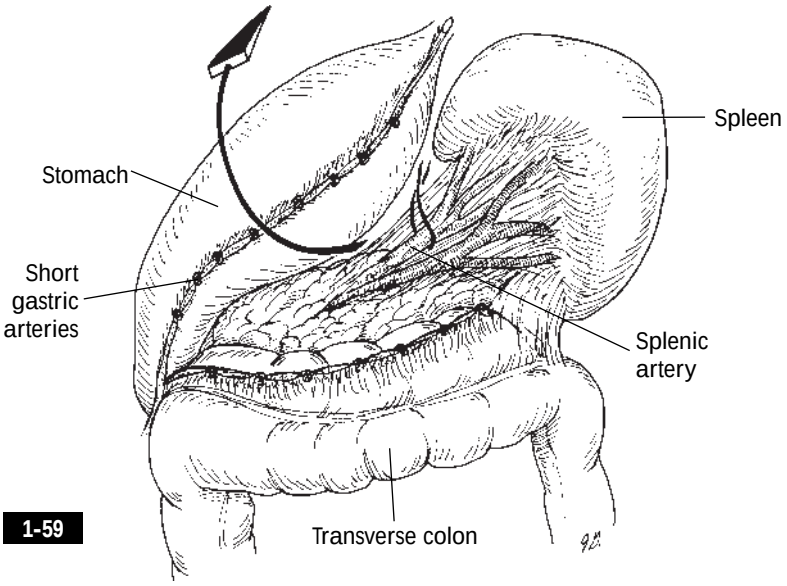

1-59

KEY POINTS

POSTERIOR APPROACH

- Using the left hand, the surgeon medially rotates the spleen while compressing the organ.
- Evacuation of blood is performed using laparotomy pads.
- Via the posterior approach, the peritoneal attachments are divided and the splenic pedicle and pancreatic tail are identified.
- Division of the peritoneal attachments and short gastric arteries is performed.
- The arterial system of the splenic artery is ligated.
- The splenic vein is ligated.

ANTERIOR APPROACH

- The gastroepiploic and short gastric arteries are divided, separating the omentum from the stomach.
- The stomach is reflected superiorly, and ligation and division of the splenic artery and then the splenic vein are performed.

POTENTIAL PROBLEMS

- *Massive hemorrhage:* Apply compression to the spleen → evacuate blood with dry sponge (do not use suction device because it is not quick enough)
- *Posterior dissection with injury of tail of pancreas:* Continue procedure and consider a surgical consultation for inspection and drain placement
- *Spleen is too large to use posterior approach:* Use the anterior approach to ligate the splenic artery first

REFERENCES

1. Ikard R, Merendino KA: Accidental excision of the superior mesenteric artery, *Surg Clin North Am* 50:1075, 1970.
2. Moul JW et al: Celiac axis and superior mesenteric artery injury associated with left radical nephrectomy for locally advanced renal cell carcinoma, *J Urol* 141:1104-1108, 1991.
3. Marsh CL: Enhancing exposure of the left upper retroperitoneum, *Contemp Urol* 6(8):15-20, 1994.
4. Wise HA III: Anterior transabdominal approach for radical retroperitoneum lymphadenectomy. In Crawford ED, Borden TA, editors: *Genitourinary cancer surgery,* Philadelphia, 1982, Lea & Febiger, p 298.
5. Donohue JP: Testis tumors. In Libertino JA, editor: *International perspectives in urology,* Baltimore, 1983, Williams & Wilkins, pp 181-193.
6. Cummings K: Surgical management of renal cell carcinoma with extension into the vena cava. In Crawford ED, Borden TA, editors: *Genitourinary cancer surgery,* Philadelphia, 1982, Lea & Febiger, pp 70-79.
7. Pringle JH: Notes on the arrest of hepatic hemorrhage due to trauma, *Ann Surg* 48:541-549, 1908.
8. Edwards EA et al: The duodenum, pancreas, and spleen. In Edwards EA, Malone PD, MacArthur JD, editors: *Operative anatomy of the abdomen and pelvis,* ed 9, Philadelphia, 1975, Lea & Febiger, pp 37-44.
9. Montie JE: Inferior vena cava tumor thrombectomy. In Montie JE, Pontes JE, Bukowski RM, editors: *Clinical management of renal cell carcinoma,* Chicago, 1990, Mosby.
10. Blute ML, Zincke H: Surgical management of renal cell carcinoma with intracaval involvement, *AUA Update Series,* lesson 17, vol XIII, 1994.
11. Clayman RV, Gonzalez R, Fraley EE: Renal cell cancer invading the inferior vena cava: clinical review and anatomical approach, *J Urol* 123:157-162, 1980.
12. Marshall FF et al: Surgical management of renal cell carcinoma with intracaval neoplastic extension above the hepatic veins, *J Urol* 139:1166, 1988.

13 McAninich JW, Carroll PR: Renal trauma: kidney preservation through improved vascular control—a refined approach, *J Trauma* 22(4):285-289, 1982.

14 Skinner DG: Considerations for management of large retroperitoneal tumors: use of the modified thoracoabdominal approach, *J Urol* 117:605-609, 1977.

SUGGESTED READINGS

Bowers WF, Hewlett TH, Thomas GJ: *Manual of surgical technique*, Springfield, Ill, 1963, Charles C Thomas, pp 215-217.

Hoeltl W, Hruby W, Aharinejad S: Renal vein anatomy and its implications for retroperitoneal surgery, *J Urol* 143: 1108-1114, 1990.

Matsumata T et al: Modified technique of Pringle's maneuver in resection of the liver, *Surg Gynecol Obstet* 172:245-256, 1991.

Skinner DG: Technique of nephroureterectomy with regional lymph node dissection, *Urol Clin North Am* 5(1):253-255, 1978.

Zollinger RM Jr, Zollinger RM: Right hepatic lobectomy. In *Atlas of surgical operations*, ed 6, New York, 1989, Macmillan, pp 209-210.

THE FLANK INCISION AND EXPOSURE OF THE KIDNEY

2

Good flank exposure of the kidney can be achieved by many surgical approaches. In general, the kidney lies higher than expected from the radiologic studies, with the left kidney slightly higher than the right kidney. Except for lower pole renal biopsy, most operations require good exposure of the renal pelvis and the renal pedicle and thus call for either a supra–twelfth-rib incision or a twelfth-rib rib resection. In the following discussion of these two approaches, important anatomic considerations for all flank exposures are highlighted.

FIG. 2-1. The flexion of the operating table should be in line with the anterior superior iliac spine of the pelvis. This spine is a constant landmark that the surgeon can palpate in both thin and obese patients.

After the patient is positioned on the side, the kidney rest can be elevated and the operating table flexed. It is important to monitor the patient's vital signs because the vena cava can be compressed during this maneuver. We prefer that the patient is in a straight lateral position 90 degrees to the table as opposed to an angled position; the straight lateral position can be angled by simple rotation of the operating table from side to side. The surgeon should apply 5-inch–wide adhesive tape horizontally across at the level of the iliac spine and around the operating table to secure and maintain the patient in this flank position. The taping stabilizes patient position perpendicular to the operating table and thus allows the operating table to be rolled from side to side for improved exposure of the anterior or posterior kidney.

Although the anterior superior iliac spine is positioned at the flexion of the table, when the table is fully flexed, the final position of the body will cause the entire pelvis to be slightly below the apex of the flexion and the ribs to be slightly above, which creates tension in the area of the lower

Flank Position

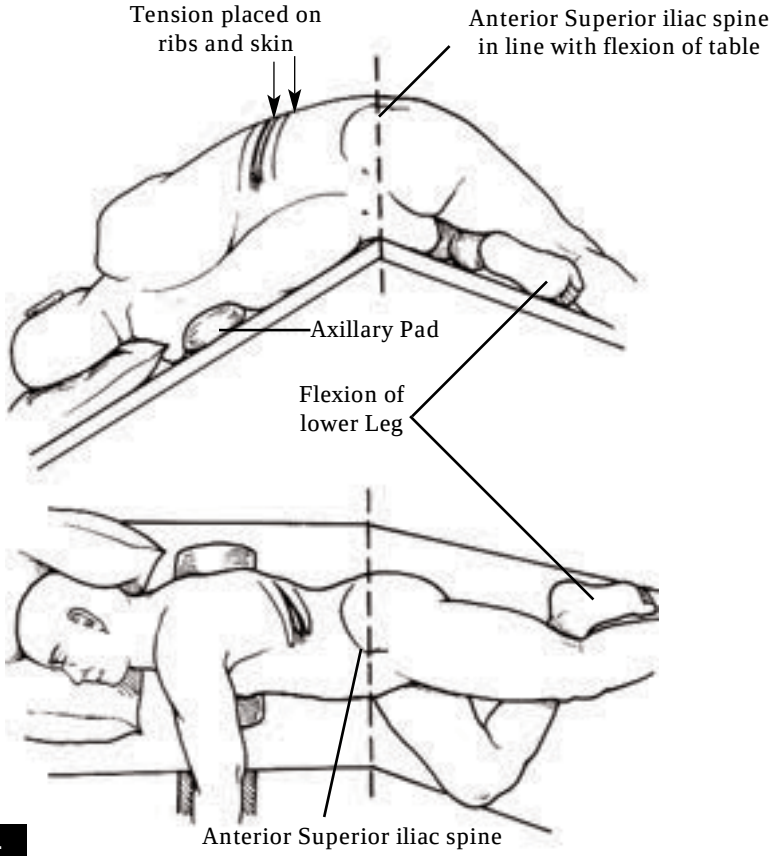

2-1

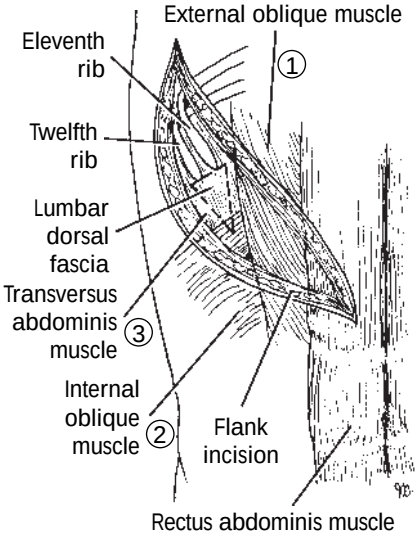

2-2

ribs and flank. The surgeon should palpate the region between the eleventh and twelfth ribs and between the ribs and the iliac spine when the operating table is adequately flexed to ensure that this tension has been maintained.

The lower leg is flexed to 90 degrees at the knee to prevent the body from rolling from side to side, but the upper leg is kept straight to maintain the tension of the incision site; pillows are placed between the legs as support.

An axillary pad is placed under the lower dependent arm to prevent any neural compression. The upper arm should be placed on an airplane rest for stabilization.

EXPOSURE

For any flank exposure of the kidney, the surgeon must release three components holding the ribs together:

1. Intercostal muscles
2. Diaphragmatic attachments to the ribs and retroperitoneum
3. Internal intercostal membrane holding the proximal ribs together

Supra–Twelfth-Rib Incision

FIG. 2-2. The surgeon makes the incision extending from the lateral border of the rectus abdominis muscle to beyond the posterior axillary line. This incision is essentially slightly superior to the twelfth rib.[1] Anterior and medial to the rib, the external oblique *(1)*, internal oblique *(2)*, and transversus abdominis *(3)* muscles are sequentially divided.

Although it is not always possible, the surgeon should attempt to preserve the intercostal nerve to prevent the "frog belly" protrusion of the abdomen after surgery. The intercostal nerve can be freed from the muscles and can be pushed medially and laterally to the incision during the operation.

Once the internal oblique muscle is divided, the dense lumbar dorsal fascia, which lies anterior and medial to the tips of the eleventh and twelfth ribs, can be identified.

FIG. 2-3. By opening this fascial landmark, the surgeon can enter the retroperitoneal space and mobilize the peritoneum anteriorly.

FIG. 2-4. The surgeon inserts the left index and middle fingers and bluntly spreads the fingers beneath the transversus abdominis muscle to establish a dissection plane between the anterior peritoneum and the muscle. The transversus abdominis muscle is then divided to the lateral margin of the rectus fascia.

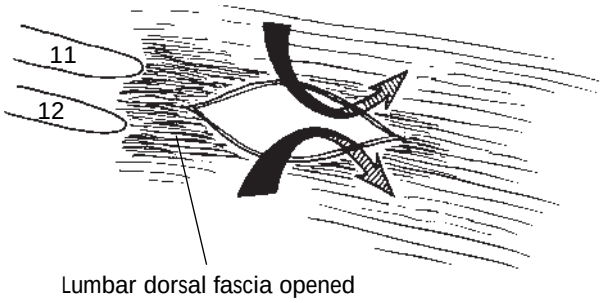

2-3

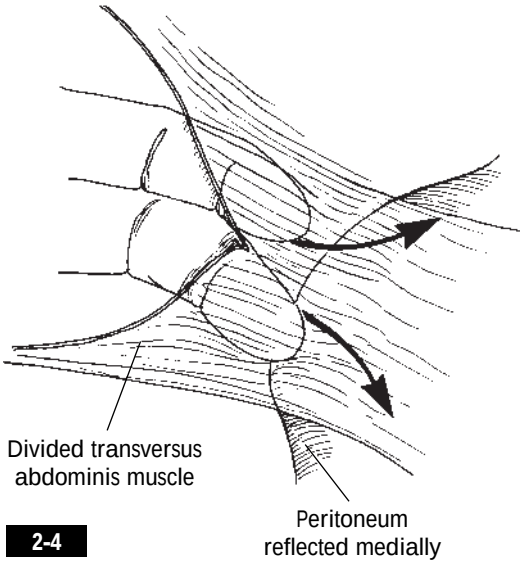

2-4

FIG. 2-5. The two large muscles, the latissimus dorsi and the serratus posterior, are partially divided to expose the posterior part of the ribs and the intercostal muscles. One common error is to fail to complete the posterior dissection despite an excellent anterior dissection.

FIGS. 2-6 AND 2-7. The surgeon uses a sponge stick bluntly and gently to sweep the posterior Gerota's fascia medially off the psoas and quadratus lumborum muscles (*1* in Fig. 2-6). The kidney and peritoneum are rolled medially by this maneuver, exposing the posterior surface of the kidney and its pedicle in Gerota's fascial compartment.

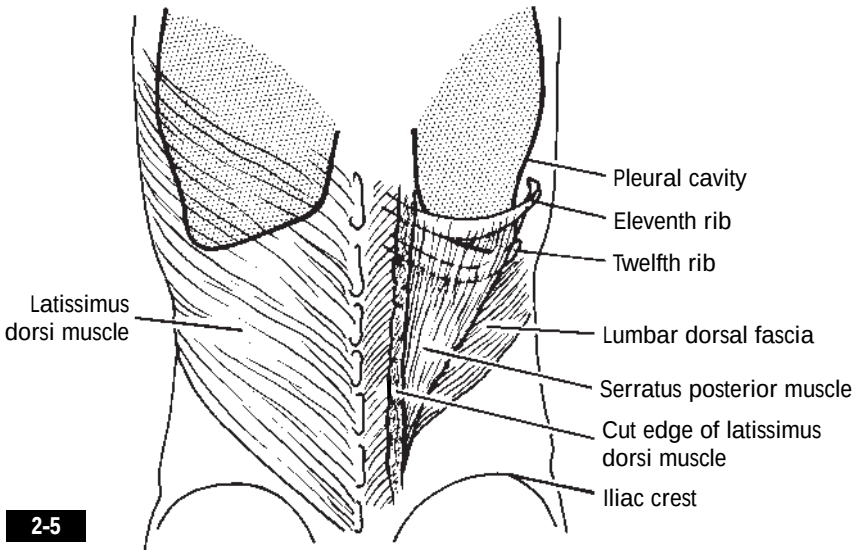

2-5

Entry into Retroperitoneum

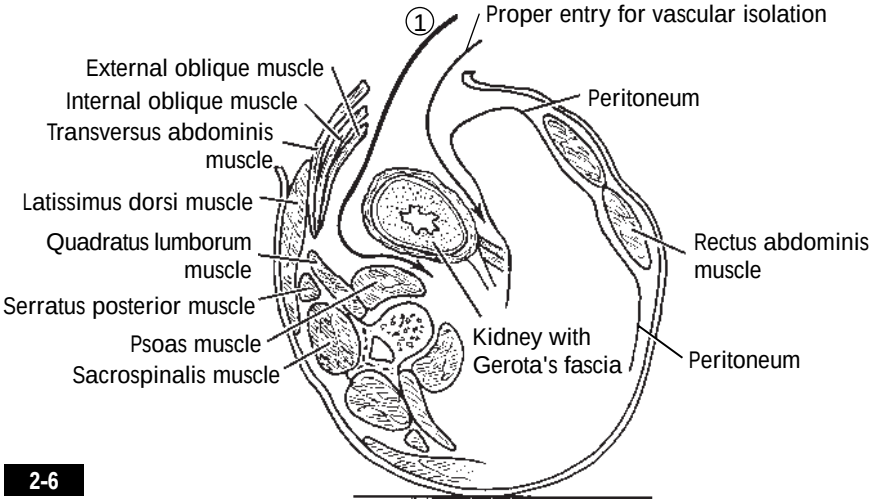

2-6

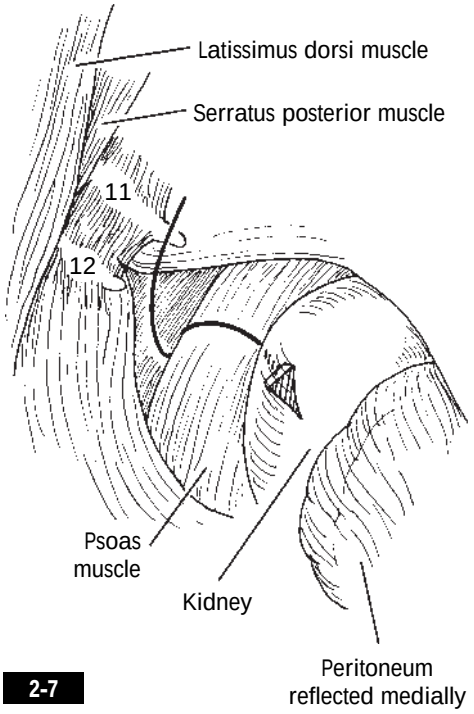

2-7

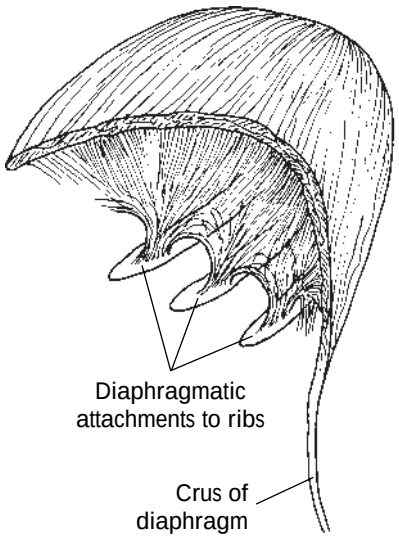

2-8

Diaphragmatic Attachments

FIGS. 2-8 AND 2-9. With outward traction of the free end of the twelfth rib, the surgeon uses the right index finger and gently pushes proximally against the inner aspect of the twelfth rib, thereby separating strands of the diaphragmatic muscles from the rib. This maneuver exposes the inner aspect of the rib completely and gives the surgeon a clear view of the diaphragmatic muscles' attachments to the rib and retroperitoneum. These diaphragmatic attachments are then divided.

Using the index finger, the surgeon must apply pressure against the rib rather than on diaphragmatic muscles or the adjacent pleura. This maneuver, in essence, separates the pleura from the rib.

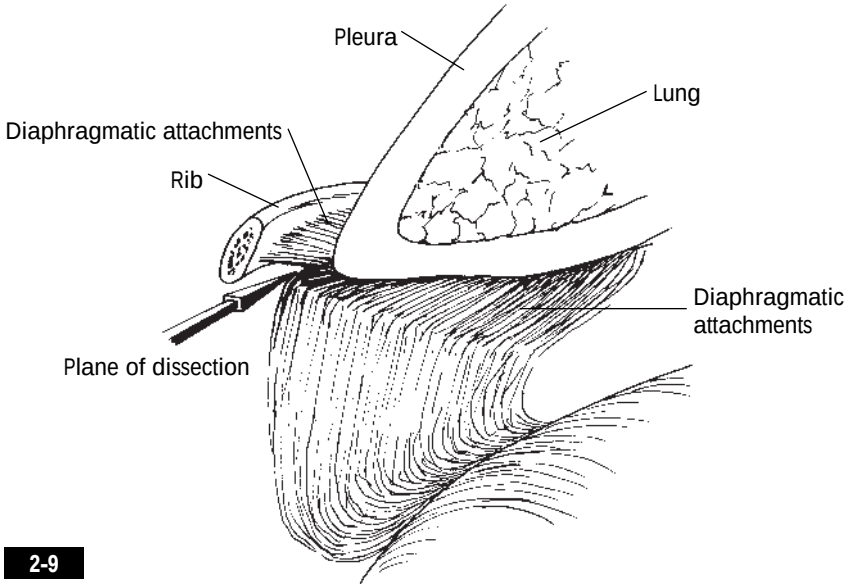

2-9

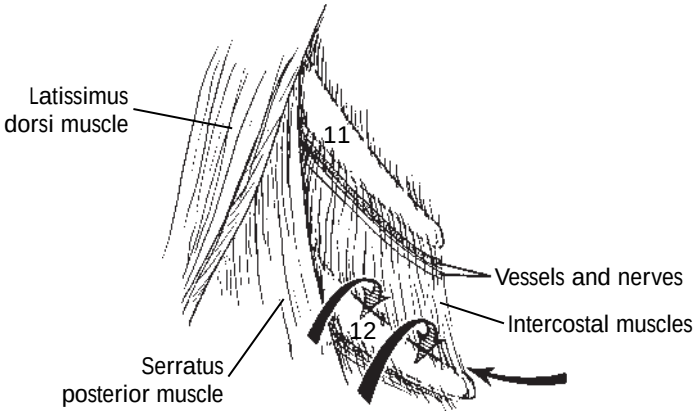

2-10

Intercostal Attachments

FIG. 2-10. With the same traction applied outward and downward on the distal tip of the twelfth rib, the intercostal muscles are now gently divided from the superior margin of the rib, beginning at the distal tip of the rib and extending to the proximal region, avoiding injury to the pleura.

The surgeon can divide the muscle directly above the rib without injury to the vasculature and nerves, which are located immediately below the rib.

FIG. 2-11. The surgeon's right index finger pushes gently against the most proximal inner aspect of the twelfth rib until the junction of the vertebral body is felt. The surgeon can now palpate the internal intercostal membrane and eleventh rib above. The intercostal membrane is a thin, dense band of tissue holding the two ribs together. Only this dense membrane is divided; the tissue deeper to this membrane is left intact. When dividing this membrane, the surgeon can feel the release of tension. The Finochetto retractor with two dry laparotomy pads can be placed on either side of the ribs and opened slowly for full exposure of the kidney.

This same exposure can be applied to the eleventh rib if necessary.

Twelfth-Rib Rib Resection

FIG. 2-12. Using periosteal elevators such as Doyen periosteal elevators, the surgeon first cleans and frees the rib from its intercostal attachments with periosteal elevators in opposing directions as illustrated. The Doyen elevators curl around the bony rib and essentially release the periosteum and its diaphragmatic attachments.

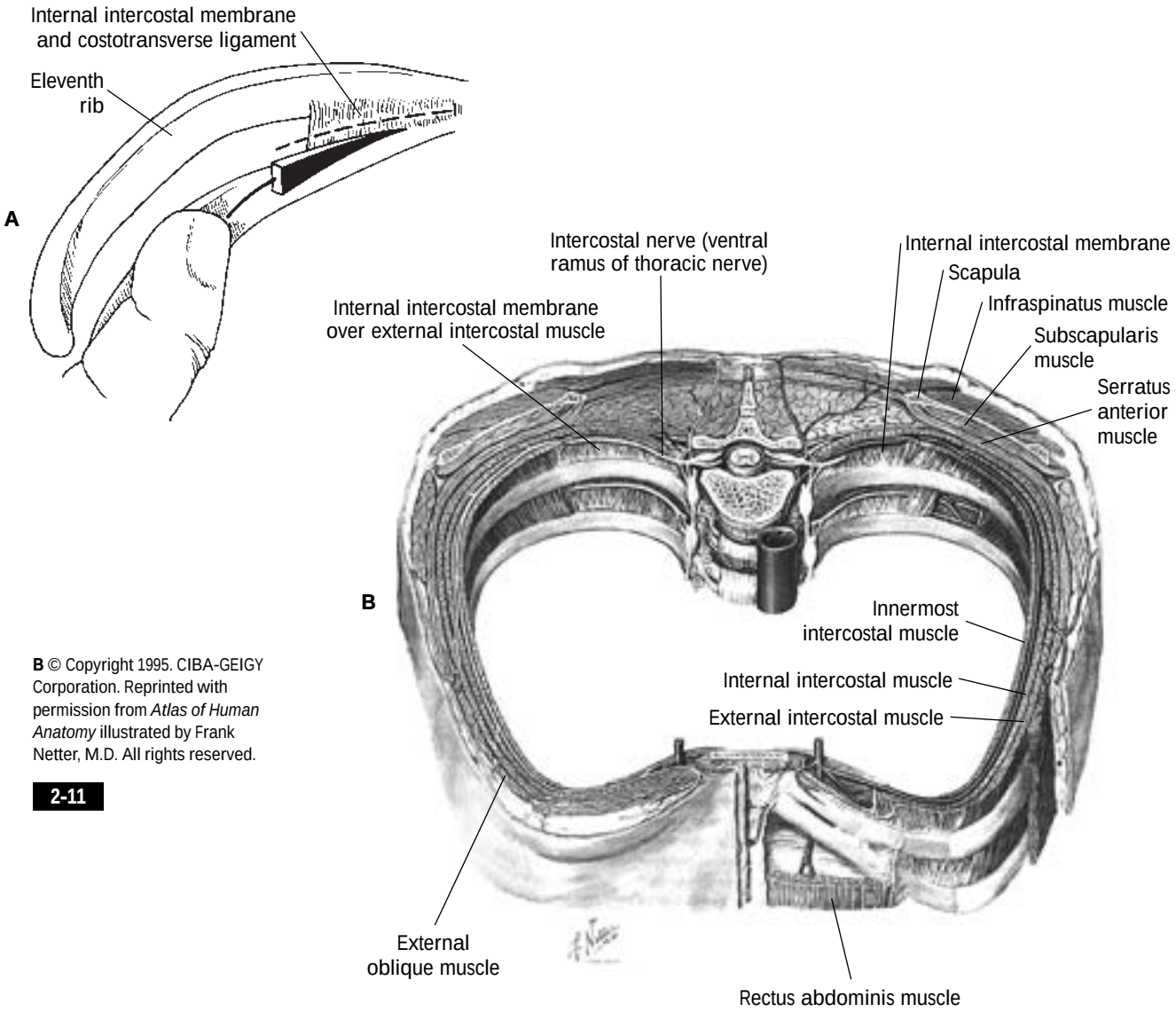

2-11

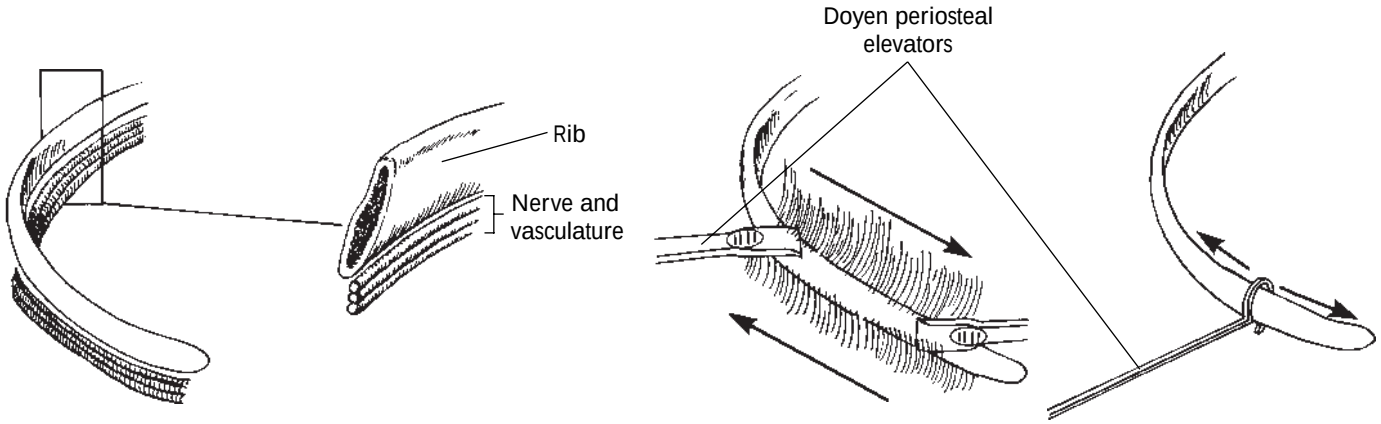

2-12

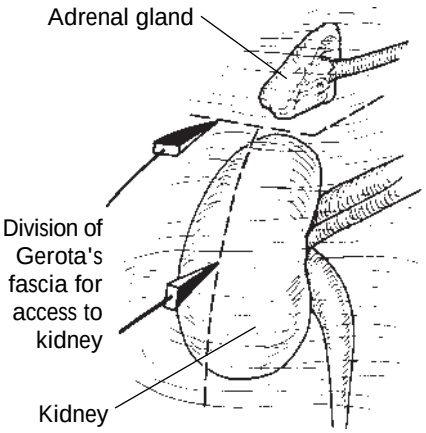

2-13

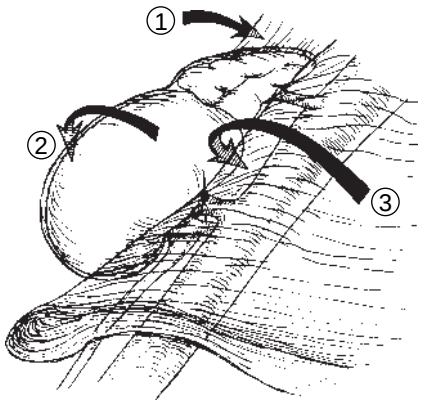

2-14

Since the rib is resected at its proximal end with rongeurs, there is no need to divide the intercostal membrane as is performed in the supra–twelfth-rib incision.

After the rib is resected, the surgeon uses blunt dissection to reestablish the plane between the quadratus lumborum and psoas muscles on one side and the posterior Gerota's fascia and kidney on the other side as described previously.

SIMPLE NEPHRECTOMY AND RECONSTRUCTIVE RENAL SURGERY

FIG. 2-13. The surgeon divides the most lateral posterior aspect of the Gerota's fascia to expose the lateral surface of the kidney.

Dissection between the Gerota's fascia and the kidney medially on both sides provides excellent exposure of the kidney, renal pelvis, and renal pedicle.

RADICAL NEPHRECTOMY IN FLANK POSITION FOR SMALL RENAL CANCERS IN LOWER HALF OF KIDNEY

FIG. 2-14. The dissection preserves the integrity of the Gerota's fascia and includes the adrenal gland *(1)*.

The surgeon separates the posterior Gerota's fascia from the psoas muscle *(2)*.

The surgeon then identifies the upper ureter and places a vessel loop for traction. Often the gonadal vein is next to the ureter and can be divided on the right side.

The most difficult maneuver of the operation is to separate the posterior peritoneum from the anterior Gerota's fascia *(3)*. The assistant holds the peritoneum up while the surgeon uses the fingers to gently tease a dissection plane between the two. The reflection of the posterior peritoneum can often be seen and used as a guide. As the surgeon gently uses the fingers to separate the two layers, first the renal vein and then the renal pelvis can be identified medially.

With the patient in the full flank position for right-side dissection to expose the kidney, the surgeon will not see the duodenum as clearly as when the patient is in the supine position (Kocher maneuver, see p. 12). As the separation of the peritoneum and the Gerota's fascia is completed, the duodenum will be just anterior to the vena cava.

FIG. 2-15. From the anterior aspect of the kidney, the surgeon can usually identify all venous structures, renal vein, adrenal vein, gonadal vein, and lumbar vein.

At times it may be necessary to free the entire posterior Gerota's fascia from the posterior muscles to isolate the renal artery located slightly inferior to and behind the renal vein.

The renal artery is always ligated and/or divided *before* the renal vein is. Two ties (0 silk) are placed proximally and one distally.

Superiorly, the surgeon follows the Gerota's fascia and proceeds beyond the adrenal gland. While cautiously using gentle downward traction with the left index and middle fingers on either side of the adrenal gland, the surgeon can clip and divide the attachments superiorly with the right hand. If the adrenal vein has not been identified yet, it will usually lie on the medial aspect of the adrenal gland (for right-sided nephrectomy).

RENAL AND ADRENAL VASCULATURE

On the *right side*, the adrenal, renal, and gonadal veins branch directly from the vena cava, whereas on the *left side*, the adrenal, accessory lumbar, and gonadal vessels join the renal vein.

On the *right side*, the adrenal

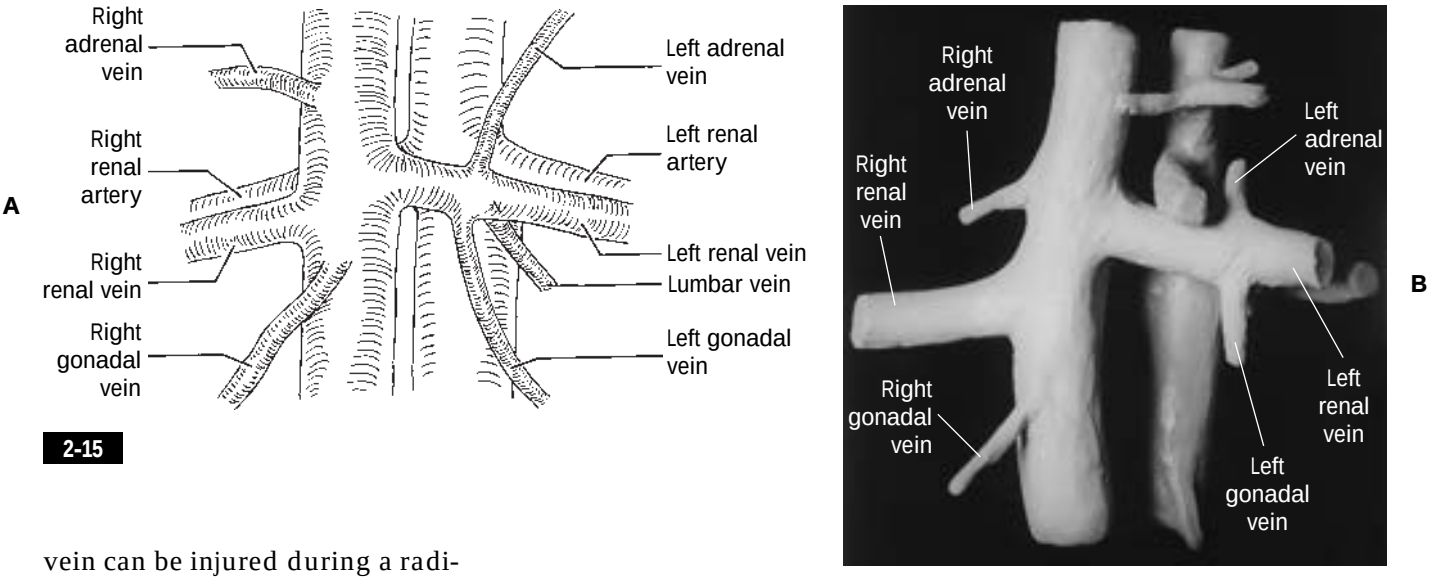

2-15

vein can be injured during a radical nephrectomy for large upper pole cancer as previously discussed (see p. 12).

FIG. 2-16. On the *left side*, the location and vasculature of the adrenal gland is more accessible and easier to expose. The most common venous injury involves the accessory lumbar vein draining into the renal vein from a posterior position. Because this vein is located directly behind the renal vein, the surgeon may miss it before dividing the renal pedicle vein (see p. 20).

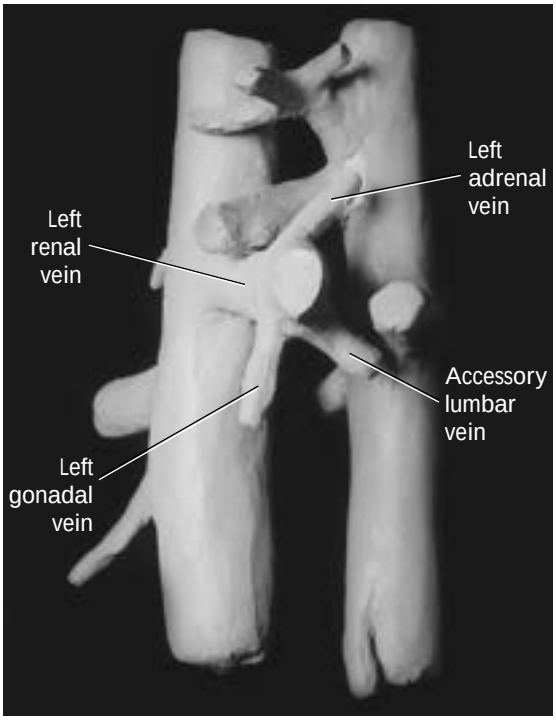

2-16

PLEUROTOMY

Inadvertent pleurotomy is common with flank incisions. The simplest method to correct this problem is to insert a chest tube (see p. 23).

For a small opening, a red rubber catheter can be placed within the pleural cavity, and the opening can be closed with a stitch (2-0 chromic).

After the surgery is completed and the wound is reapproximated around this catheter, the proximal end of the red rubber catheter is placed to an underwater seal such as a medicine cup filled with water.

The anesthesiologist can expand the lung by inflation and can push the air within the cavity out through the red rubber catheter.

The surgeon gradually moves the catheter out while watching for air bubbles to be expelled.

When no further air bubbles come out through the catheter, the surgeon pulls the catheter out.

In most cases, the postoperative chest radiograph shows a small residual defect of 10% pneumothorax. This small defect does not require treatment but needs only monitoring with serial radiographs.

KEY POINTS

- The patient is positioned with the anterior iliac crest in line with the flexion of the table.
- The retroperitoneum space is established first.
- The intercostal muscles, diaphragmatic attachments, and intercostal membrane (for supra–twelfth-rib incision) are released.
- Note that above the twelfth rib the pleura can be easily swept off, whereas the pleura is more adherent to the ribs above the eleventh rib.
- The Gerota's fascia is divided to expose the kidney and renal pedicle for reconstructive renal surgery.
- The posterior peritoneum and anterior Gerota's fascia are separated to expose the renal pedicle for a cancer operation.
- The right adrenal vein is carefully dissected out for right-sided tumors. For left-sided tumors, the surgeon must watch for the lumbar vein draining into the renal vein from a posterior position.

POTENTIAL PROBLEMS

- *Pleurotomy:* Perform postoperative closure with the tip of a red rubber catheter in the pleural cavity and the open end to an underwater seal to blow out the air in the pleural cavity *or* place chest tube
- *Intercostal vasculature and nerve injury:* Achieve hemostasis by electrocoagulation → perform stitch ligation of vasculature not including the nerve
- *Inadvertent opening of the posterior peritoneum:* Perform immediate closure because this defect may be forgotten subsequently
- *Torn adrenal vein on right side:* Apply hand compression on the vena cava → apply curved Satinsky vascular clamp on a cuff of the vena cava before repairs if necessary (see p. 59)
- *Excessive manipulation of left-sided dissection leading to splenic injury with hemorrhage suspected based on sudden drop in blood pressure:* Perform peritoneotomy → explore spleen to see if preservation is possible → if not, perform splenectomy (see p. 28)

REFERENCE

1 Turner-Warwick RT: The supracostal approach to the renal area, *Br J Urol* 37:671, 1965.

THE METHOD OF ANATROPHIC NEPHROLITHOTOMY USED IN CALCULUS REMOVAL AND PARTIAL NEPHRECTOMY

3

With the widely used extracorporal lithotripsy, percutaneous nephrolithotomy, and endourologic methods for kidney stone surgery, the clinical use of the anatrophic nephrolithotomy procedure has diminished. However, because this operation clearly showed the advantages of using hypothermia in extensive kidney surgery and demonstrated maximal parenchymal preservation, it can still be useful. Anatrophic nephrolithotomy not only can be used for full staghorn calculus surgery but also can be adapted for complex kidney reconstructions and partial amputations in a solitary kidney.

If the surgeon chooses to induce kidney hypothermia for the operative procedure, intravenous infusion of mannitol (12.5 g) preoperatively as well as immediately before clamping the renal vasculature will allow the maximal ischemic time with the least renal damage.[1,2]

OPERATIVE PROCEDURE

Slush Preparation

FIG. 3-1. Slush should be used immediately after renal vasculature occlusion and is prepared easily by the following method[3,4]:

1. Dry ice is placed in a large basin.
2. An empty stainless steel bowl is placed in the middle of the large basin such that it is surrounded up to the rim with the dry ice **(A).**

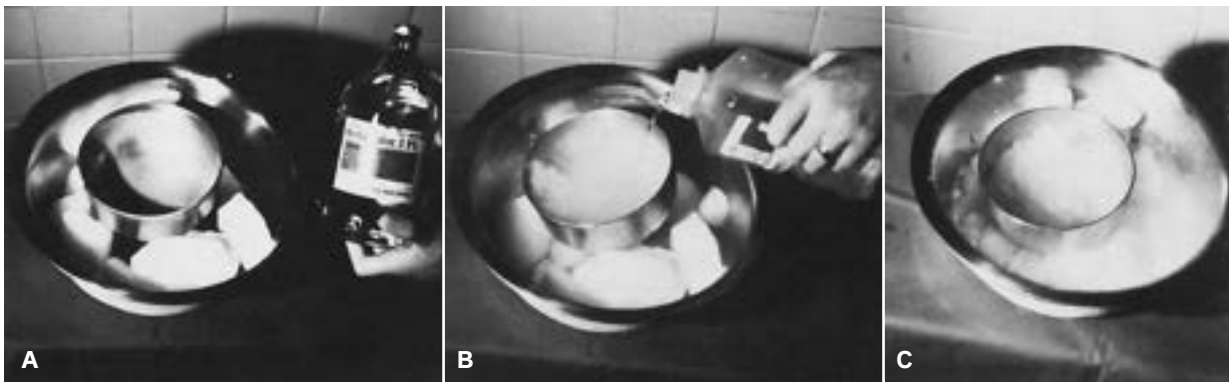

From Cromie WJ, Streem S: *Urology* 19(1):85, 1982.

3-1

3 When the inside of the stainless steel bowl becomes "frosty," normal saline solution is slowly poured in while the solution is stirred **(B).**
4 Within 5 minutes, slush will form and will be ready for use **(C).**

Coagulum Preparation

The use of the most popular coagulum for trapping kidney stones was curtailed by the report of the associated development of a pulmonary embolus. The thrombin was identified as the culprit for the cascade of the fatal event.[5]

FIG. 3-2. A simpler method of forming a coagulum cast without thrombin was described by Kalash, Campbell, and Young.[6] Although this formula is rarely used, we have found it to be the most consistent and easiest to use:

1 Cryoprecipitate (250 mg/U) (12 U 100 ml) is ordered the day before surgery.
2 The cryoprecipitate first is allowed to thaw in a 37° C bath and then is left at room temperature for 30 to 40 minutes before use.
3 Using a 10% solution of calcium chloride (10 ml ampule, Elkin), the surgeon mixes a volume ratio of 1:20 of calcium chloride to cryoprecipitate (e.g., 1 ml of calcium chloride solution to 20 ml of cryoprecipitate). One to two drops of methylene blue can be added to distinguish this mixture from the stones.[2]
4 Either by estimating or by directly applying a No. 18 angiocatheter into the renal pelvis, the surgeon withdraws the volume of urine within the pelvis.
5 Correspondingly, the surgeon draws the same or greater volume of the cryoprecipitate mixture and injects it into the renal pelvis after the proximal ureter is temporarily obstructed with a vessel loop. The injection should fill the renal pelvis such that the mixture can flow into the multiple calyces. However, the surgeon should not overdistend the collecting system because this could lead to venous extravasation.[5]
6 The surgeon injects 5 ml of the mixture into a medicine cup to observe for coagulation to take place. It requires 15 to 20 minutes for the coagulum to form.
7 The surgeon then opens the renal pelvis and calyx and removes the solidified coagulum with the stone trapped within it.

Arterial and Venous Isolation

FIG. 3-3. To find the true avascular plane between the anterior and posterior renal arteries, Smith and Boyce[7] first described isolating the renal artery from the renal vein and then occluding the anterior or posterior branch of the artery with a bulldog vascular clamp. An obvious avascular line can be defined if methylene blue is injected.

However, because this method is cumbersome and also has led to irreversible arterial injury, a simpler method described by Redman, Bissada, and Harper[8] is more commonly used.

With this simpler method, the surgeon estimates the location of the avascular plane, which is slightly posterior to the midportion of the kidney. The surgeon occludes the renal artery and vein together as one unit instead of separating the artery, vein, and branches.

We prefer using vessel loops wrapped around twice and tied (en bloc ligation) rather than using bulldog vascular clamps. This vessel loop method lessens the vascular trauma and also permits the surgeon to loosen the loops intermittently to allow flow-through during the operation.

Coagulum Cast of Renal Pelvis and Ureter with Stones Entrapped

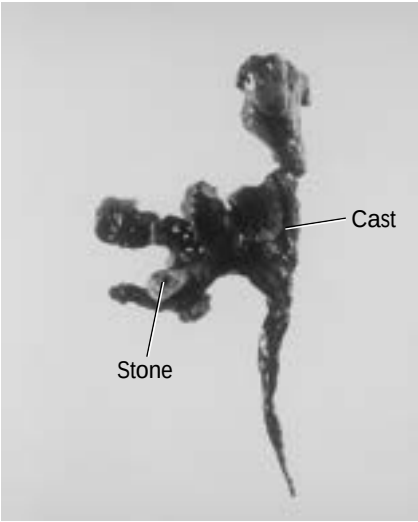

3-2

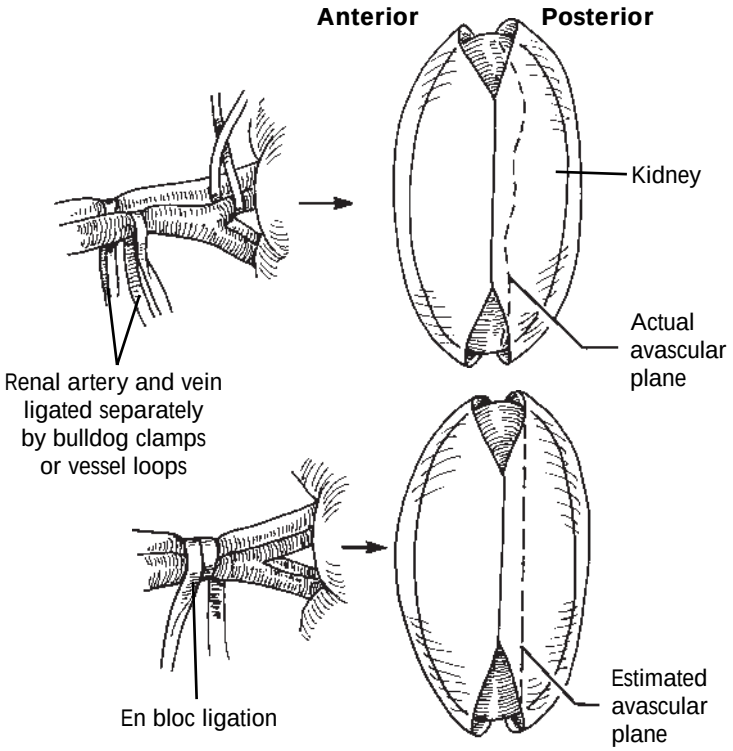

3-3

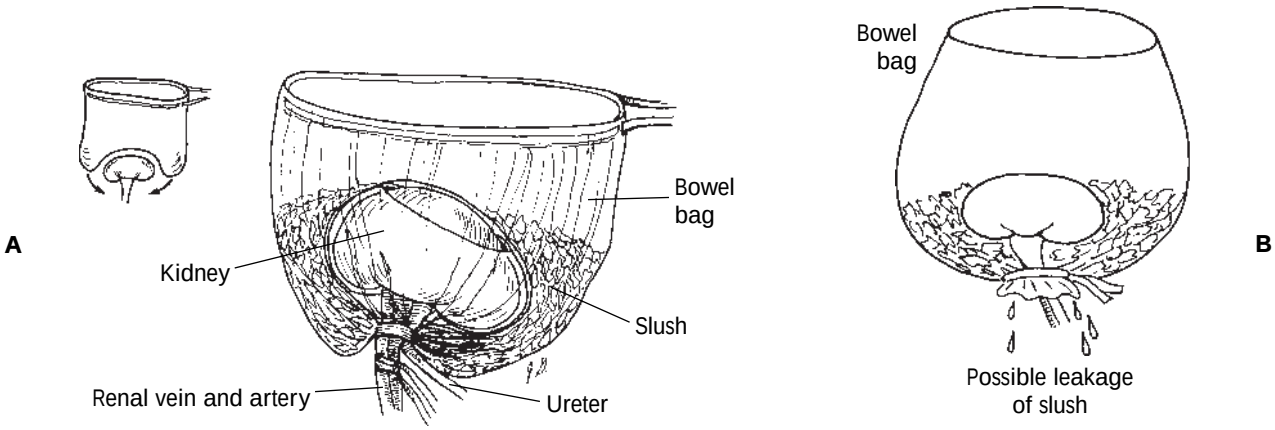

3-4

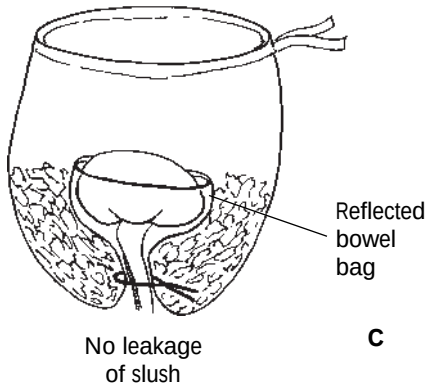

Bowel Bag Placement

FIG. 3-4. After the vessel loops have been placed loosely around the entire vascular pedicle, a bowel bag is placed over the kidney. Wrapping the kidney down to its pedicle, the surgeon ties umbilical tape around the base **(A).**

A small slit is made so the kidney can be extruded. The object of this maneuver is to prevent excessive leakage of slush into the retroperitoneum. Fluid in direct contact with the body may lead to excessive body hypothermia **(B).**

Once the renal vasculature has been occluded, slush is poured into the bowel bag **(C).**

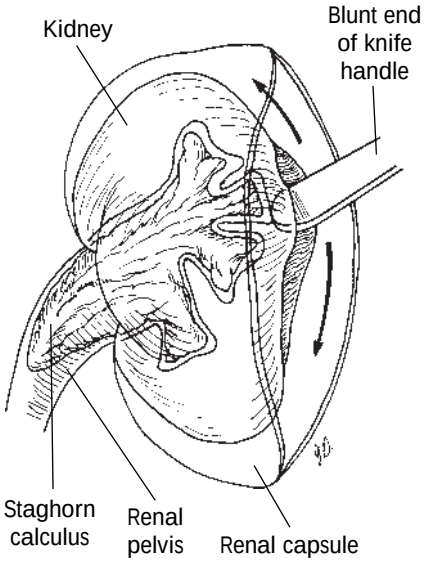

3-5

FIG. 3-5. Using the simpler method of this operation, the surgeon first divides and preserves as much of the renal capsule as possible and then bivalves the kidney with a blunt knife handle along the estimated avascular line.

If coagulum is used, the precipitate is injected before opening the parenchyma.

After the surgeon has removed the bulk of the stones and has irrigated and flushed out each calyx, the most difficult part of the surgery is undertaken: the removal of residual stones.

The recurrence rate of infectious stones is proportionally related to the number of stones remaining in the kidney.

FIG. 3-6. With a needle placed on either pole, the surgeon can define remaining stones in the anterior as well as the posterior leaf of the bivalved kidney with the use of jaw or dental film.[9] We prefer this method over the use of nephroscopy or sonography.

Jaw or dental film (Kodak catalog number 1566389) or 5 × 12 inch panoramic film is placed between intensifying screens (Lanex Regular; Kodak) and then placed within a pliable Gendex cassette. The cassette is covered with adhesive sterilized plastic or placed within a sterile plastic bag. The surgeon places the cassette between the bivalved kidney and obtains a radiograph of the stones in the anterior leaf. A second film is placed posterior to the whole kidney to define stones in both leaves of the kidney. By counting the stones in the first film and subtracting the number from the total number of stones detected in the second film, the surgeon can define the stones in the posterior leaf.

FIG. 3-7. A nephrostomy tube and a small-caliber irrigating stent are placed after the stones are removed *(1* and *2)*.

Obvious, large defects of the collecting system and divided vasculature are closed with an absorbable stitch (4-0 chromic) *(3)*, but it is not necessary to reapproximate all divided vessels or collecting systems.

The importance of reapproximating the renal capsule to create a tamponade cannot be overemphasized.

When the kidney is rewarmed and the vessel loop around the vasculature is released *(4)*, there is usually minimal bleeding.

PARTIAL NEPHRECTOMY FOR RENAL CANCER IN SOLITARY KIDNEY

If partial nephrectomy is indicated, whether for cancer in a solitary kidney or for other reasons, the objective is to remove the diseased segment of the kidney and to preserve as much residual parenchyma as possible.

A preoperative selective arteriogram is useful.

In rare cases in which a branch of the renal artery corresponds to

Portable Radiograph for Residual Stones

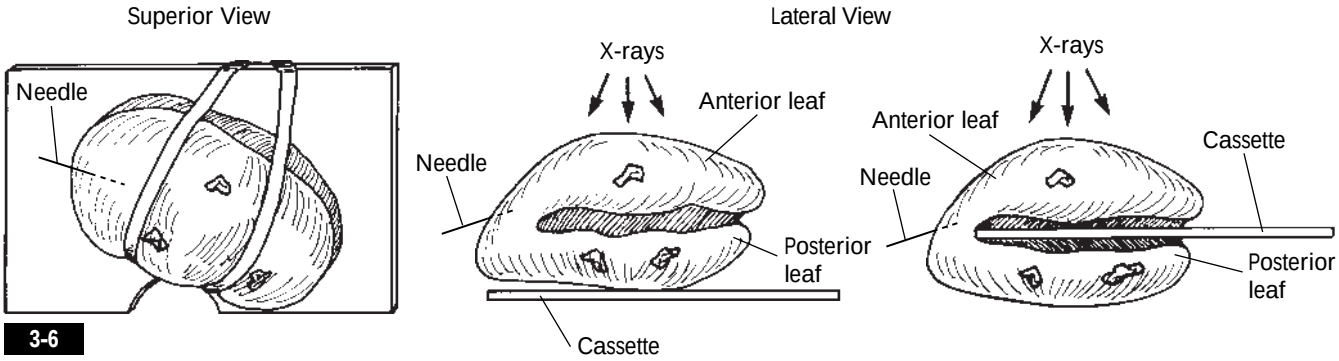

3-6

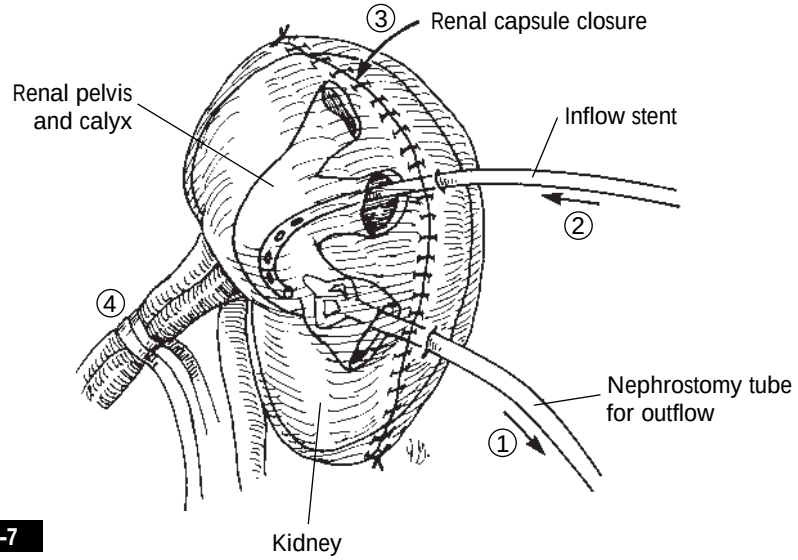

3-7

Partial Nephrectomy

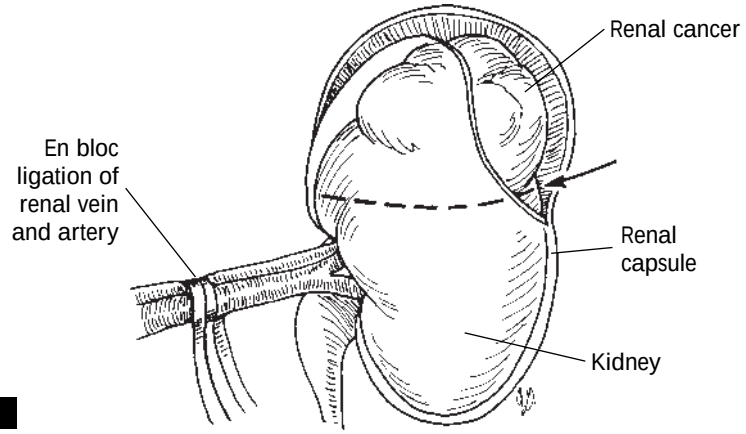

3-8

the segment to be resected, the surgeon can simply ligate the branch and perform partial nephrectomy. In the majority of cases, however, this is not so. En bloc ligation of the renal artery and vein should be performed and then hypothermia should be induced.

FIG. 3-8. The capsule is opened, and the amputation of the kidney segment for a partial nephrectomy can be performed using the blunt end of a knife handle to divide the parenchyma.

The calyceal systems should be closed with a running stitch (2-0 or 4-0 chromic), and large-caliber vessels should be closed with figure-of-eight stitches.

The assistant should now loosen the vessel loop around the renal pedicle while the surgeon searches for obvious venous and arterial bleeding sites that require occlusion.

The argon beam coagulator (Birtcher / Solos, Irvine, Calif.) can provide excellent hemostasis of the raw surfaces of the amputated kidney.[9] The coagulator can also be used to obtain hemostasis of the spleen and liver.

FIG. 3-9. Mild hemorrhage can be tamponaded by pieces of fat or Surgicel with Avitene compressed within the reconstructed renal capsule.

The use of fibrin glue (Hemaedics, Inc., Malibu, Calif.) is also helpful.

FIG. 3-10. If there is still bleeding after the kidney is rewarmed and the temporary vascular ligation is released, the Teflon felt pledget sandwiching technique is another alternative for achieving hemostasis.

Using two Teflon felt pledgets (1 × 2 cm), the surgeon passes a mattress stitch (0 chromic) through the pledgets with the kidney in between as a "sandwich." The Teflon pledgets prevent the stitch from tearing through because pressure is applied to compress the kidney. The same technique is used to repair lacerated spleens and livers.

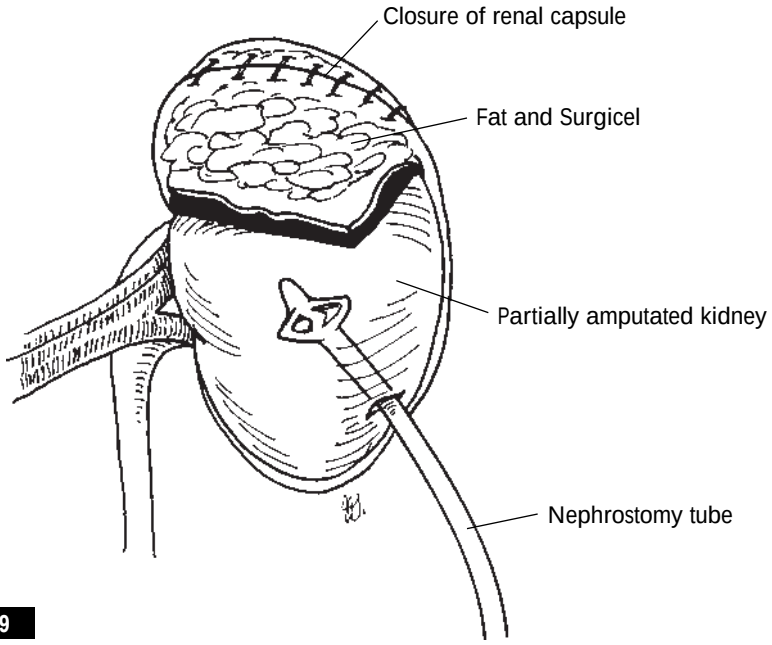

3-9

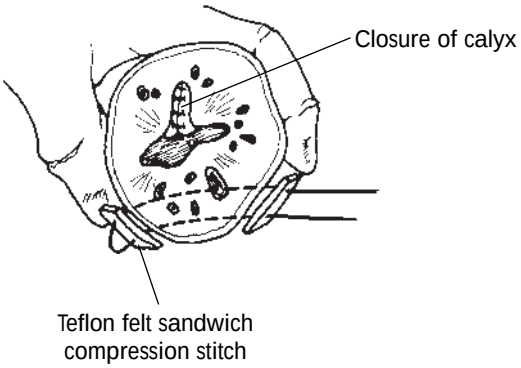

3-10

KEY POINTS

ANATROPHIC NEPHROLITHOTOMY

- Mannitol (12.5 g) is administered intravenously.
- A vessel loop is twice wrapped around the renal artery and vein together. Alternatively, a single loop with a Rummel vascular tourniquet can be applied to the renal vessels.
- A bowel bag is placed around the kidney.
- Slush is poured into the bowel bag to induce hypothermia.
- The divided renal capsule is preserved for closure.
- The need for the use of coagulum should be considered.
- The renal stone is removed and the calyceal branches are irrigated.
- Cassette film radiographs of the anterior and posterior leaves of the bivalved kidney are obtained.
- A nephrostomy tube (Malecot 18 Fr) and stent (6 or 8 Fr) are placed for possible irrigation.
- Large open defects of the collecting system are closed and large vessels are reapproximated with an absorbable stitch.
- Capsular reapproximation is completed.
- The kidney is rewarmed and the vessel loops around the renal pedicle are released.

PARTIAL NEPHRECTOMY

- Vascular control is obtained with a vessel loop double-looped around the renal artery and vein together.
- Hypothermia is induced with the kidney in a bowel bag.
- Capsular division and kidney amputation are performed.
- A nephrostomy tube is placed.
- Open defects of the collecting system are reapproximated.
- Stitch ligation of large blood vessels is performed. (*Partial* loosening of the vascular occlusion will reveal bleeding sites.)
- The argon beam coagulator is used to obtain hemostasis of raw surfaces following amputation.
- A tamponade effect of capsular closure is achieved with Surgicel or fat compressed within the renal capsule or with fibrin glue (Hemaedics, Inc.,) applied to the wound.
- The Teflon felt sandwich technique can be used to control bleeding.

POTENTIAL PROBLEMS

ANATROPHIC NEPHROLITHOTOMY

- *Inability to remove small residual stones after radiographic location:* Perform nephrostomy → leave stent near the area of the stone to serve as the inflow port for later irrigation
- *Excessive bleeding after rewarming of kidney and releasing vessel loop around renal pedicle:* Use Teflon pledget sandwich technique to compress the bleeding site

REFERENCES

1 Wickham JEA, Coe N, Ward JP: One hundred cases of nephrolithotomy under hypothermia, *J Urol* 112:702, 1974.

2 Finlayson B: Anatrophic nephrolithotomy [letter to the editor], *J Urol* 122:428, 1979.

3 Cromie WJ, Streem S: Rapid and simple slush preparation for hypothermic renal surgery, *Urol/Urotech,* 19:1, 1982.

4 Stanisic TH, Horan P, Silvert MA: Normal saline slush preparation for renal surgery, *J Urol* 122:287, 1979.

5 Pence JR et al: Pulmonary emboli associated with coagulum pyelolithotomy, *J Urol* 127:572, 1982.

6 Kalash SS, Campbell EW, Young JD: Further simplification of cryoprecipitate coagulum pyelolithotomy without thrombin, *Urology* 22(5):483, 1983.

7 Smith MJV, Boyce WH: Anatrophic nephrotomy and plastic calyrraphy, *J Urol* 99:521, 1968.

8 Redman JF, Bissada NK, Harper DL: Anatrophic nephrolithotomy: experience with a simplification of the Smith and Boyce technique, *J Urol* 122:595, 1979.

9 McHold DS, Yu GW: Intrarenal radiography for localization of residual struvite stones, *Cont Urol* 7:2 58, 1995.

SUGGESTED READINGS

Assimos DG et al: A comparison of anatrophic nephrolithotomy and percutaneous nephrolithotomy with and without extracorporeal shock-wave lithotripsy for management of patients with staghorn calculi, *J Urol* 145:710, 1991.

Boyce WH: The localization of intrarenal calculi during surgery, *J Urol* 118 (part 2):152, 1977.

Brodel M: The intrinsic blood vessels of the kidney and their significance in nephrotomy, *Johns Hopkins Hosp Bull* 118:10, 1901.

Kalash SS, Campbell EW, Young JD: Sources of fibrinogen for coagulum pyelolithotomy without thrombin, *J Urol* 12:486, 1983.

Kalash SS, Young JD Jr, Harne G: Modification of cryoprecipitate coagulum pyelolithotomy technique, *J Urol* 19:467, 1981.

Roth RA, Finlayson B: Stones: clinical management of urolithiasis. In Roth RA, Finlayson B, editors: *International perspectives in urology,* vol 6, Baltimore, 1983, Williams & Wilkins, pp 358-360.

Repair of Ureteral Pelvic Junction Obstruction

4

Although many operations to correct ureteral pelvic junction obstructions are viable, we have found dismembered pyeloplasty to be the simplest, most versatile, and most reliable procedure for a successful outcome. Both a voiding cystourethrogram to rule out reflux and a retrograde pyelogram immediately before the procedure are helpful if the lower ureter has not been studied.

ISOLATION OF RENAL PELVIS AND URETER

The surgeon uses a flank approach to expose the retroperitoneum and kidney (see pp. 31-33). The Gerota's fascia is divided, and the renal pedicle, renal pelvis, and ureters are identified and isolated.

The surgeon will need to dissect free 4 to 5 cm of the proximal ureter with its adventitia intact.

Although the radiologic studies may show a well-dilated renal pelvis, the surgeon will sometimes find the actual renal pelvis hidden within the renal cortex.

FIG. 4-1. With some contralateral traction applied to the ureter, the surgeon uses the forceps to gently push umbilical tape between the renal pelvis and the cortex and to establish a plane of dissection. With a vein retractor placed on the cortex, the surgeon can continue this gentle blunt dissection until the dilated renal pelvis is fully identified on both sides.

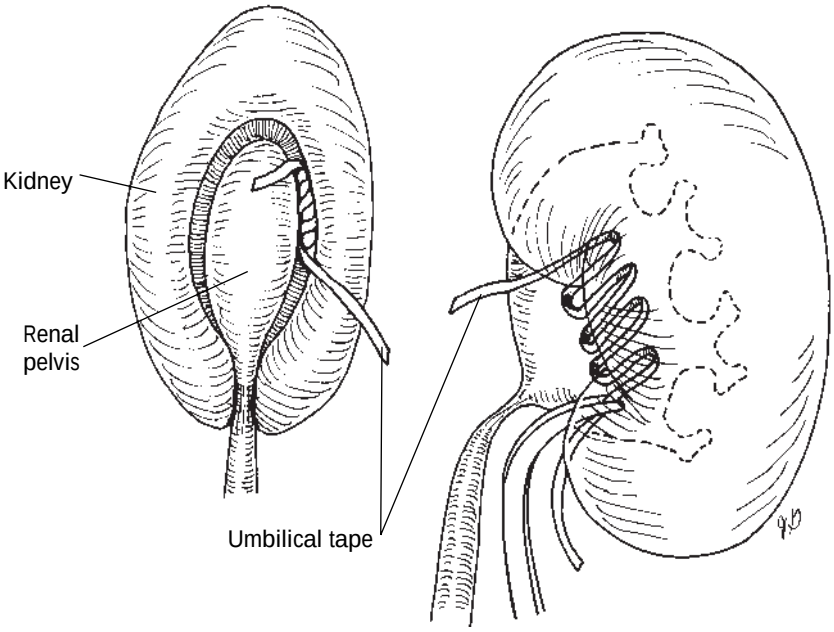

4-1

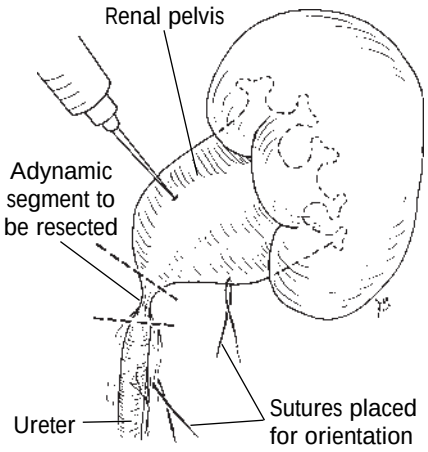

4-2

RESECTION OF ADYNAMIC URETERAL SEGMENT

FIG. 4-2. By injecting saline solution into the renal pelvis to dilate it, the surgeon can locate the adynamic segment and plan the resection.

Marking stitches are placed on the renal pelvis side as well as the ureteral side before resection of the adynamic segment is performed. These marking stitches provide the correct orientation for the ureteral spatulation and the planned anastomosis of the pelvis and ureter.

RESECTION OF ADYNAMIC SEGMENT AND DISTAL URETERAL SPATULATION

Although the actual adynamic segment is usually 1 cm in length, it is important to remove it completely, even though spatulation of the ureter and pelvis reduces the effect of any residual muscle. The adynamic segment is resected, and ureteral spatulation is performed immediately while proper ureteral orientation is maintained.

A 5 or 6 Fr ureteral stent is passed down the spatulated ureter to prevent ureteral twisting.

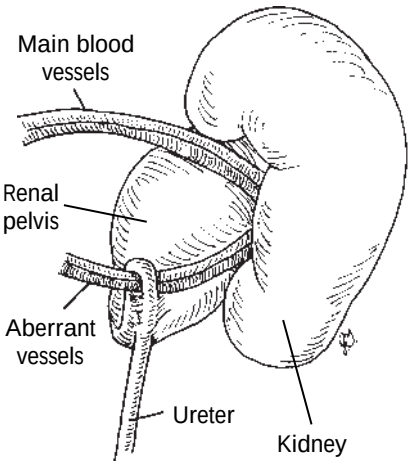

4-3

ABERRANT CROSSING VESSELS

FIGS. 4-3 AND 4-4. Because aberrant crossing vessels are associated with an intrinsic abnormality of the ureter, correcting the crossing vessels alone will not resolve the problem.

We prefer to divide the renal pelvis slightly above the ureteral pelvic junction, resect the adynamic segment, and then transpose the renal pelvis anterior to the crossing vessels rather than to divide these aberrant vessels.

If the surgeon chooses to divide the aberrant vessels, a compression test of the crossing vessels can be performed before the procedure is undertaken to see if a portion of the renal parenchyma becomes dark with ischemia. If ischemia is noted, division and transposition of the renal pelvis should be performed rather than division of the vessels.

RESECTION OF A LARGE, DISEASED REDUNDANT RENAL PELVIS

Although not always seen in children, the adult patient with longstanding renal disease usually has a large adynamic redundant renal pelvis that may require resection.

FIG. 4-5. After the renal pelvis is opened, the surgeon should wait until the renal pelvis has contracted to its stable state. If the redundancy remains large, then resection of the renal pelvis will be necessary.

The surgeon should first spatulate the renal pelvis *(1)* and estimate the line of resection on both sides *(2)*.

In diseased, dilated renal pelvises, the calyces are also stretched out. The surgeon should avoid cutting stretched calyces and should retain a good margin of resection for the anastomosis.

Transposition of Renal Pelvis and Ureter Anterior to Vessels

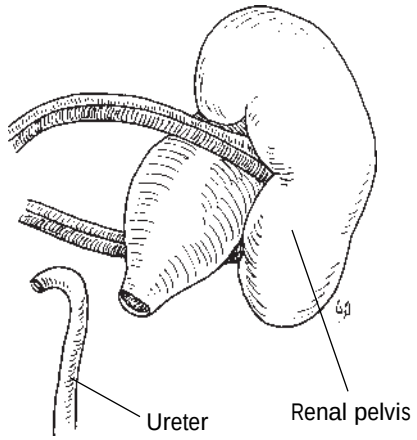

4-4

Resection of Redundant Renal Pelvis After Spatulation

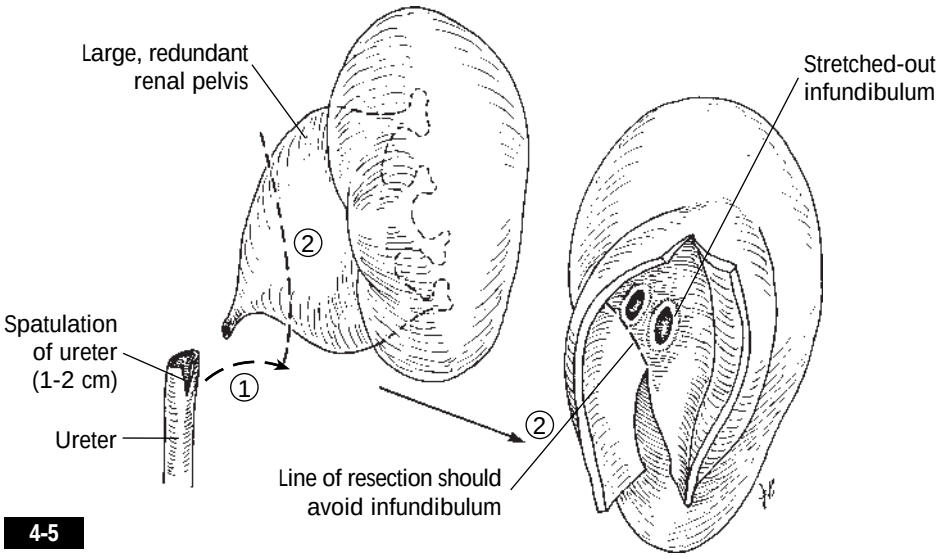

4-5

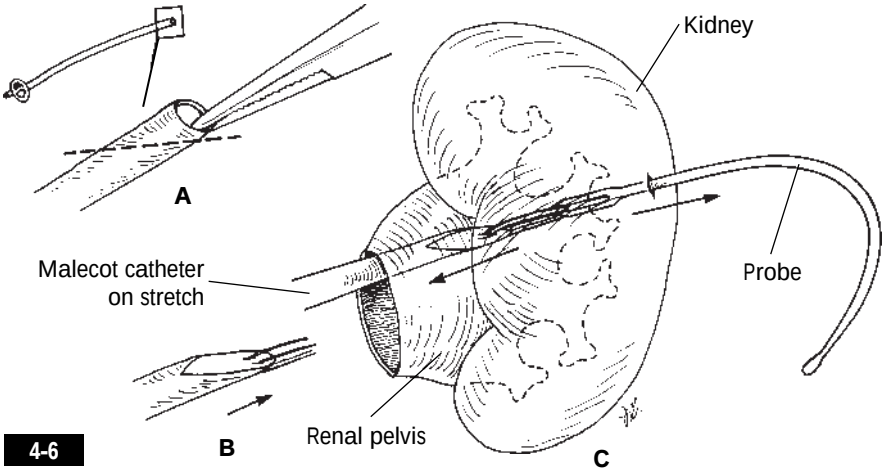

4-6

NEPHROSTOMY TUBE PLACEMENT BEFORE RECONSTRUCTION

FIG. 4-6. If nephrostomy tube placement is indicated, we prefer to use a probe rather than a Randall's forceps for the maneuver.

After the proximal end of a Malecot catheter is cut diagonally **(A),** the surgeon secures it to the probe with a figure-of-eight stitch (0 silk). The placement of this type of stitch between the two ensures that the stitch will not tear out under tension **(B).**

The rounded, blunt distal end of the probe is passed into a selected calyx as well as through the pyramid and cortex.

As the probe exits the kidney and as the diagonal end of the catheter enters the renal parenchyma, the surgeon stretches the Malecot catheter while pulling it through the kidney **(C).** The assistant holds the kidney until the end of the Malecot catheter has passed through the cortex. With this stretching maneuver, the catheter lumen is narrowed while the catheter passes through the cortex. The elastic catheter acts as a tamponade of the renal puncture, with resultant decreased bleeding as compared with that which occurs with the use of Randall's forceps.

Mobilization of Kidney

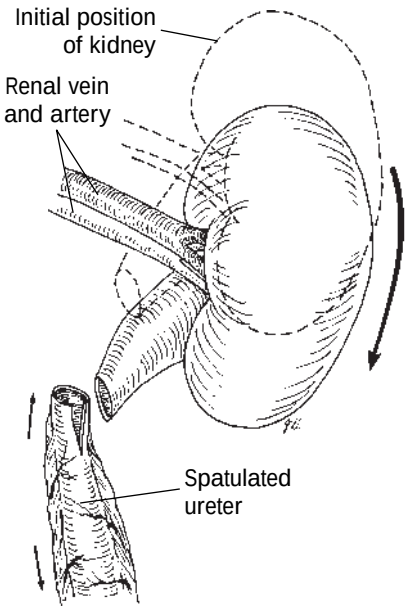

4-7

RECONSTRUCTION OF URETERAL PELVIC JUNCTION

The ureteral stent previously passed into the bladder ensures no ureteral twisting or obstruction.

FIG. 4-7. If the most dependent portion of the renal pelvis marked with the silk stitch does not easily meet the spatulated ureteral end, the following maneuvers should be considered:

1. Mobilize the ureter with its adventitia further.
2. Dissect the kidney free from the Gerota's fascia, especially at the superior pole, and free the renal artery and vein from the adjacent soft tissue. This maneuver permits a downward movement of up to 3 cm.

FIGS. 4-8 AND 4-9. After adynamic ureteral segment resection, the surgeon may modify the dismembered renal pelvis for a V-flap or perform any of a number of other techniques. The goal is dependent drainage, funneled ureteral pelvic junction, smooth anastomosis, and no twists.

Dismembered V-Flap

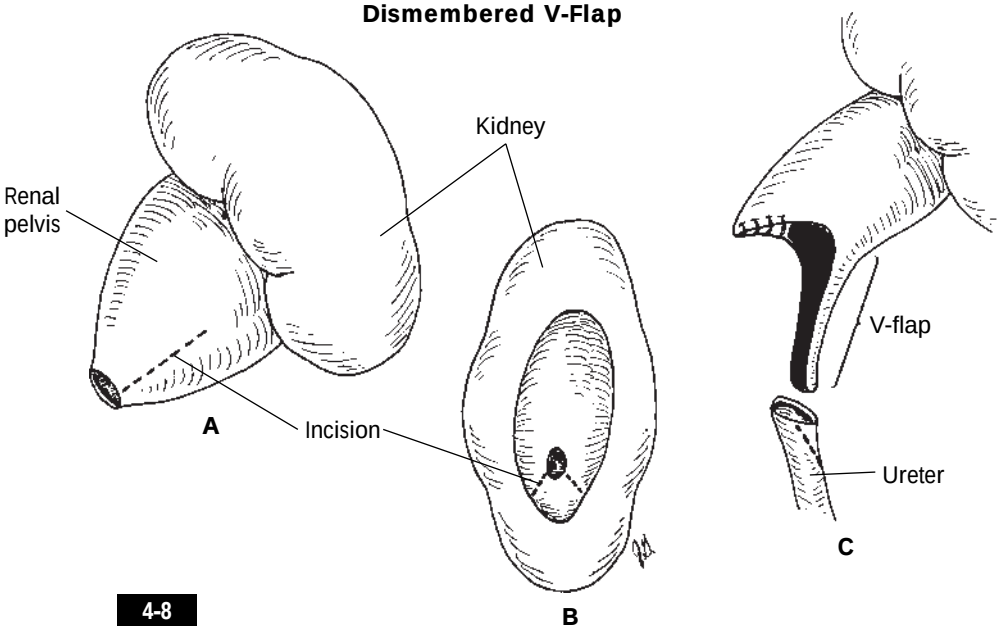

4-8

Dismembered Spiral Flap

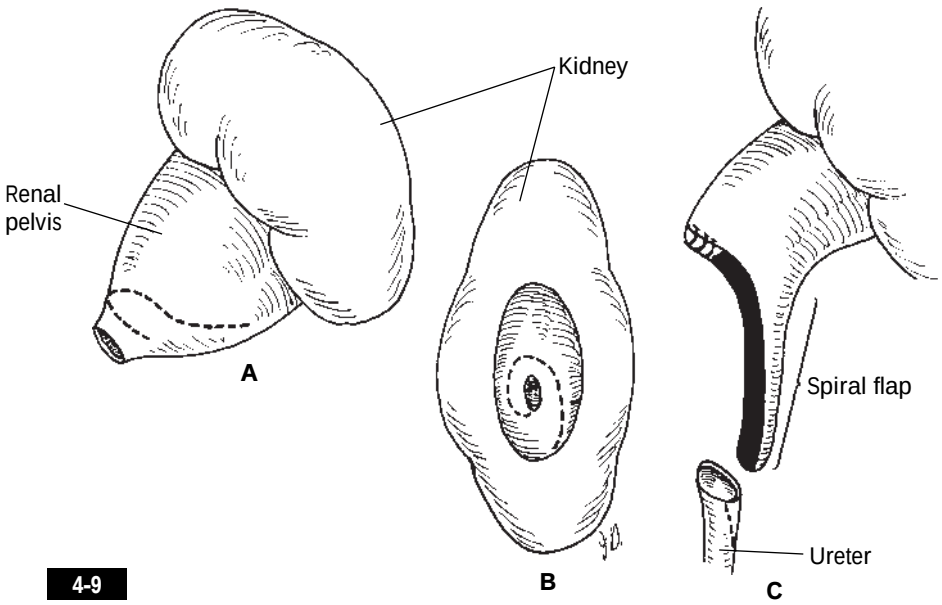

4-9

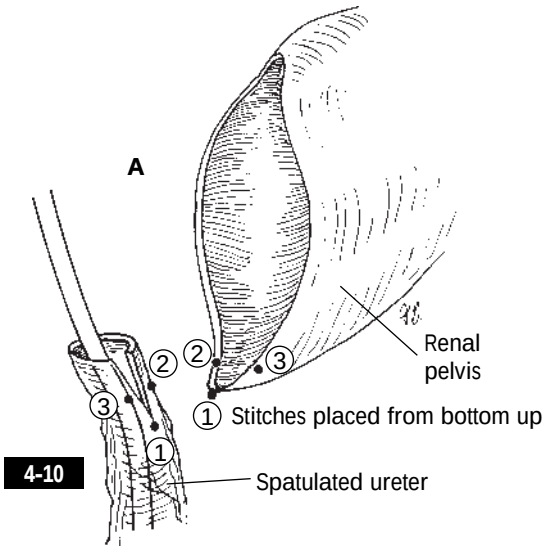

4-10

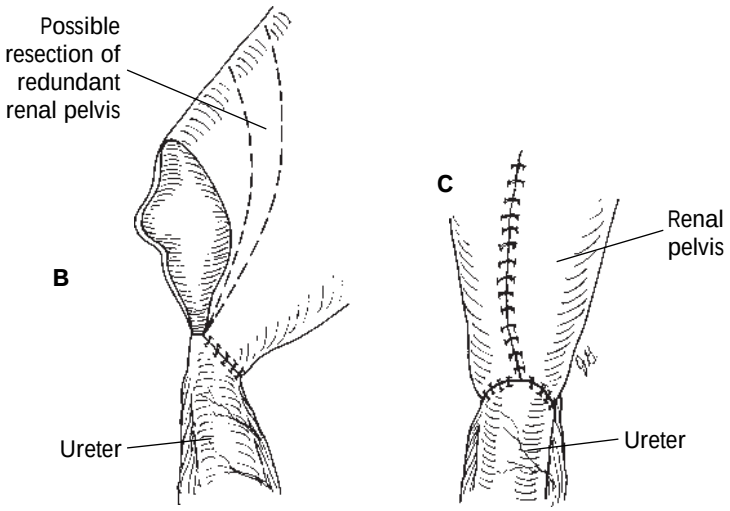

Davis Intubation

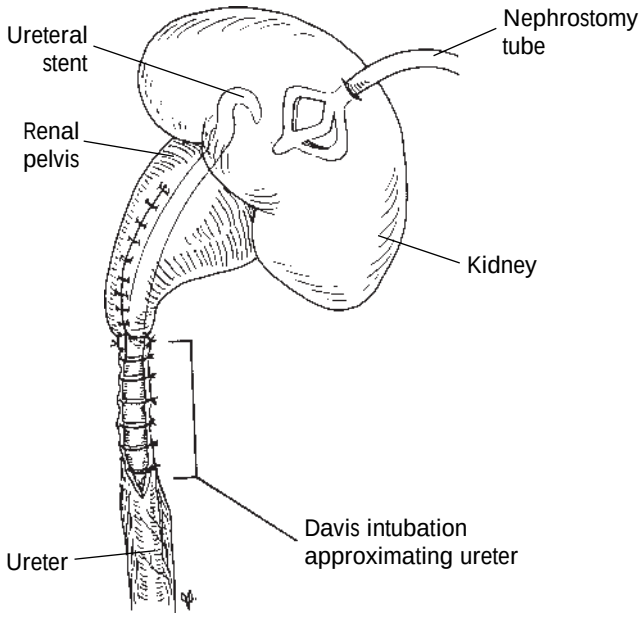

4-11

FIG. 4-10. When the ureter is reanastomosed to the renal pelvis, the best method is *to begin from the lowest portion and to work upward.* This approach ensures the widest lumen and allows for further tailoring of the renal pelvis above the anastomosis.

The surgeon should place three vertex interrupted stitches (4-0 Vicryl) at the spatulated end of the ureter to the most dependent portion of the renal pelvis.

After these three extremely important stitches have been made, a watertight stitch (4-0 Vicryl) is used to reapproximate the rest of the renal pelvis. A 2-0 Vicryl interrupted stitch can be placed at 2 cm intervals for reinforcement. The ureteral stent is removed.

DAVIS INTUBATION FOR LONG URETERAL STRICTURE

In situations in which there is a long, strictured proximal ureter or the gap between the healthy renal pelvis and the ureter is greater than 2 cm, Davis intubation is an excellent procedure to re-create continuity.

FIGS. 4-11 AND 4-12. After a nephrostomy tube has been placed, the surgeon must bring the urothelium of the pelvis in contact with the urothelium of the ureter.

This contact point of urothelium can be accomplished by both kidney and ureteral mobilization.

The surgeon places mattress stitches around the ureteral stent (5 or 6 Fr) to fix the free margins of the narrowed ureter. A drain should be placed adjacent to the repair.

During a 3- to 6-week interval, the urothelium and muscle will grow around the ureteral stent and reestablish continuity between the ureter and renal pelvis. A nephrostogram will confirm continuity.

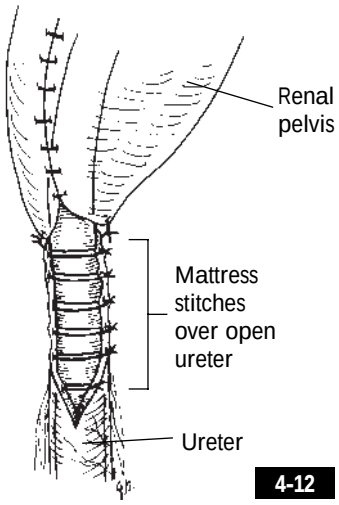

4-12

KEY POINTS

- The adynamic ureteral segment at the ureteral pelvic junction is located.
- Marking stitches are placed on the renal pelvis side and the ureteral side before resection of the adynamic segment.
- The adynamic segment is resected.
- Ureteral spatulation is performed immediately and a ureteral stent (5 or 6 Fr) is passed down the spatulated ureter into the bladder.
- The renal pelvis must be transposed anterior to any aberrant crossing vessels.
- The resection of a large, diseased redundant renal pelvis should be considered; however, cutting into a stretched calyx must be avoided.
- Further mobilization of the ureter and/or kidney should be considered if needed to avoid tension at the anastomosis site.
- The use of a V-flap or spiral flap can be considered.
- A nephrostomy tube is placed.
- Anastomosis should begin from the lowest portion of the renal pelvis and spatulated end of the ureter and continued upward.
- Three vertex interrupted stitches and running stitches are placed to reapproximate the ureter and the renal pelvis; in addition, interrupted stitches (2-0 Vicryl) are placed for support.
- The renal pelvis is tailored if needed.
- Davis intubation is constructed in the case of a long, strictured ureter.
- Drains are placed.

POTENTIAL PROBLEMS

- *Crossing aberrant vessels that are necessary for renal perfusion:* Transpose the cut renal pelvis anterior to the vessels
- *Resection of redundant pelvis with accidental calyceal injury:* Repair the calyx, leaving a margin more distal for the anastomosis, and cut the renal pelvis distal to it
- *Bleeding at nephrostomy tube site*: Apply manual compression → use Teflon felt sandwich technique if needed (see pp. 25, 44)
- *Large gap between renal pelvis and ureter*: Mobilize the ureter → mobilize the kidney and renal vessels → use a V-flap or spiral flap → construct Davis intubation

RETROPERITONEAL LYMPH NODE DISSECTION

5

TRANSABDOMINAL APPROACH

The transabdominal midline incision with complete bowel mobilization provides one of the best surgical exposures for retroperitoneal lymphadenectomy.

FIG. 5-1. The incision extends from the xiphoid process to 6 cm below the umbilicus.

FIGS. 5-2 AND 5-3. For both left- and right-sided tumors, a right-sided, posterior parietal peritoneal incision extends from the foramen of Winslow, around the cecum, and up the mesenteric root to the ligament of Treitz.

If there is bulky disease, it is critical to make the incision into the foramen of Winslow and to divide the ligament of Treitz itself. Small vessels within the ligament need to be coagulated.[1]

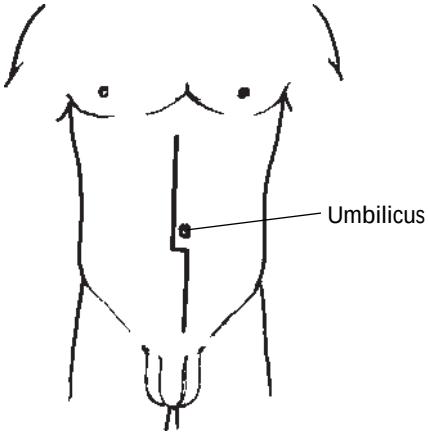

5-1

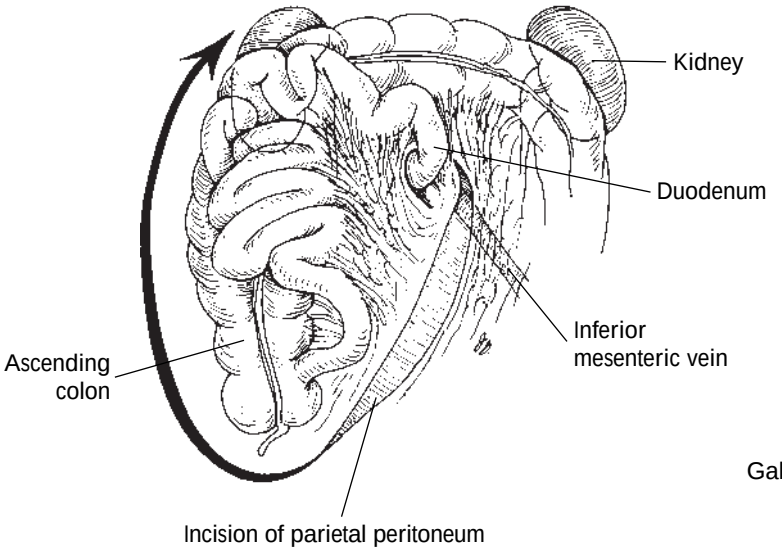

5-2

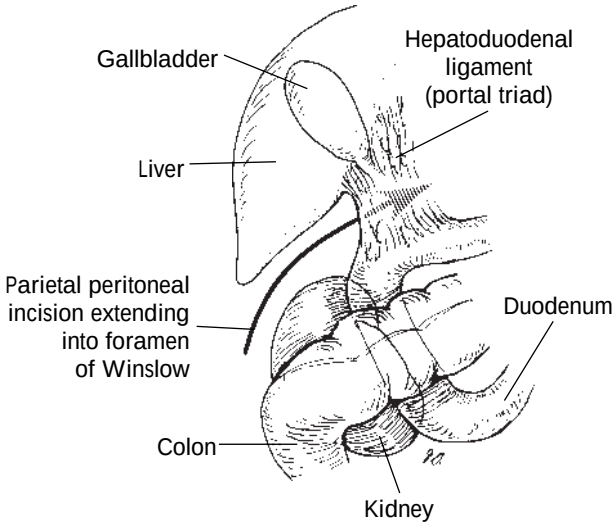

5-3

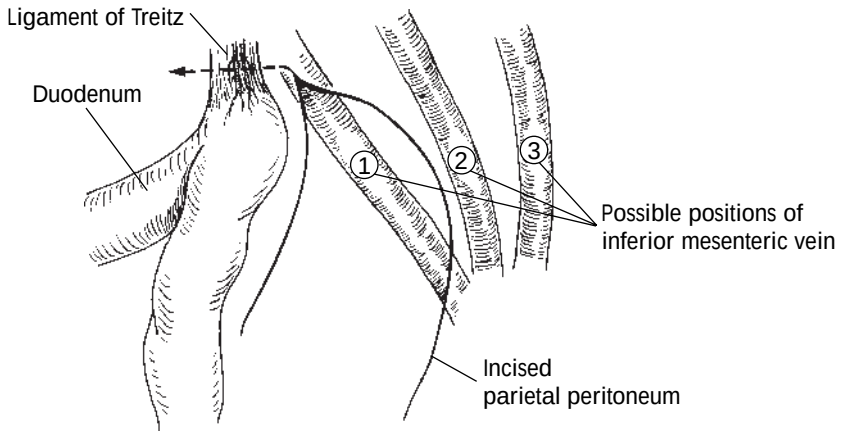

5-4

Variations in Anatomy of Inferior Mesenteric Vein

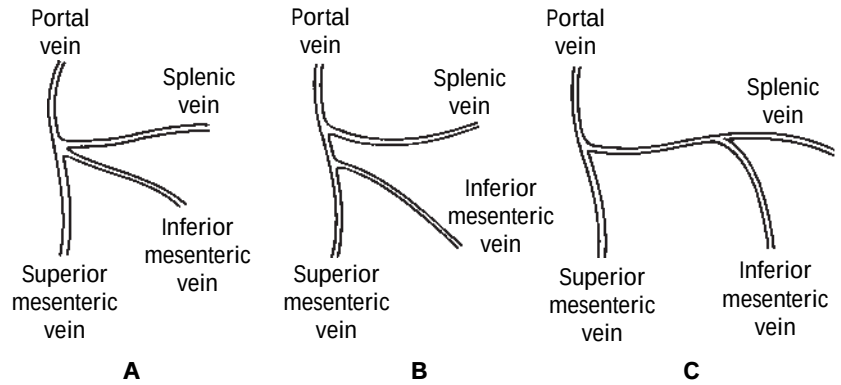

5-5

FIGS. 5-4 AND 5-5. The inferior mesenteric vein drains part of the left transverse colon, the descending colon, and the rectum. The inferior mesenteric vein can vary in its location and may join the splenic vein laterally or medially or even the superior mesenteric vein directly. The superior mesenteric vein drains the ascending colon and right transverse colon. When bulky disease compresses the vena cava, this inferior mesenteric vein can become quite large. This vessel may be under tension after the bowel is mobilized. Depending on the location and size of the inferior mesenteric vein, we generally divide it to gain further exposure.

FIG. 5-6. The Kocher maneuver frees the duodenum, exposing the right kidney and part of the vena cava (see pp. 11-12).

The right colon, part of the transverse colon, and the small bowel are packed with a laparotomy pad into a bowel bag and placed over the chest wall. The laparotomy pad prevents the bowel from slipping out.

FIG. 5-7. Anterior to the superior mesenteric artery, pancreas, and renal pedicles, there are bands of small lymphatic tributaries that must be divided to gain the proper exposure.

FIG. 5-8. Part of the body of the pancreas is now reflected cephalad with the superior mesenteric artery and the duodenum. When the Harrington retractor blade is placed over the region of the reflected pancreas, the assistant should be aware that excessive compression causes pancreatic contusions.

Kocher Maneuver

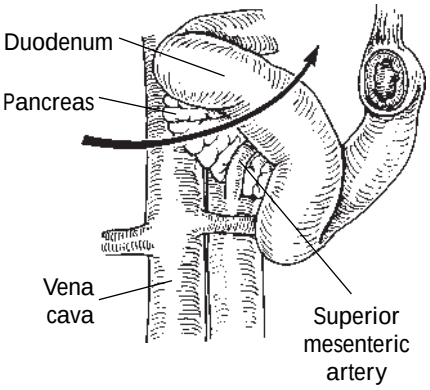

5-6

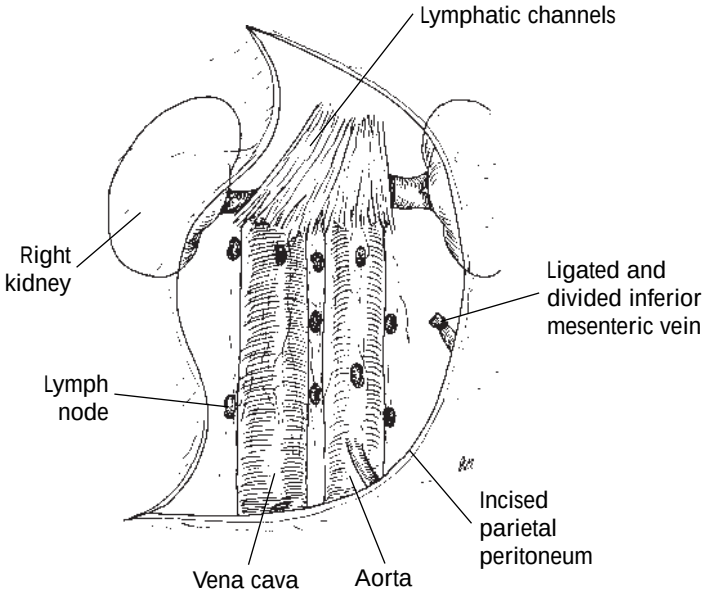

5-7

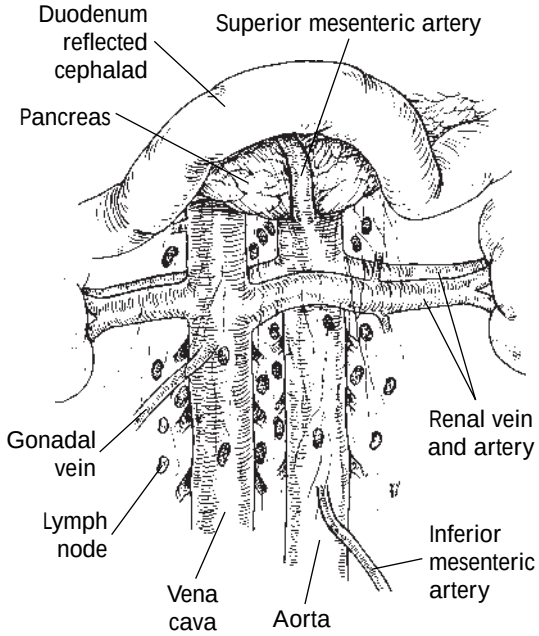

5-8

LYMPHADENECTOMY

FIG. 5-9. We prefer to use the template method of lymphadenectomy for emission preservation[2] rather than a specific nerve-sparing dissection.[3,4] There is 95% chance of preservation of emission by the template method.

The templates shown here for right-sided and left-sided lymph node dissection represent a complete bilateral dissection above the level of the *inferior mesenteric artery* and a unilateral dissection below the inferior mesenteric artery. On the right side, the dissection is carried along the right renal hilar area to the level of the right ureter and down to where the ureter crosses the common iliac artery. The ipsilateral gonadal vessels are removed to the level of the deep inguinal ring and the previously ligated stump of the spermatic cord. For left-sided dissection, the template is similar, with the exception of the right lateral margin. Since nodal spread tends to occur from right to left, dissection is carried only to the lateral margin of the inferior vena cava rather than all the way to the right ureter.

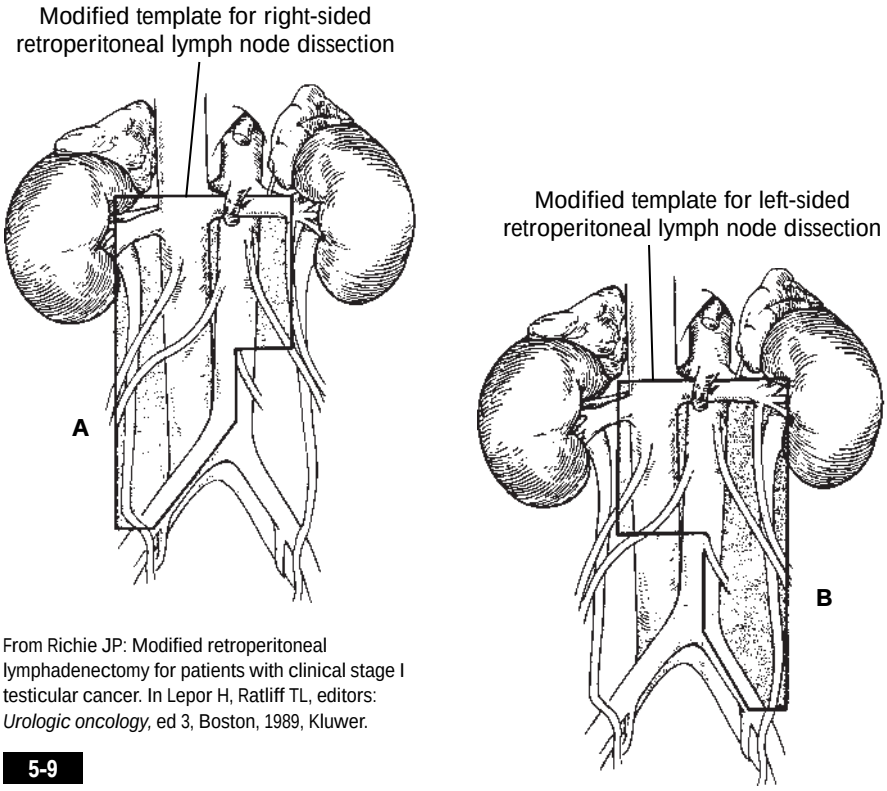

From Richie JP: Modified retroperitoneal lymphadenectomy for patients with clinical stage I testicular cancer. In Lepor H, Ratliff TL, editors: *Urologic oncology,* ed 3, Boston, 1989, Kluwer.

5-9

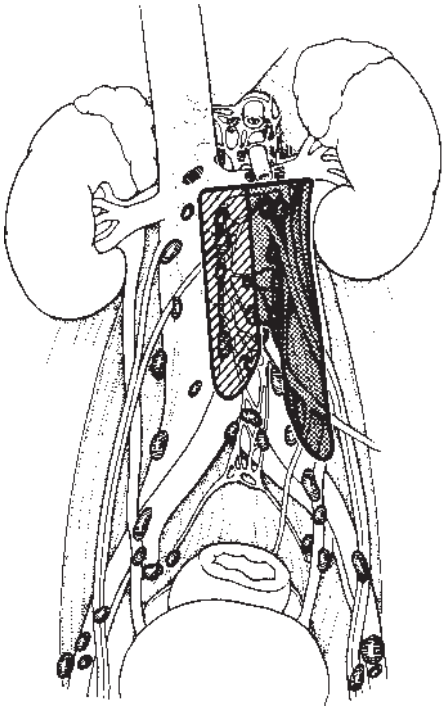

From Donohue JP et al: *J Urol* 144:287, 1990.

5-10

FIG. 5-10. The most common sites of involvement and the frequency of regional involvement for all stages are well documented.[4,5] The primary zone of metastatic spread for right testis tumors is the right paraaortic or interaortocaval zone *(cross-hatched area).* However, in standard retroperitoneal lymphadenectomy, for right-sided tumors the dissection template is routinely extended to include the right iliac and right paracaval nodes. The primary zone of metastatic spread for left testis tumors is the left paraaortic zone *(stippled area).*

FIG. 5-11. In their study of the distribution of nodal metastases in nonseminomatous testis tumors, Donohue, Zachary, and Maynard[4] found that patients with right-sided stage IIA tumors **(A)** had an overwhelming preponderance of positive interaortocaval nodes (*circles* represent the location of positive nodes). In addition, precaval nodes were often involved. Suprahilar nodal involvement was absent and contralateral and iliac involvement was rare. In right-sided stage IIB disease **(B),** nodal distribution was more widespread and the suprahilar, preaortic right paracaval, and iliac zones were more often involved. Large, palpable tumors extended into the suprahilar zone in right-sided stage IIC disease **(C).** A larger number of positive iliac nodes, caused by the retrograde flow of lymph, were found.

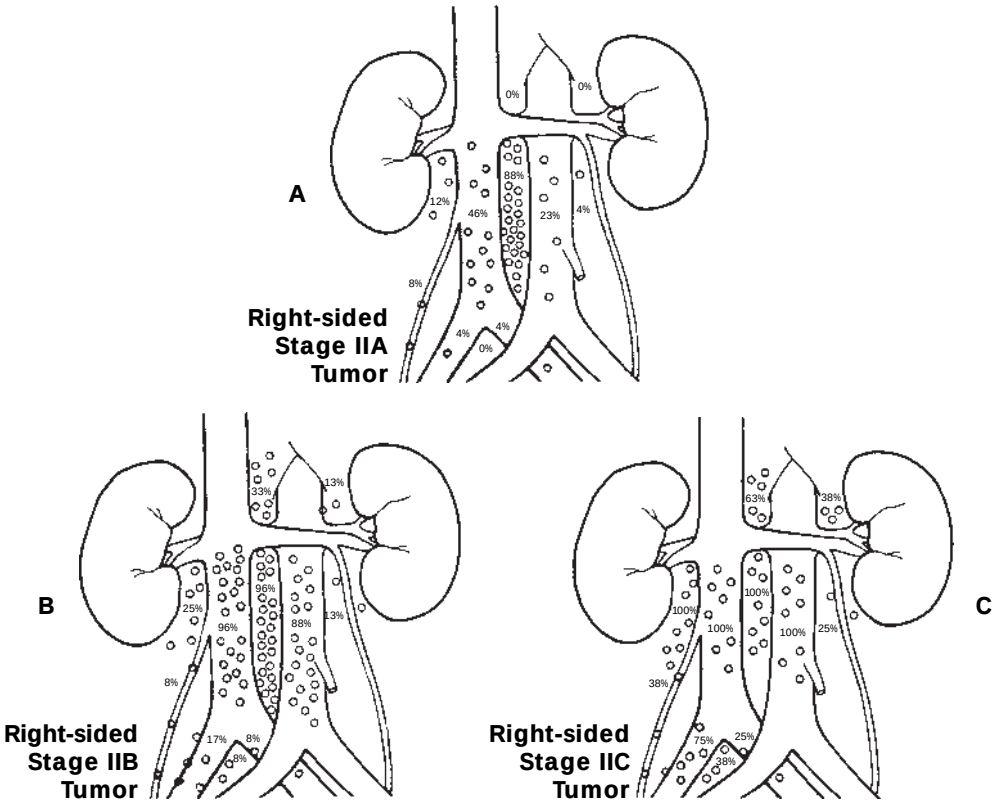

From Donohue JP, Zachary JM, Maynard BR: *J Urol* 128:315, 1982.

5-11

FIG. 5-12. In left-sided stage IIA disease, the left paraaortic zone below the renal vein and the preaortic zone were most commonly involved **(A).** Contralateral caval, paracaval, and iliac involvement was absent. In a few cases, the suprahilar nodes were involved but they were paraaortic and located just above the level of the renal arteries. Left-sided stage IIB tumors spread into the interaortocaval, precaval, and suprahilar zones **(B),** whereas left-sided stage IIC palpable masses involved the suprahilar zones by direct extension of the tumor mass **(C).** In addition, in stage IIC disease, the iliac zones and precaval zones were often involved due to the tumor size.

FIG. 5-13. Division of the retroperitoneum into zones is useful for orientation and sequential dissection. We prefer to send multiple specimens placed on a schematic diagram (as shown) for pathologic evaluation.

A large marking stitch (0 silk) is placed above the inferior mesenteric artery because this site is the inferior midline landmark. Before any dissection distorts the anatomy, marking stitches are placed to define template borders.

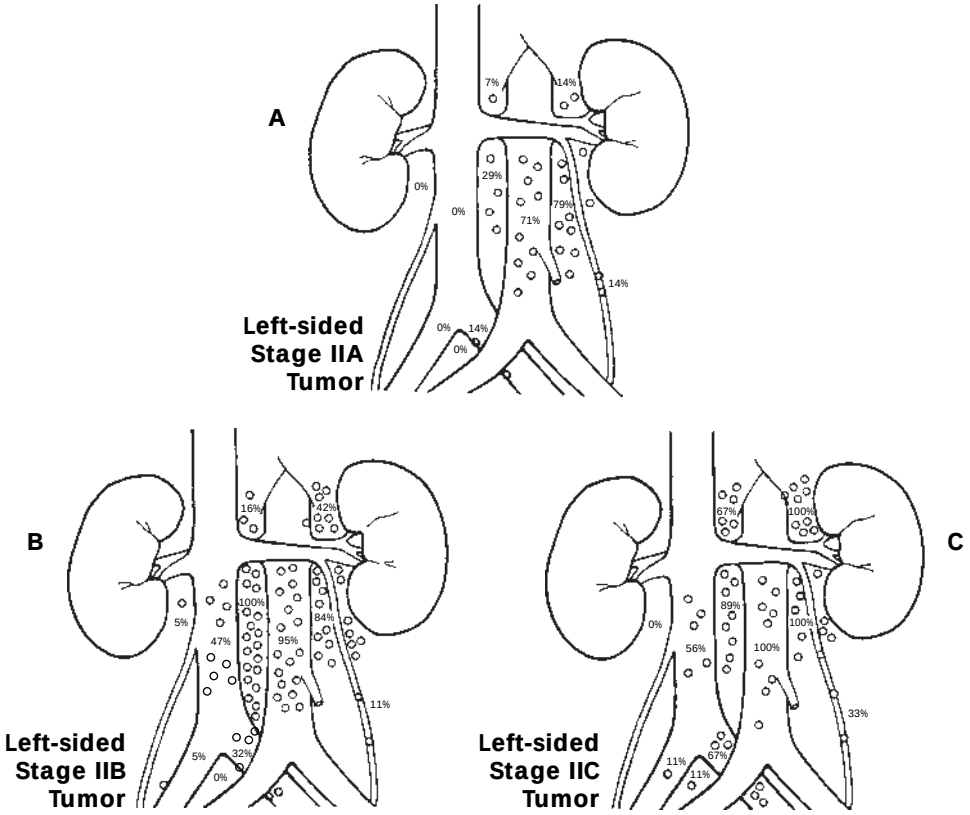

From Donohue JP, Zachary JM, Maynard BR: *J Urol* 128:315, 1982.

5-12

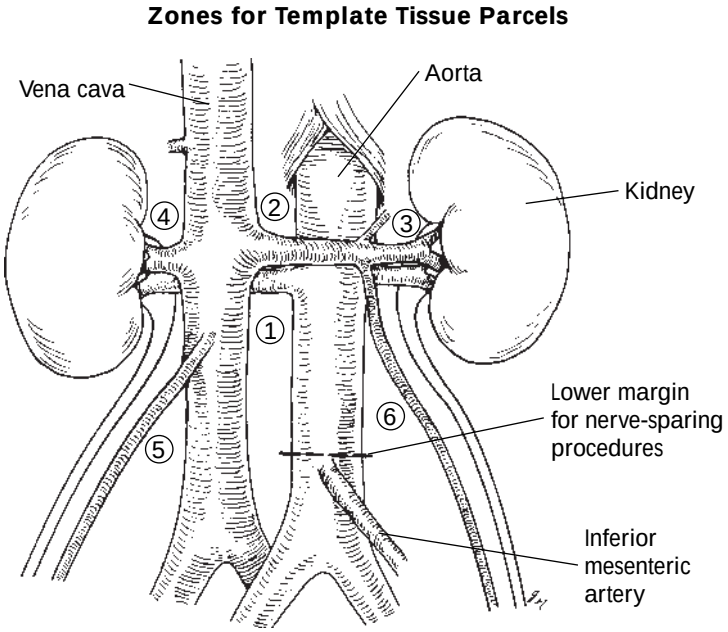

5-13

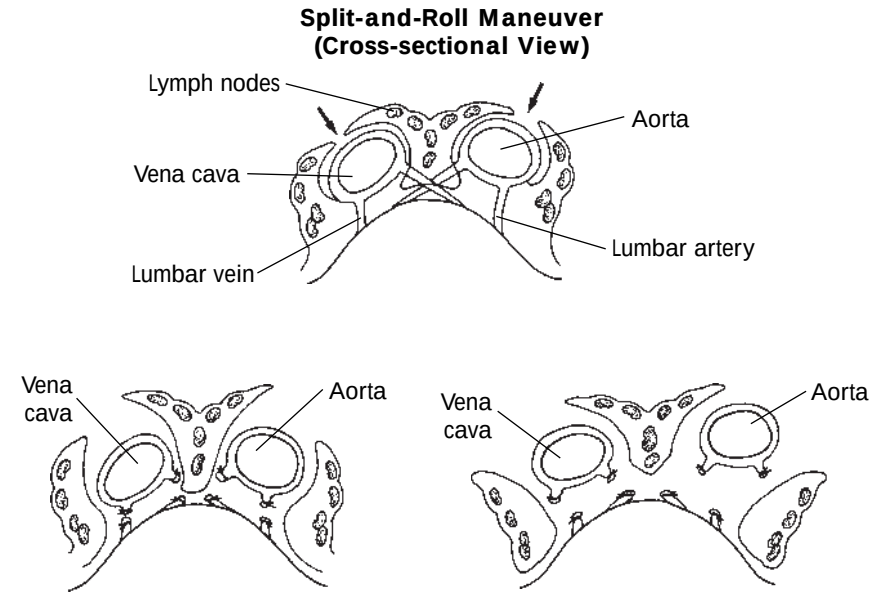

5-14

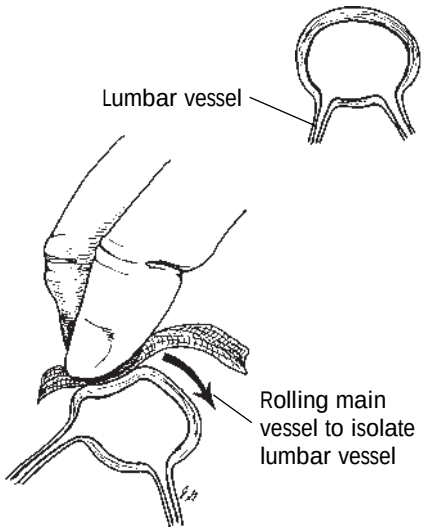

5-15

FIG. 5-14. The split-and-roll maneuver first described by Donohue[5] is the simplest approach for node dissection. After tissues are split anteriorly over the vena cava and aorta, the surgeon sweeps the great vessels away from adjacent fatty tissue and lymph nodes.

This maneuver is easiest if traction is applied with Singley forceps to hold the nodes laterally while the surgeon uses Kitner dissectors (tonsil clamp with ball of gauze clamped at tip) to push the vessels medially.

FIG. 5-15. With a thin layer of dry sponge between the surgeon's finger and the blood vessel, the surgeon gently rolls the vessel medially. The lateral lumbar vessels are thus easily exposed at the base.

In general, the three pairs of lumbar vessels below the renal pedicle can be divided without complication since most of the patients are young, healthy men. The surgeon should avoid ligating any lumbar arteries at or above the level of the renal pedicle to avoid the unusual but real complication of damage to the spinal cord.[6,7]

VENOUS HEMORRHAGE

FIG. 5-16. During the dissection, inadvertent tears of the lumbar veins are common. Under direct vision, the surgeon uses an Allis clamp to grasp the torn lumbar vein before it recedes into the soft tissues.[8]

FIG. 5-17. If a sudden tear of the vena cava occurs when it is nearly skeletonized, the surgeon can use a three-finger maneuver to arrest the bleeding. The index and middle fingers lift and compress the vessel while the thumb can move back and forth in preparation for the closure with a double-arm stitch (4-0 Prolene) for two rows of stitches.

FIG. 5-18. If there is an early tear of the vena cava before the vessel is skeletonized, the surgeon can use two sponge sticks to compress the vena cava above and below the injury after the vena cava is freed from the aorta. Once the blood has been evacuated with laparotomy pads, the surgeon can repair the laceration. An Allis clamp is placed at each end of the laceration and the surgeon uses a running stitch (4-0 Prolene) to close the defect.[9]

The placement of vessel loops around the vena cava above and below the injury is also helpful. It should be remembered that the vena cava has friable walls, which are easily torn, particularly at the points where tributaries enter.

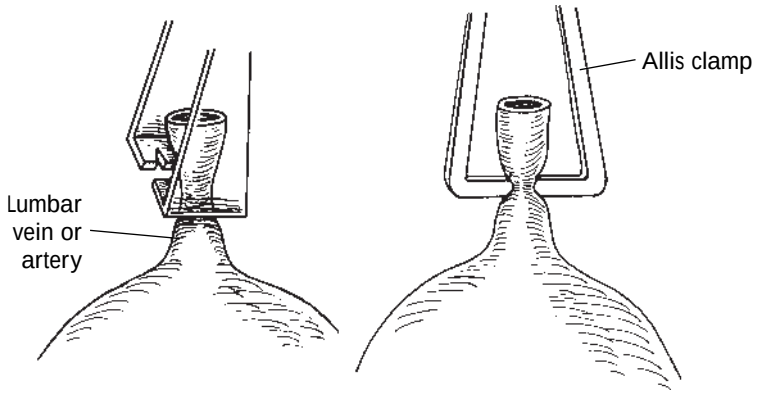

5-16

Three-Finger Compression of Vena Cava

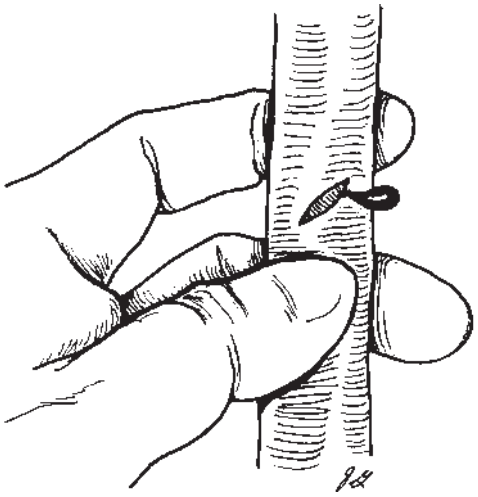

5-17

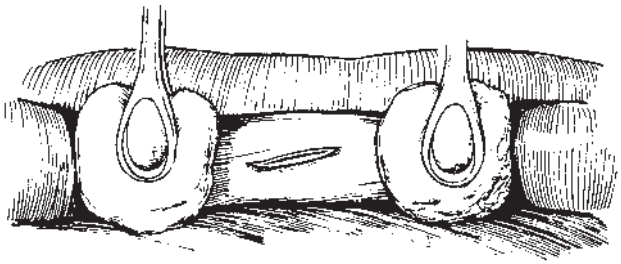

From Hinman F Jr: *Atlas of urologic surgery,* Philadelphia, 1989, WB Saunders.

5-18

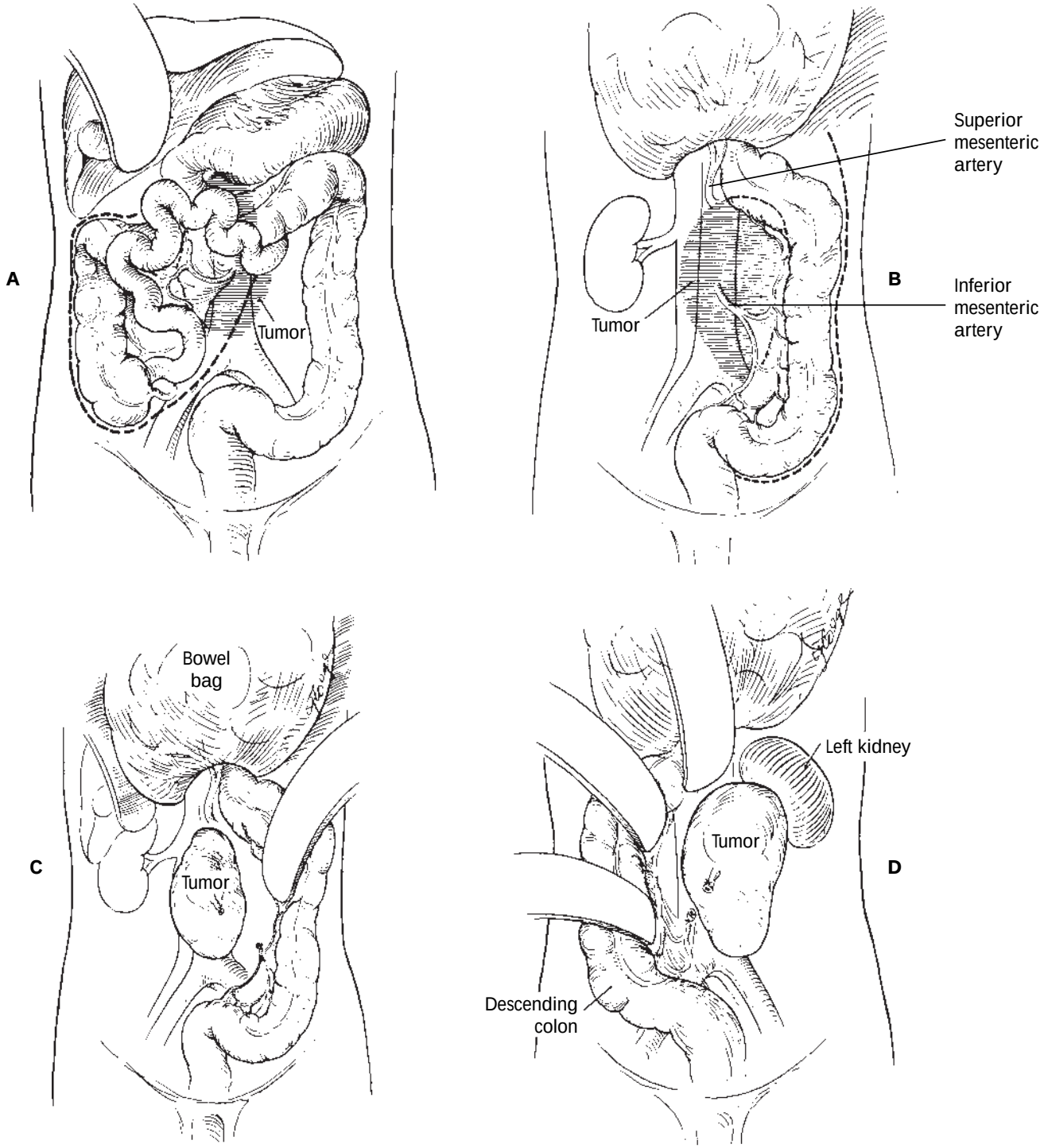

From Skinner DG: *J Urol* 117:605, 1977.

5-19

EXPOSURE OF AND SURGERY FOR BULKY RESIDUAL DISEASE

FIG. 5-19. To obtain maximal exposure, the surgeon must carry the initial peritoneal incision in the right posterior parietal peritoneum along the line of Toldt all the way up into the foramen of Winslow (to the region of the bile duct) and around the mesenteric root with division of the ligament of Treitz **(A).** Complete mobilization of the small bowel, ascending colon, duodenum, and part of the pancreas must be achieved.[3,8]

After the peritoneal attachments to the colon and small bowel mesentery have been incised, the intraabdominal contents are placed in a bowel bag and placed on the anterior chest wall, thus exposing the entire retroperitoneum **(B).** The surgeon must avoid placing excessive tension on the superior mesenteric pedicle.

For exposure of left-sided tumors, the spleen and transverse and descending colon are mobilized **(C).** For extensive tumors the right colon and small bowel are mobilized, placed in a bowel bag, and reflected onto the chest wall.

A left parietal peritoneal incision may be necessary to obtain the best exposure for a bulky mass extending to the left side **(D).** In this case, ligation of the inferior mesenteric artery is necessary to allow the mobilization of the descending colon. As stated earlier, the surgeon must take care to protect the superior mesenteric artery.

FIG. 5-20. Because 10% of debulking procedures may include ipsilateral nephrectomy, the surgeon should start the dissection from the contralateral ureter to ensure preservation of the remaining functioning kidney and ureter unit.

After chemotherapy, there is usually a dense fibrosis of the lymphatic tissues surrounding the great vessels. The surgeon must first define a dissection plane between the vessels and the tumor. Dissection in the subadventitial plane below the fibrous capsule of the tumor is the best approach **(A).**

Once a clear separation is started between the great vessels and the mass, the surgeon can use medial traction with right-angle clamps and gradually dissect the mass from the retroperitoneum **(B).**

A

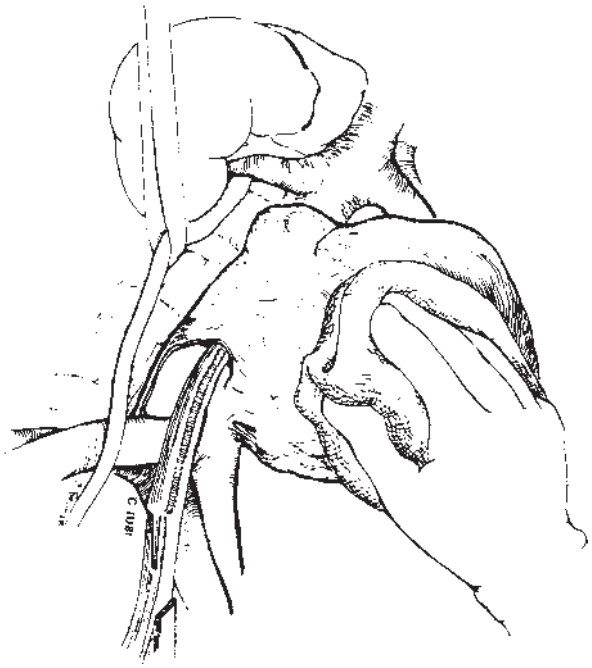

B

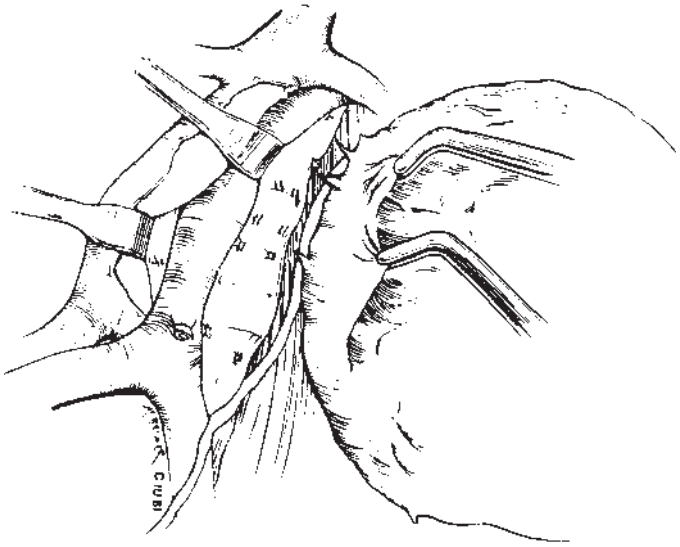

From Donohue JP: *Testis tumors,* Baltimore, 1983, Williams & Wilkins.

SUPRAHILAR NODAL DISEASE

If suprahilar nodal involvement is anticipated from preoperative radiologic studies, the surgeon should be prepared to extend the midline incision and create a thoracoabdominal incision. In addition, the patient should be positioned at a 45-degree angle at the chest level as for a thoracoabdominal radical nephrectomy to obtain the best exposure of the high retroperitoneum with mobilization of the liver (see pp. 2-3).

FIGS. 5-21 AND 5-22. In general, nodal involvement occurs behind the crus of the diaphragm and above. The crura can easily be palpated as two leaves on either side of the aorta and can be divided for improved exposure.[5,10] This maneuver is blind, guided by only the surgeon's finger palpation of the diaphragmatic crus.

To learn this maneuver, the urologist should assist a thoracic surgeon with cases involving aortic aneurysm repair.

Residual higher masses should be approached directly from above in the pleural cavity.

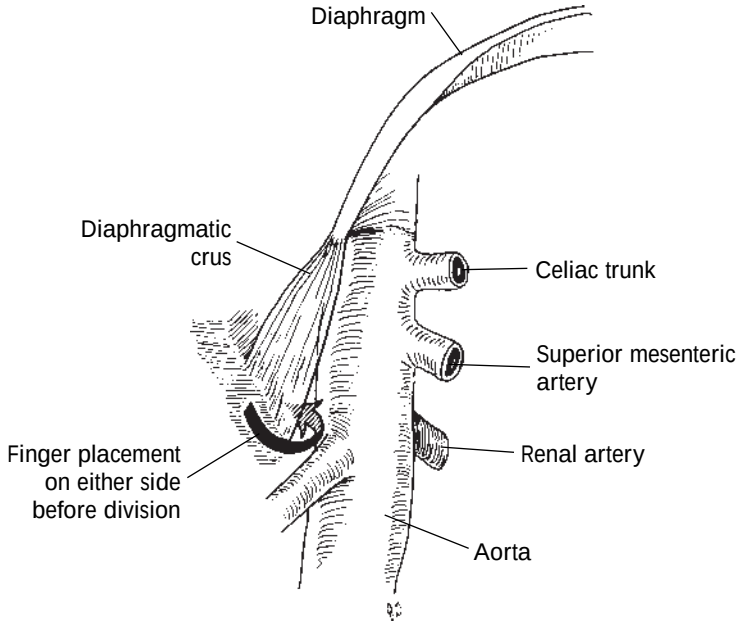

5-21

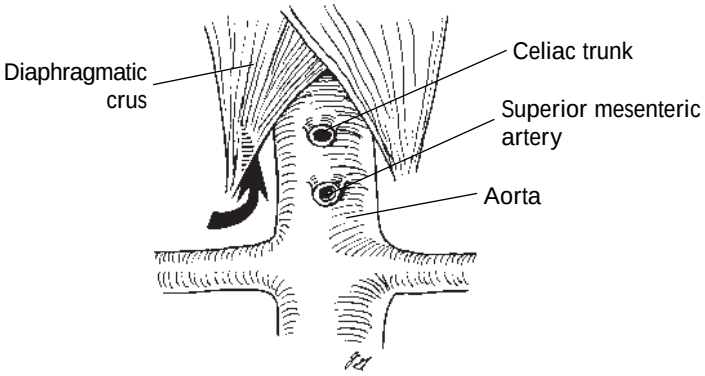

5-22

KEY POINTS

- An incision is made lateral to the right colon extending from the foramen of Winslow, around the cecum, and up the mesenteric root to the ligament of Treitz.
- The inferior mesenteric vein is divided.
- The bowel is packed into a bowel bag and is reflected cephalad on the chest.
- With the pancreas reflected cephalad, the superior mesenteric artery is located by palpation and the Harrington retractor is placed over the region of the reflected pancreas.
- For a template nerve-sparing procedure, a large marking stitch is placed over the inferior mesenteric artery and other marking stitches are inserted to define template borders.
- The split-and-roll maneuver is performed.
- A multiple specimen analysis on the schematic diagram is prepared.
- Diaphragmatic crus division is performed for suprahilar node dissection.
- Bulky disease dissection is performed with preservation of the functioning contralateral renal unit.

POTENTIAL PROBLEMS

- *Poor exposure*: Check the incision to the foramen of Winslow and around to the ligament of Treitz → divide the ligament of Treitz → divide the inferior mesenteric vein
- *Vena cava tear*: Use a three-finger maneuver → apply compression with sponge sticks above and below the tear → control the vessel above and below the tear with vessel loops → perform double-arm stitch (Prolene 4-0) for closure
- *Injury of inferior mesenteric artery*: Proceed with surgery
- *Injury of lumbar artery above renal pedicle unilaterally*: Preserve the other side and all other lumbar arteries above the pedicles
- *Difficult lymphadenopathy in suprahilar area*: Divide diaphragmatic crura bilaterally
- *Area at inferior margin near inferior mesenteric artery shows positive biopsy*: Perform a full-node dissection and disregard the nerve-sparing template

REFERENCES

1 Edwards EA et al: The duodenum, pancreas, and spleen. In Edwards EA, Malone PD, MacArthur JD, editors: *Operative anatomy of the abdomen and pelvis,* ed 9, Philadelphia, 1975, Lea & Febiger, pp 37-44.

2 Richie JP: Modified retroperitoneal lymphadenectomy for patients with clinical stage I testicular cancer. In Lepor H, Ratliff TL, editors: *Urologic oncology,* ed 3, Boston, 1989, Kluwer, pp 36-53.

3 Donohue JP: Testis tumors. In Libertino JA, editor: *International perspectives in urology,* Baltimore, 1983, Williams & Wilkins.

4 Donohue JP, Zachary JM, Maynard BR: Distribution of nodal metastases in nonseminomatous testis cancer, *J Urol* 128:315, 1982.

5 Donohue JP: Nerve-sparing techniques in urological surgery. Postgraduate course 23, American Urological Association Meeting, 1991.

6 Ferguson LR et al: Spinal ischemia following abdominal aortic surgery, *Ann Surg* 181:267, 1975.

7 Kaswick JA, Bloomberg SD, Skinner DG: Radical retroperitoneal node dissection: how effective is removal of all retroperitoneal nodes? *J Urol* 115:70, 1976.

8 Skinner DG: Considerations for management of large retroperitoneal tumors: use of the modified thoracoabdominal approach, *J Urol* 117: 605, 1977.

9 Hinman F Jr: *Atlas of urologic surgery,* Philadelphia, 1989, WB Saunders.

10 Stoney RJ, Effeney DJ: Thoracoabdominal aorta and its branches. In Stoney RJ, Effeney DJ, editors: *Wylie's atlas of vascular surgery,* Philadelphia, 1992, JB Lippincott.

SUGGESTED READINGS

Donohue JP et al: Nerve-sparing retroperitoneal lymphadenectomy with preservation of ejaculation, *J Urol* 144:287, 1990.

Jewett MAS et al: Retroperitoneal lymphadenectomy for testis tumor with nerve-sparing for ejaculation, *J Urol* 139:1220, 1988.

Lange PH et al: Return of fertility after treatment for nonseminomatous testicular cancer: changing concepts, *J Urol* 129:1131, 1983.

Skinner DG: Technique of nephroureterectomy with regional lymph node dissection, *Urol Clin North Am* 5(1): 253, 1978.

TRANSURETEROURETEROSTOMY

6

ISOLATION OF URETERS AND POSTERIOR PERITONEAL TUNNEL

After incising the avascular line of Toldt lateral to the colon, the surgeon immediately isolates both ureters with vessel loops.

FIGS. 6-1 AND 6-2. The incision is extended from around the cecum up the mesenteric root, allowing the surgeon to mobilize the donor ureter more easily.

In essence, this maneuver allows for a shorter posterior parietal peritoneal tunnel for the donor ureter (*2* on Fig. 6-1); it also permits the surgeon to inspect the tunnel more easily to ensure that the angulation is gradual and wide.

FIGS. 6-3 AND 6-4. In addition, with this maneuver the surgeon can locate the inferior mesenteric artery, which could potentially obstruct the donor ureter.[1]

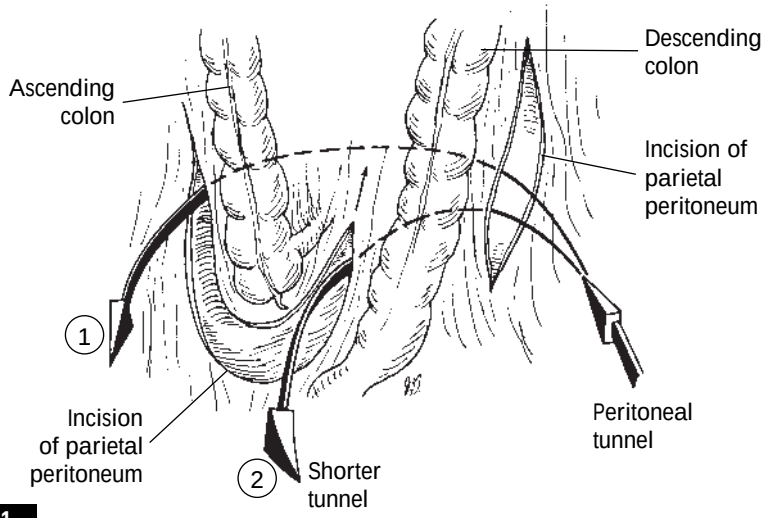

6-1

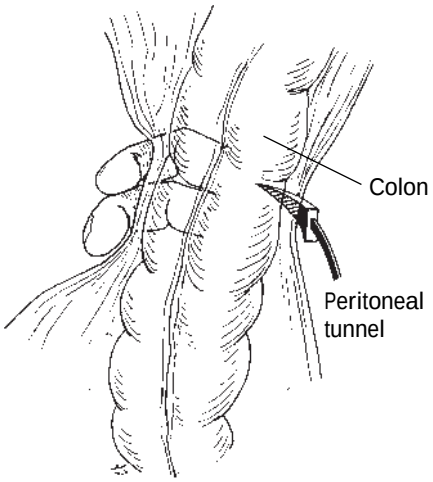

6-2

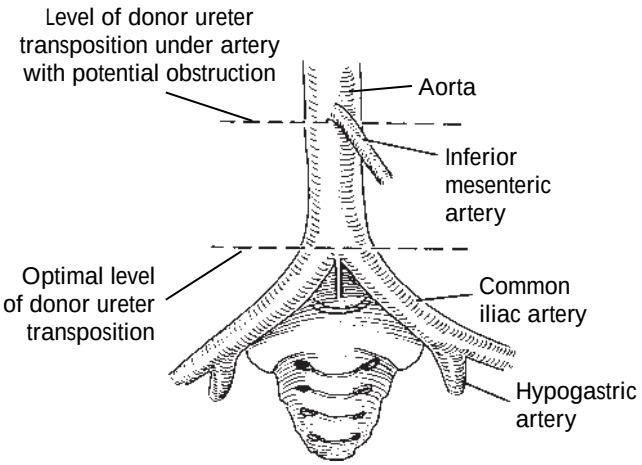

6-3

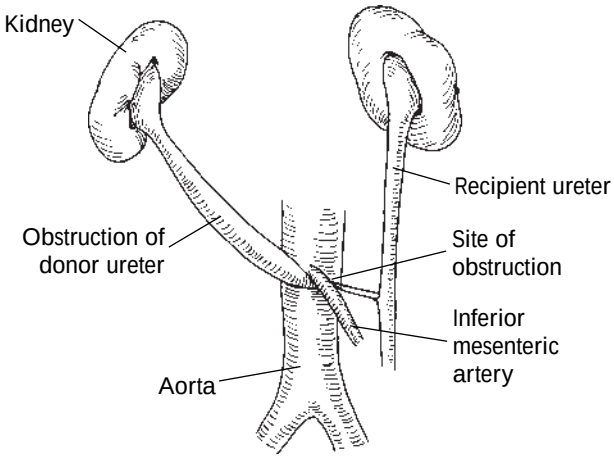

6-4

PERFORMANCE OF A SUCCESSFUL TRANSURETEROURETEROSTOMY

The surgeon must consider four factors:

1. Preservation of the intrinsic vascularity of the donor ureter.
2. Proper mobilization of the donor and recipient ureters to ensure a gradual angulation of the transureteral anastomosis.
3. Creation of a wide posterior parietal peritoneal tunnel without a sharp angulation.
4. Extra-wide anastomosis of the two ureters.

Donor Ureter

FIG. 6-5. The donor ureter should be freed up to the lower pole of its kidney. The ureteral adventitia should be intact and thick to ensure sufficient vascularity.

If the ipsilateral gonadal vessel appears to hold or cause a sharp angulation of the donor ureter, then it should be divided.

Before the recipient ureter is prepared, the donor ureter can be clipped at its free end to dilate the ureter by hydronephrosis. This maneuver facilitates the anastomosis and prevents ureteral twisting.

Recipient Ureter

FIG. 6-5. To ensure a gradual angulation of the ureteral anastomosis, it may be necessary to free a segment of the recipient ureter. Some investigators have emphasized that the recipient ureter should not be disturbed[2]; but we, in agreement with Hodges,[3] have not seen any complications with this maneuver. When either the recipient or donor ureter is mobilized, it is critical that the surgeon leave the adventitia on the ureter rather than denuding it.

At times, it may even be necessary to divide the gonadal vessels on the recipient side to allow gradual angulation for the ureteral anastomosis.

Ureteral Anastomosis

This should be a large side-to-oblique (recipient ureter to donor ureter) anastomosis rather than a side-to-end anastomosis. It should be at least 2 cm wide.

The hydronephrotic donor ureter should be tunneled through the parietal peritoneum to check for a proper anastomotic site. After ureterotomy and ureteral spatulation, the first three vertex stitches (4-0 Vicryl) are placed.

Left-to-Right Transureteroureterostomy

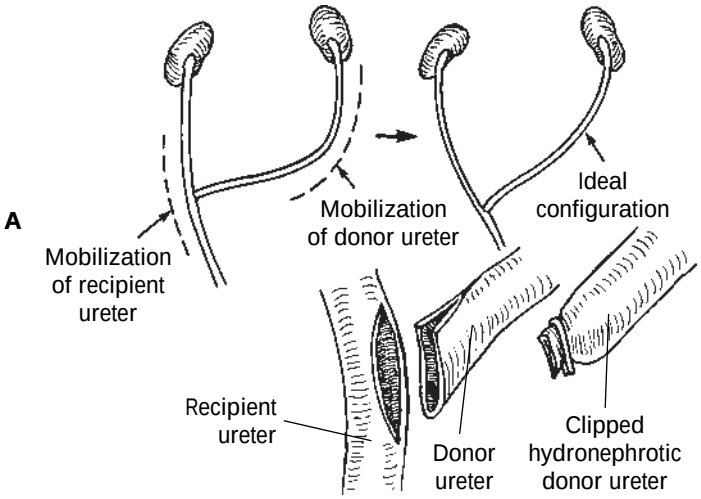

Right-to-Left Transureteroureterostomy

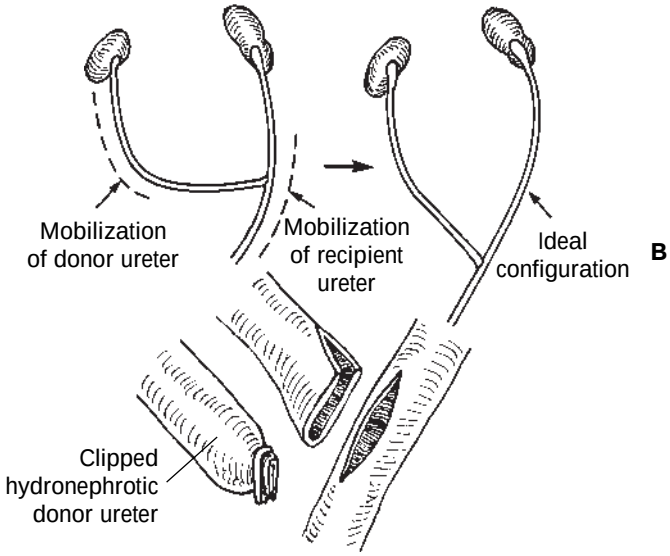

6-5

FIG. 6-6. After the back wall of the ureteral anastomosis is completed, the following is performed: one end of the stent is placed down into the recipient ureter and into the bladder. The other end goes up into the donor ureter on the contralateral side.

We prefer to use Bard (6 or 8 Fr) ureteral diversionary stents, which are long and can be brought through the bladder and fixed to abdominal skin.

The surgeon threads the guidewire into a newly cut hole in the middle of the stent going to the distal open ends. Then the stent guidewire is passed into the bladder via the recipient ureter.

Extra holes are cut into the stent at the anastomotic site and slightly below to ensure drainage from both kidney units. The guidewire is now rethreaded through a cut hole into the other end of the stent and passed into the donor ureter and up to the kidney.

FIG. 6-7. On the bladder end, a small cystostomy is made, and the stent is brought out through the bladder and fixed to the bladder wall with a 4-0 chromic stitch. This stent is then brought out through a separate stab wound and fixed to the skin.

Drains adjacent to the anastomosis are left in place and a Foley catheter or suprapubic tube is left in the bladder.

Ureteral Anastomosis and Stent Placement

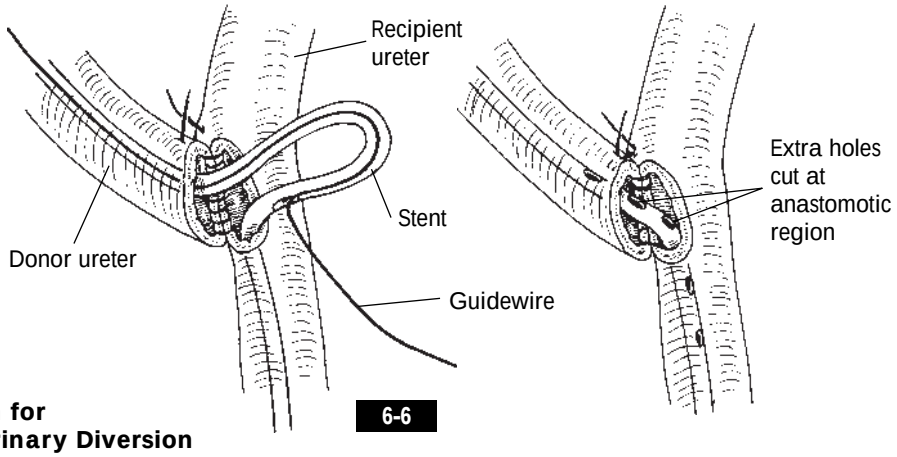

6-6

Optimal Configuration for Transureteroureterostomy with Urinary Diversion

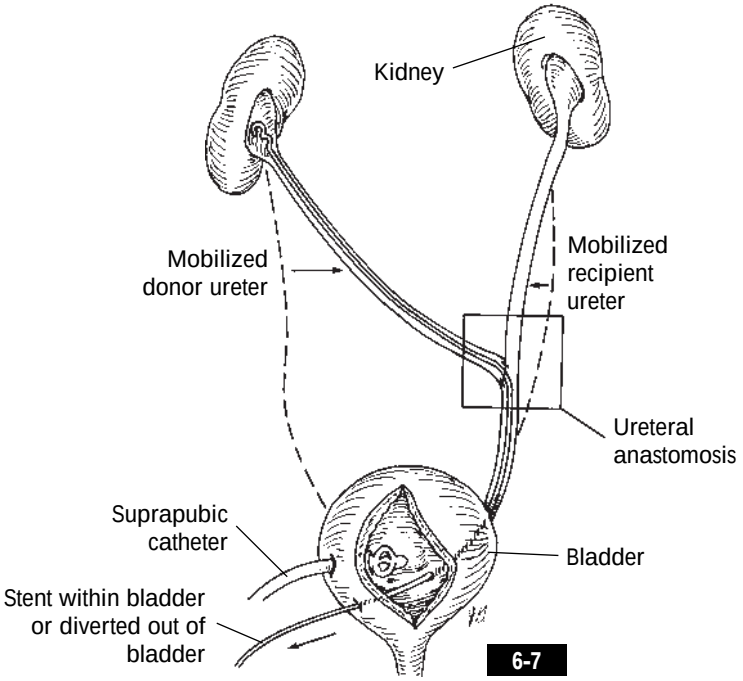

6-7

KEY POINTS

- An incision is made lateral to the colon to isolate the ureter.
- The incision is carried around the cecum and up the mesenteric root.
- The inferior mesenteric artery is located.
- The surgeon ensures that the parietal peritoneal tunnel is wide and has a gradual angle.
- The donor ureter with adventitia is freed to the lower pole of the kidney and clipped at its distal end for dilatation.
- The gonadal vessel is divided if necessary.
- The ureter is tunneled through and checked for the best position for anastomosis.
- The recipient ureter is mobilized, and the gonadal vessel is divided if necessary.
- The donor ureter is spatulated and an anastomosis of at least 2 cm is performed.
- The two ureters must have a gradual angulation such that it is a large side-to-oblique (recipient ureter to donor ureter) anastomosis.
- After the three vertex stitches have been made and the back wall of the anastomosis is complete, the stent is placed.
- The stent is inserted into bladder via the recipient ureter.
- Extra holes are cut in the stent at the anastomosis junction.
- The guidewire is inserted into cut hole, threaded to the proximal end of the stent, and passed up to the donor kidney.
- Drains and a suprapubic tube or Foley catheter are placed.

POTENTIAL PROBLEMS

- *Excessive angulation of donor ureter*: Check the donor ureter for full mobilization to the kidney → check to see if the posterior peritoneal tunnel is adequately wide → check the ipsilateral gonadal vessel division → check for inferior mesentery artery syndrome (ureter trapped under the artery) → check recipient ureter mobilization and gonadal vessel ligation
- *Difficulty placing one stent*: Use two small stents (4 Fr) to each kidney unit

REFERENCES

1 Hodges CV et al: Clinical experiences with transureteroureterostomy, *J Urol* 90:552, 1963.

2 Hendren WH, Hensle TW: Transureteroureterostomy: experience with 75 cases, *J Urol* 123:826, 1980.

3 Hodges CV et al: Transureteroureterostomy: 25-year experience with 100 patients, *J Urol* 123:834, 1980.

PSOAS HITCH, BOARI FLAP, AND COMBINATION OF PSOAS HITCH AND BOARI FLAP

7

The psoas hitch procedure, Boari flap, and transureteroureterostomy are useful operative procedures for reestablishing continuity between the ureter and bladder. Of the three, the most versatile and the one associated with the fewest complications is the psoas hitch procedure. The psoas hitch is a means of extending the bladder's dome or lateral wall cephalad and anchoring the bladder to the surface of the psoas muscle, thereby bridging a gap between the ureter and bladder.

The psoas hitch procedure has been used in a variety of clinical situations: when the distal ureter is scarred secondary to chronic infection or previous surgery, when the ureter has been damaged by trauma, and even when a simple antirefluxing reimplantation of the ureter is necessary.[1]

There are clinical situations when the ureter has already been damaged and severed from the bladder for which vesical-psoas fixation can be performed without first opening the bladder.

Another possible application is when ureteral reimplantation is contraindicated because of a diseased, fibrotic bladder; in this case the bladder could be manipulated cephalad to the psoas muscle for a psoas hitch procedure.

PSOAS HITCH PROCEDURE

With the bladder filled with saline solution instilled through a Foley catheter, the surgeon can easily define the perivesical spaces between the bladder and pelvic walls.

FIG. 7-1. The inferior and posterior peritoneal reflection is easily dissected from the bladder while the bladder is full. This maneuver is not always necessary; however, it provides maneuverability of the bladder dome for the psoas hitch procedure.

FIG. 7-2. As described in Chapter 18, the surgeon defines a space called the *retroperitoneal pocket* on each side cephalad to the perivesical space (see p. 169). The bladder should first be deflated.

Sagittal View

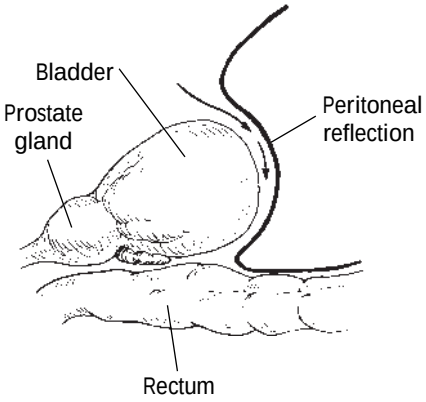

7-1

Development of Retroperitoneal Pockets

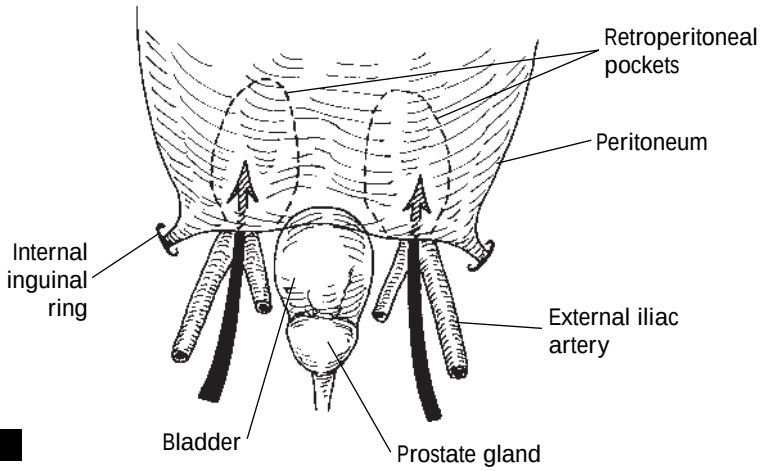

7-2

FIG. 7-3. The index and middle fingers are used to define a space between the posterior peritoneum and the retroperitoneum.

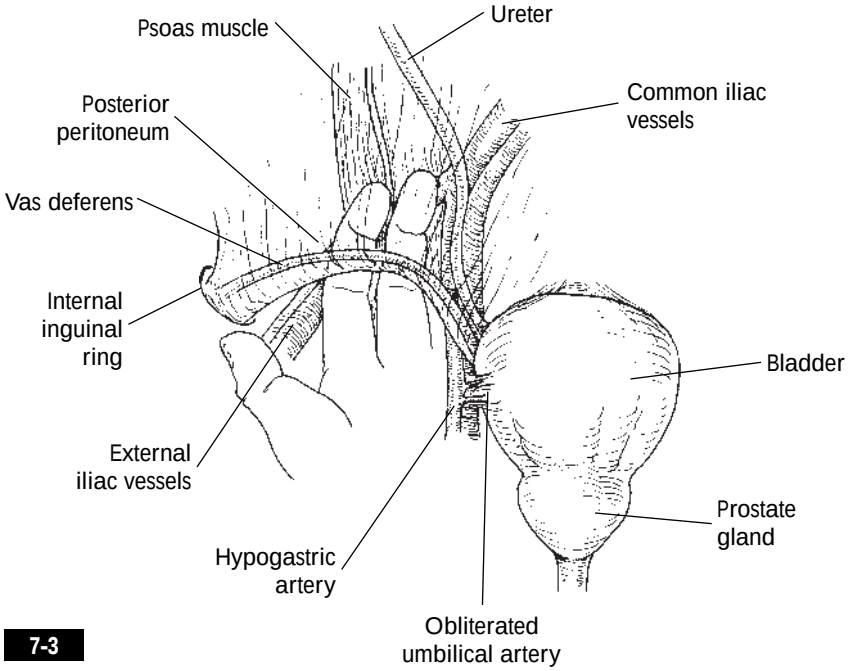

7-3

FIG. 7-4. When the surgeon successfully performs this maneuver, the following landmarks should be adjacent to the fingers: medial to the fingers are the ureter, bladder, and obliterated umbilical artery; lateral to the fingers are the internal inguinal ring, external iliac vessels, and pelvic wall; inferior to the fingers are the psoas muscle, genitofemoral nerve, and hypogastric vessels; and superior to the fingers are the vas deferens and peritoneal shelf.

By this one maneuver, the surgeon exposes not only the psoas muscle and genitofemoral nerve but also the proximal ureter above the obliterated umbilical artery.

Depending on the configuration of the bladder and the thickness of its walls, sometimes the contralateral obliterated umbilical artery and superior vesical artery must be divided to gain more maneuverability.

FIG. 7-5. The bladder, intact or opened, can be stretched onto the psoas muscle more laterally or more superiorly depending on the surgeon's choice, and the genitofemoral nerve can be mobilized

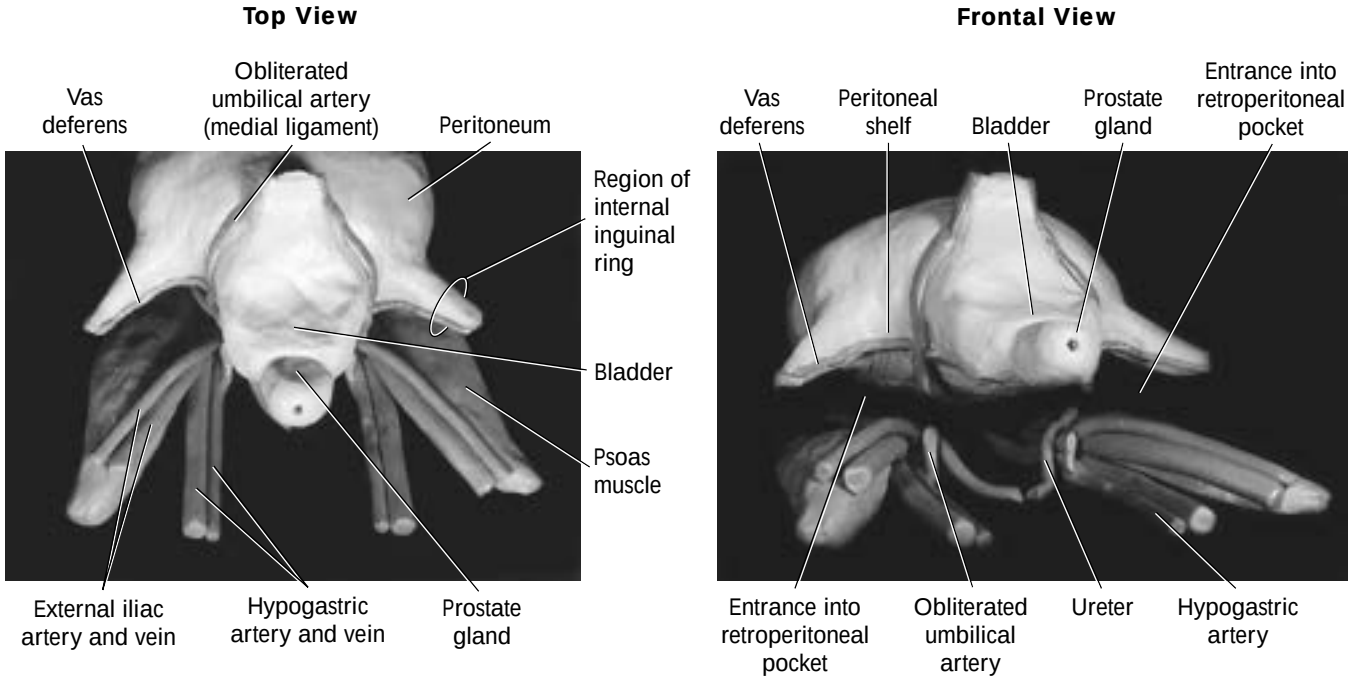

7-4

laterally if necessary. If the bladder is contracted, the surgeon can bathe the bladder dome with local anesthetic (lidocaine 1%), which will make it much easier to stretch the bladder cephalad to a greater extent than expected for fixation.

FIG. 7-6. The bladder is stretched to its maximum and two stitches (0 Vicryl) are placed for vesical-psoas fixation. Full deep suture bites of the bladder are necessary for stabilization. Once fixed, the bladder is opened for the ureteral reimplantation.

FIG. 7-7. If the bladder has been opened by a horizontal incision[2] before the psoas hitch procedure, the surgeon places two fingers into the bladder dome and stretches the bladder maximally in the cephalad lateral direction for placement of the anchoring stitches. Whether the bladder is closed or opened, the important point is to stretch the bladder cephalad as far as possible with tension to gain maximal length.

FIG. 7-8. The ureter and the fixed bladder wall should overlap at least 4 to 6 cm. Ureteral reimplantation can be accomplished in a tunneled fashion or by the Le Duc method (see p. 129).

To ensure an antirefluxing system, a 4:1 ratio of the tunnel length to ureteral width is optimal.

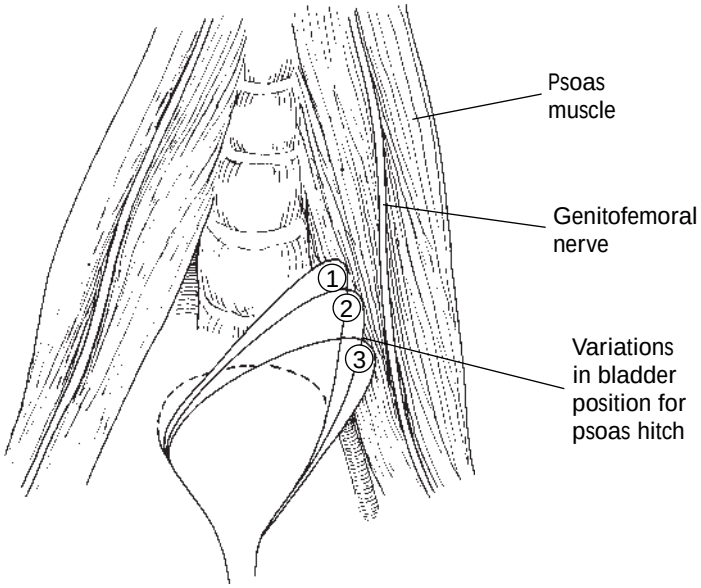

7-5

After spatulating the ureter, the surgeon should anchor the ureter to the full thickness of the bladder with interrupted stitches (2-0 to 4-0 Vicryl).

FIG. 7-9. A stent and a Malecot suprapubic tube are brought out through the bladder and abdomen and fixed in place. Alternatively, self-retaining stents and a Foley catheter through the urethra function just as well but may produce irritative symptoms postoperatively. A drain is placed in the perivesical space.

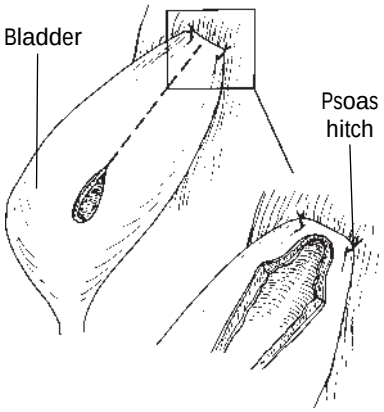

7-6

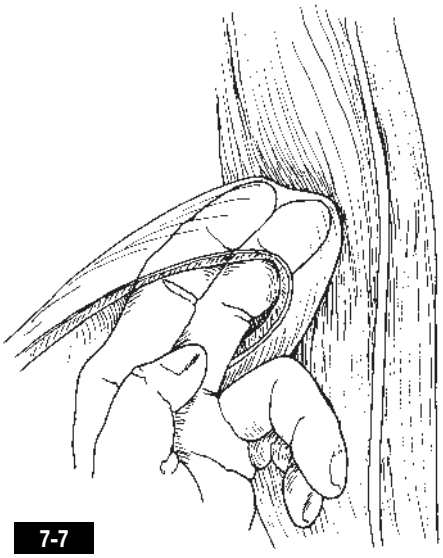

7-7

Psoas Hitch with Ureteral Reimplantation

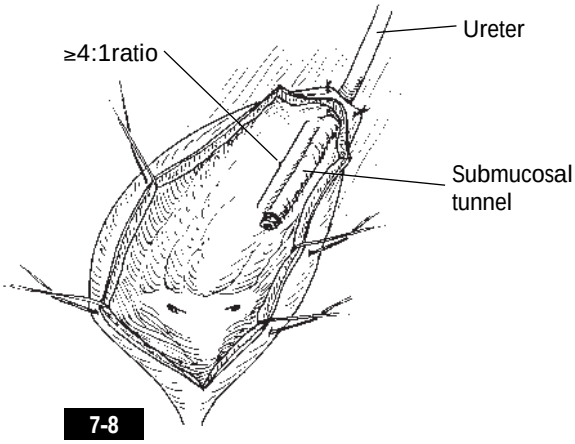

7-8

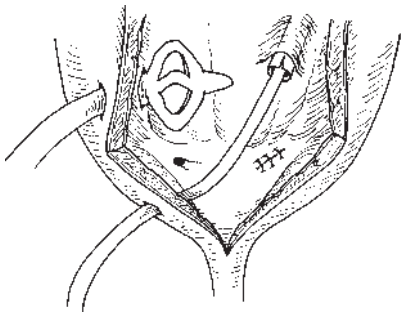

7-9

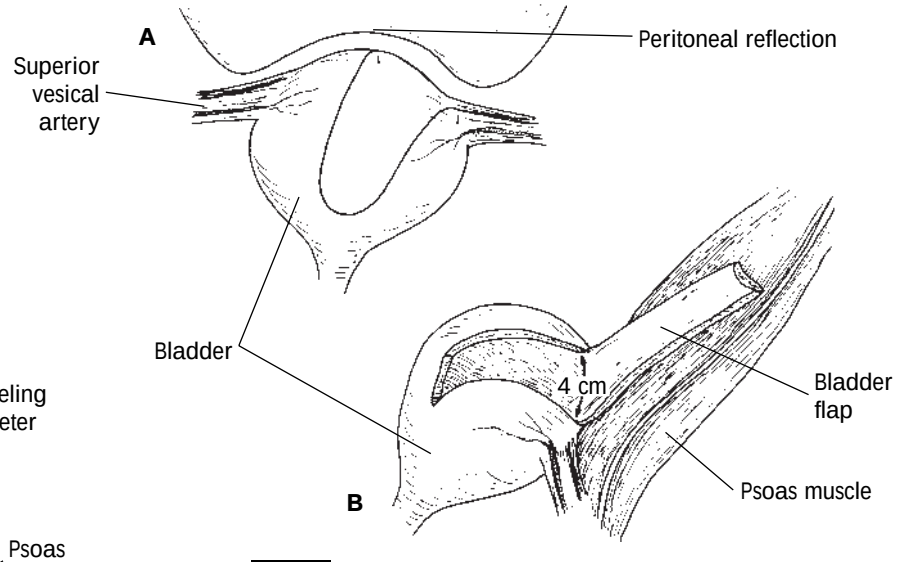

7-10

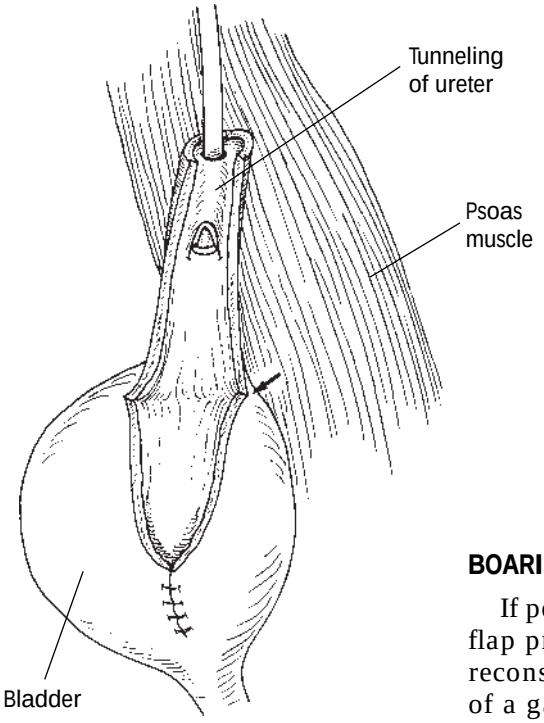

7-11

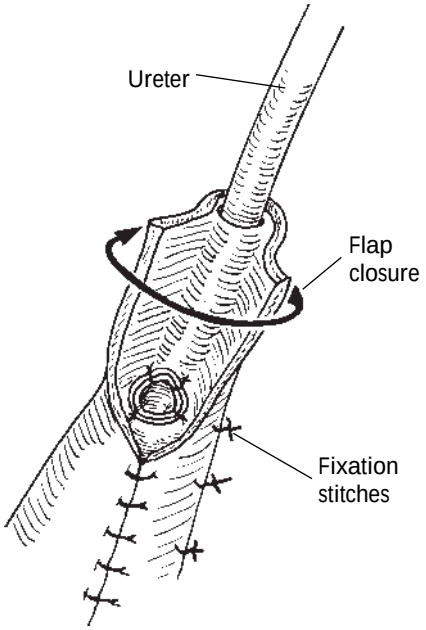

7-12

BOARI FLAP

If performed properly, the Boari flap procedure provides excellent reconstruction for reconstitution of a gap between the ureter and the bladder.

It is a second choice to the psoas hitch procedure because the Boari flap involves more variables that must be overcome for a successful result.[2,3]

The preliminary exposure is identical to the operation for the psoas hitch: isolation of the retroperitoneum and the proximal ureter and clearing of the upper half of the bladder from its peritoneal reflection.

FIG. 7-10. In contrast to the psoas hitch procedure, with the Boari flap the preservation of the superior vesical arteries is important, especially for the ipsilateral side **(A).**

The flap for Boari tubularization must be thought of as a wedge of vesical wall. The longer the flap created, the wider the base must be to maintain good vascularity. The base must be at least 4 cm wide; otherwise the tip of the flap is at risk for ischemia **(B).**

FIG. 7-11. An end-to-end anastomosis between the ureter and the bladder flap will invariably result in a stricture. The importance of a generous overlap of 3 to 4 cm between the ureter and the flap is important for a good reconstruction.

The posterior bladder at the flap base is first fixed with anchoring stitches to the psoas muscle *(arrow).* The surgeon can then perform a tunneling or a Le Duc ureteral reimplantation.[4]

FIG. 7-12. The flap is reapproximated around the ureter, and a stent, suprapubic tube, and drain are placed.

Additional fixation stitches on the Boari flap ensure that no tension is placed on the anastomotic site and that no retraction of the flap occurs.[4]

Combination of Psoas Hitch and Boari Flap

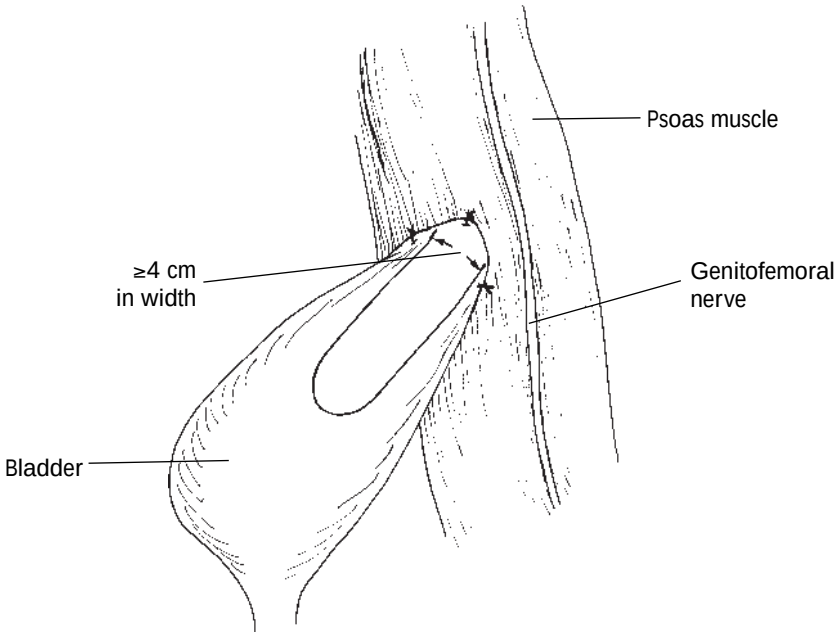

7-13

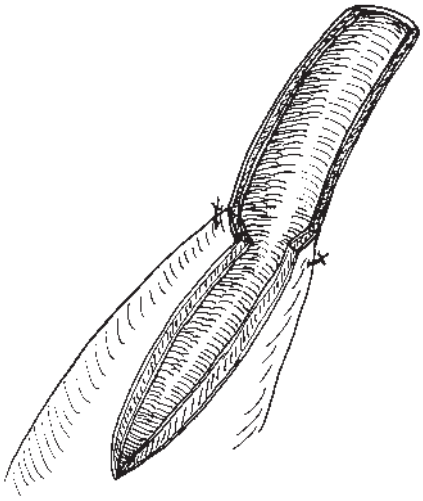

7-14

COMBINATION OF PSOAS HITCH AND BOARI FLAP

FIG. 7-13. If a vesical-psoas fixation has already been completed and the ureter still cannot be overlapped even after mobilizing the kidney and ureter (see pp. 49-50), the surgeon has the option of performing a combined psoas hitch and Boari flap procedure.

FIGS. 7-14 AND 7-15. The combination procedure requires that the base of the Boari flap be 4 cm or greater in width and that the psoas fixation stitches be wider apart than the usual placement.

In this situation we have not used flaps greater than 4 cm in length; the longer the flap, the greater the chance of ischemia and subsequent contracture.

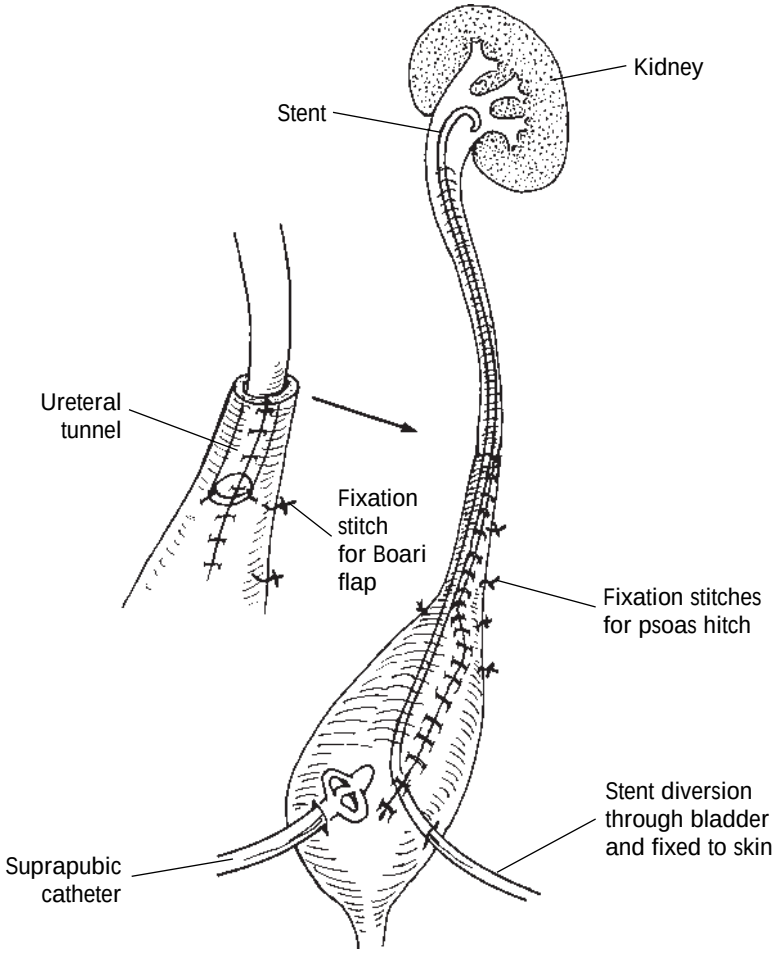

7-15

KEY POINTS

PSOAS HITCH

- The perivesical space is defined and the retroperitoneal pockets are created to isolate the psoas muscle and the proximal ureter.
- The peritoneal reflection is dissected from the bladder.
- If necessary, the contralateral obliterated umbilical artery and even the superior vesical artery are divided for greater maneuverability.
- Bladder wall or dome is bathed in local anesthetic (lidocaine 1%) before a gradual stretch of the bladder wall is performed for the anchoring stitches.
- Vesical-psoas fixation stitches are placed, avoiding the genitofemoral nerve.
- The ureter and the fixed bladder are overlapped by 4 cm.
- Ureteral reimplantation with a tunneling technique or Le Duc procedure is performed.
- Fixation of posterior surface of distal ureter to solid bladder muscle is crucial to prevent reflux.
- A ratio of 4:1 tunnel length to ureteral width for an antirefluxing system is optimal.
- A stent, suprapubic tube, and drain are placed.

BOARI FLAP

- The bladder is filled with saline solution to free the peritoneal reflection.
- Retroperitoneal pockets are created to isolate the proximal ureter and psoas muscle.
- The flap should have a wide base of no less than 4 cm.
- A tunneling or a Le Duc ureteral reimplantation is performed.
- A stent, suprapubic tube, and drain are placed.

POTENTIAL PROBLEMS

PSOAS HITCH

- *Poor maneuverability of superior bladder:* Divide the obliterated umbilical artery and the superior vesical artery bilaterally
- *Genitofemoral nerve at fixation site:* Mobilize the nerve laterally
- *Urethral gap too wide:* Mobilize the kidney and its pedicle to gain 2 to 3 cm (see pp. 49-50) → perform combination Boari flap with psoas hitch → consider transureteroureterostomy

BOARI FLAP

- *Excessive tension when ureter is tunneled into flap:* Fix flap to psoas muscle → mobilize kidney to gain 2 to 3 cm

REFERENCES

1 Middleton RG: Routine use of the psoas hitch in ureteral reimplantation, *J Urol* 123:352, 1980.

2 Turner-Warwick R, Worth PHL: The psoas bladder-hitch procedure for the replacement of the lower third of the ureter, *Br J Urol* 41:701, 1969.

3 Freedman AM, Ehrlich RM, David R: Complications of ureteral surgery. In Smith RB, Ehrlich RM, editors: *Complications of urologic surgery*, ed 2, Philadelphia, 1990, WB Saunders, pp 257-276.

4 Gow JG: *Color atlas of Boari bladder flap procedure*, vol 7, Oradell, NJ, 1983, Medical Economics Books.

SUGGESTED READINGS

Boari A: Quoted by Spies JW, Johnson CE, Wilson CS: *Proc Soc Exp Biol Med* 30:425, 1933.

Conger K, Rouse PV: Ureteroplasty by the bladder flap technique: Report of two cases, *J Urol* 74(4):485, 1955.

Hendren WH: Reoperative ureteral reimplantation: management of the difficult case, *J Pediatr Surg* 15:770, 1980.

Olsson CA, Idelson B: Renal autotransplantation for recurrent renal colic, *J Urol* 123:467, 1990.

USE OF OMENTUM IN UROLOGIC SURGERY

8

FIG. 8-1. The omentum is used as an interposition between two layers of healing tissues. It can cover the entire urinary tract all the way down to the perineum.

The omentum can be placed in areas where there is extracellular fluid collections, where there is excessive dead space, where a barrier is needed to prevent tissue reactions such as in retroperitoneal fibrosis or on suture lines, and where neovascularity is needed to reconstitute organ blood supply.

MOBILIZATION OF OMENTUM

Initially the surgeon must estimate the length of an omental segment needed to cover the desired area. At times the necessary mobilization can be accomplished without taking the omentum off the transverse colon. In the majority of cases, however, the surgeon must perform full mobilization for the desired reconstruction.

Sites for Omental Interposition

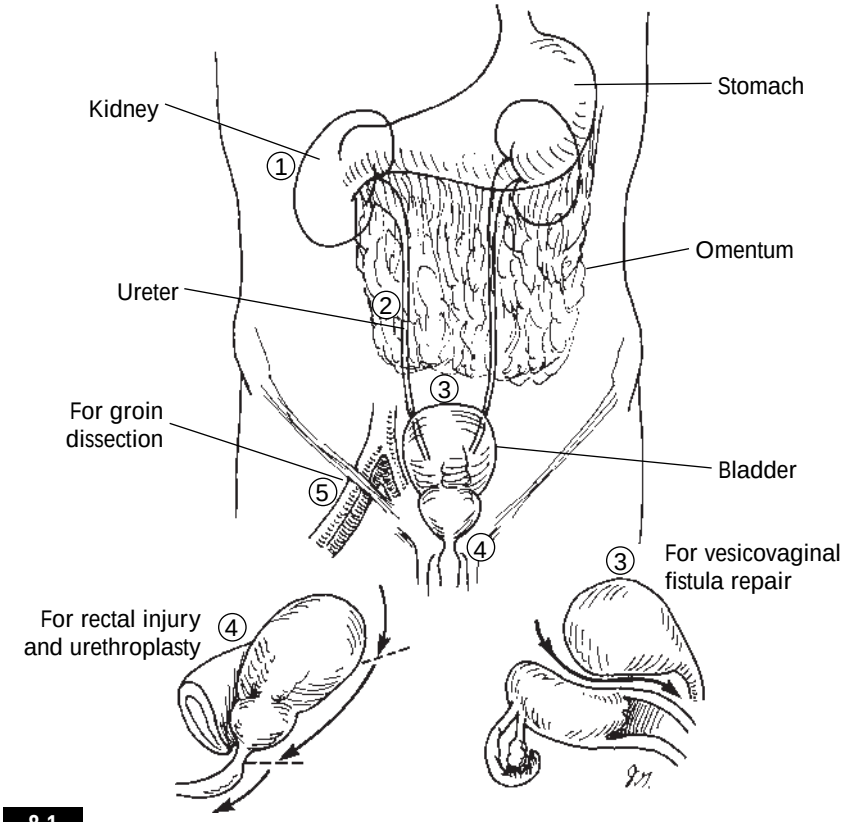

8-1

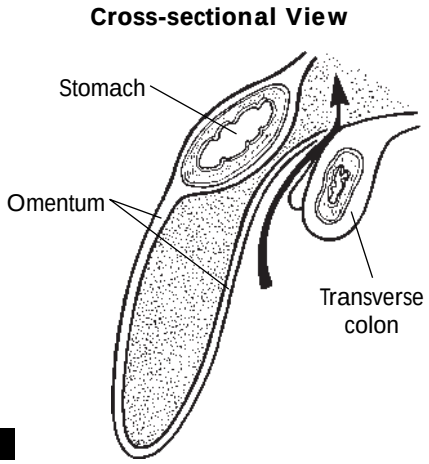

8-2

DISSECTION OF OMENTUM FROM TRANSVERSE COLON

FIGS. 8-2 AND 8-3. By lifting the entire omentum cephalad, the surgeon finds an avascular plane between the left omentum and the left transverse colon.

FIG. 8-4. Once started, the surgeon can pass the index and middle fingers between the anterior surface of the pancreas and the omentum. The dissection proceeds from the left to the right.

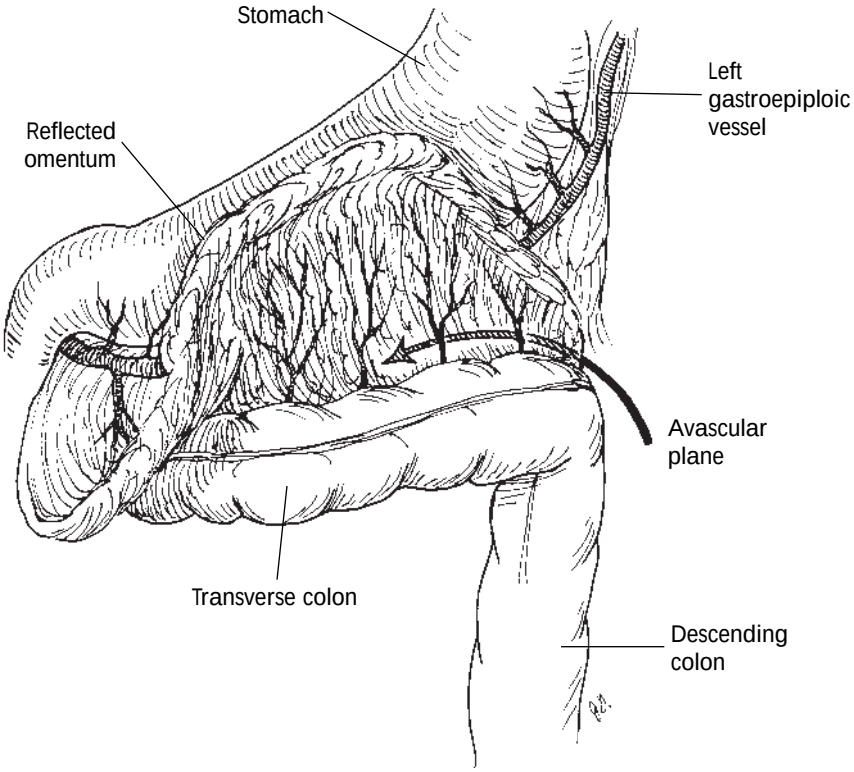

8-3

DISSECTION OF OMENTUM FROM STOMACH

FIG. 8-5. When dissecting the omentum from the stomach, the surgeon must preserve the omental vasculature. The blood supply to the omentum consists of the right and left gastroepiploic vessels, which course toward one another to form the gastroepiploic arch. The black line shows the route by which the omentum can be divided without injury to the vascular arch.

FIG. 8-6. In approximately 10% of patients, however, the right and left gastroepiploic arteries do not anastomose to form this arch[1-3] (*arrow* in **A**). Often the right gastroepiploic artery vascularizes more than two thirds of the omental apron **(B).** Although we have used both the left and the right gastroepiploic arteries, mobilization based on the left gastroepiploic pedicle may result in ischemia if the gastroepiploic arch is incomplete. In general, the right gastroepiploic artery is preferred as the pedicle.

The omentum should never be divided across the omental apron below the gastroepiploic arch because such an incision would divide the vertical branches and further compromise the already poor arcade communication **(C** and **D).**

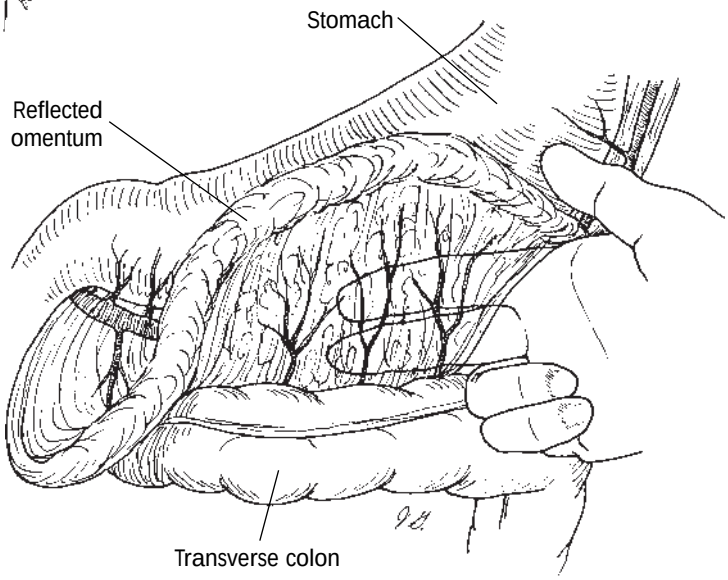

8-4

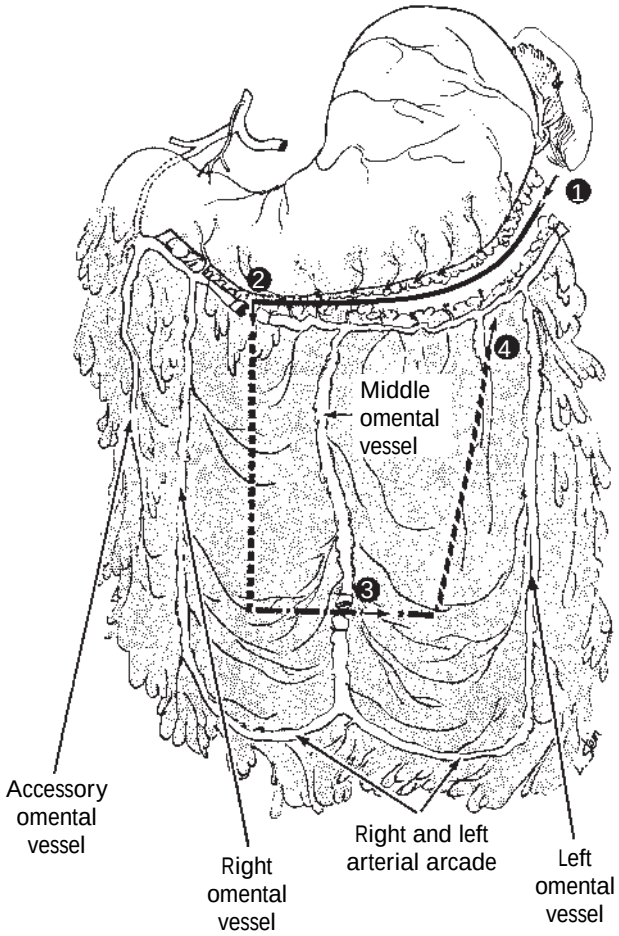

From Alday ES, Goldsmith HS: *Surg Gynecol Obstet* 135:103, 1972.

8-5

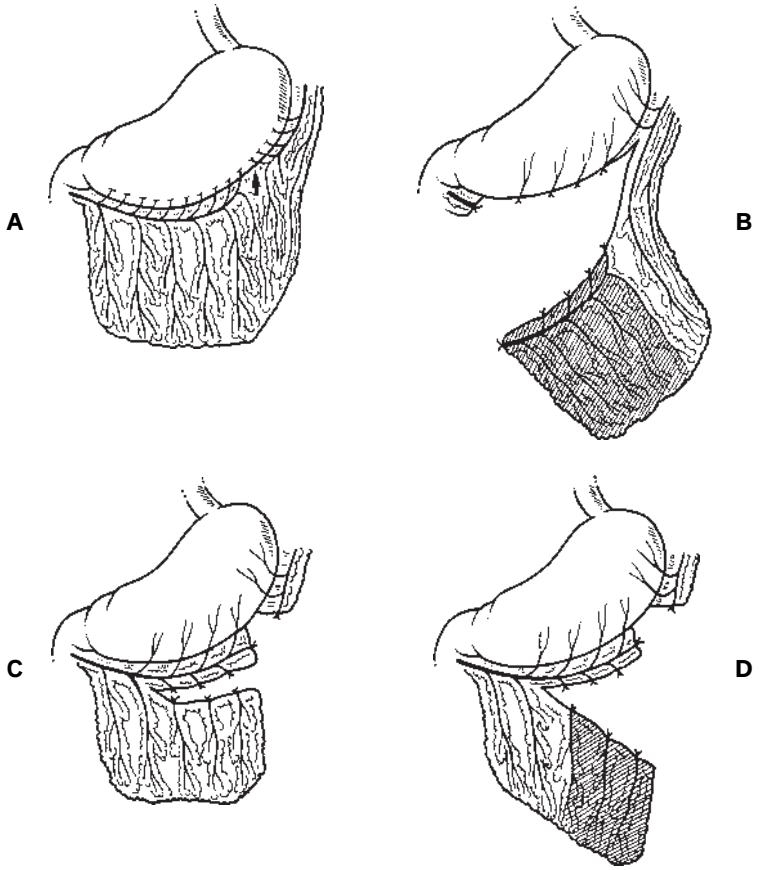

From Webster G et al: *Reconstructive urology,* London, 1993, Blackwell.

8-6

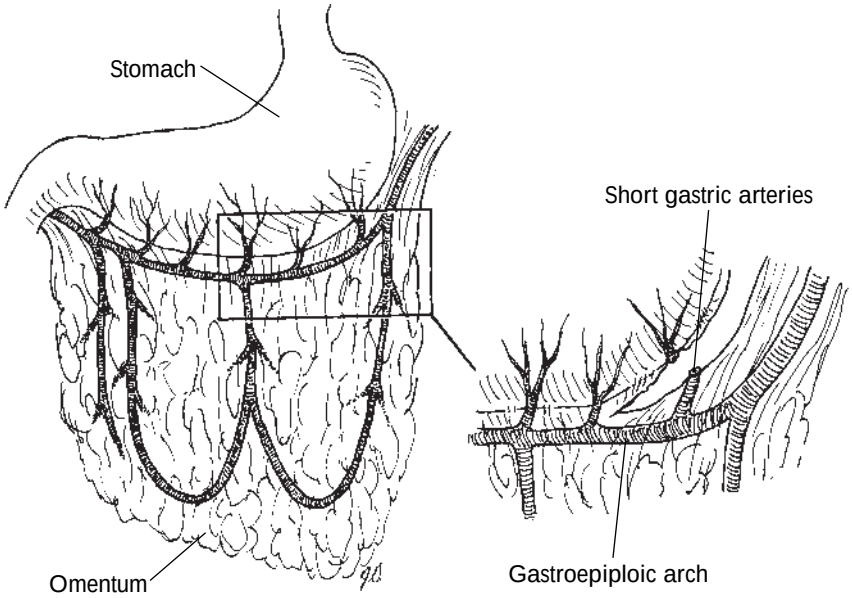

8-7

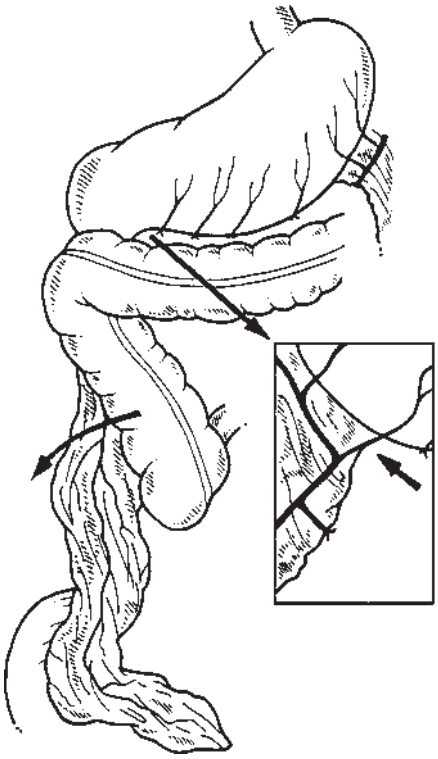

From Webster G et al: *Reconstructive urology,* London, 1993, Blackwell.

8-8

FIG. 8-7. After dividing either one of the gastroepiploic arteries, the surgeon divides the short gastric arteries to free the omentum from the stomach. It is important to divide the short gastric arteries *favoring the stomach side* to preserve the vascular arcade of the omentum.

FIG. 8-8. Mobilization of the right gastroepiploic vessel from the stomach should be extended to its gastroduodenal origin to avoid placing excessive tension on the pedicle and rupturing the last undivided branch.

Although it is tedious, the surgeon must take every precaution to avoid any small arterial bleeding within the omentum because such bleeding could lead to a large hematoma. Not only can the arcade be injured but also the surgeon will have difficulty assessing the viability of the mobilized omentum. We prefer to perform this maneuver using manual tying and hemostat clamps instead of the LDS stapler (Autosuture, U.S. Surgical, Norwalk, Conn.) going from the left short gastric arteries to the right. In this way, if there is an injury to the vascular arcade, the right side is still preserved for use.

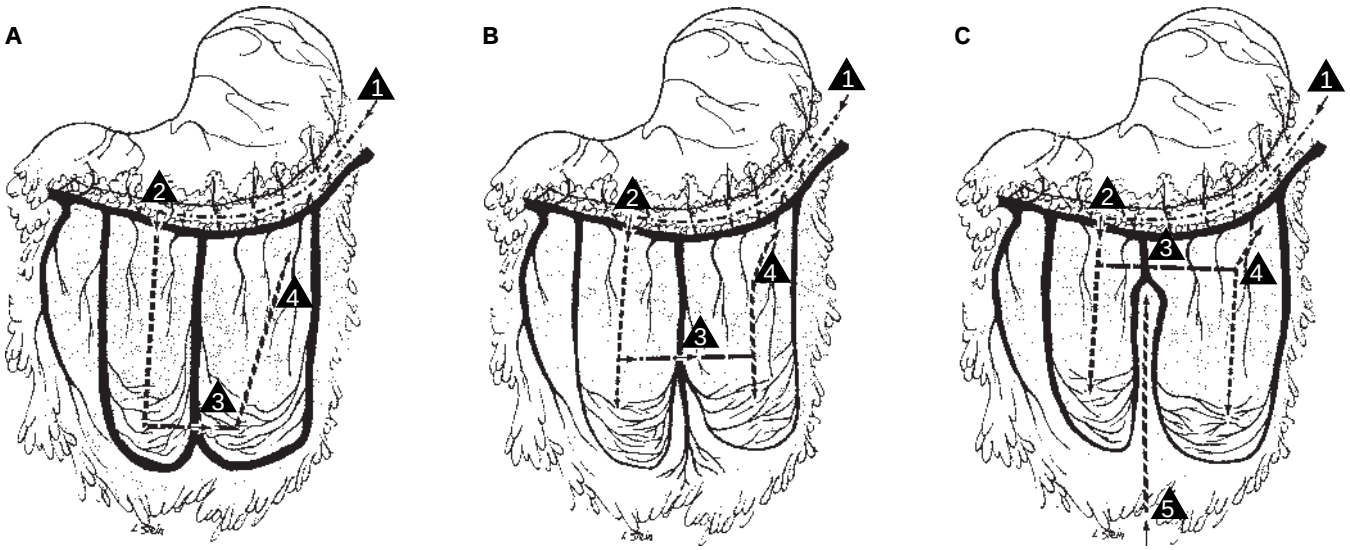

From Alday ES, Goldsmith HS: *Surg Gynecol Obstet* 135:103, 1972.

8-9

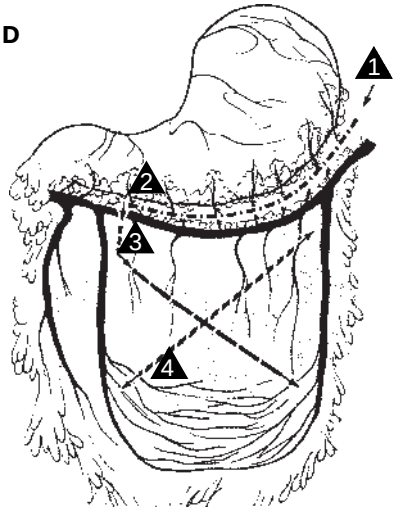

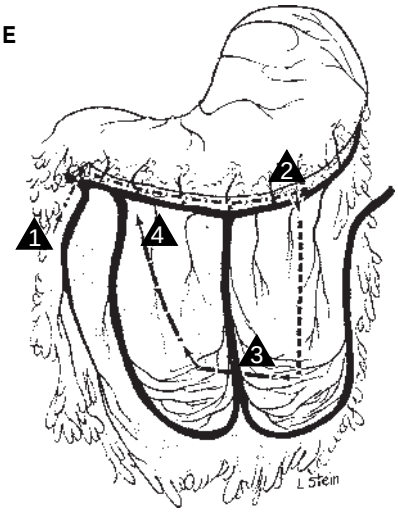

VARIATIONS IN OMENTAL VASCULATURE

As has been discussed, there are variations in omental vasculature, thus requiring a unique dissection for each patient. By shining a light source from behind the omentum (transluminations) in a darkened room, the surgeon will be able to define each variation.

FIG. 8-9. In general, there are four branches from the vascular arcade, which join at the distal portion of the omentum. These branches join the right and left omental arteries, thus forming right and left arterial arcades. Alday and Goldsmith[4] and Kiricuta and Goldstein[5] have noted *five* major variations of these arcades, which are based on the level of bifurcation or the absence of the middle omental artery. The dashed lines and numbers represent the steps in the omental mobilization procedure.

Type 1: The middle omental artery bifurcates near the lower end of the omental apron **(A).** This vascular pattern is the *most common.*

Type 2: The middle omental artery bifurcates or trifurcates midway between the gastroepiploic arch and the lower end of the omental apron **(B).**

Type 3: The middle omental artery bifurcates or trifurcates 2 to 3 cm from gastroepiploic arch **(C).**

Type 4: The right and left omental arteries join to form an omental vascular arch without the presence of the middle omental artery **(D).**

Type 5: The terminal branch of the splenic artery is not part of the gastroepiploic arch but instead develops into the left omental artery **(E).** The right gastroepiploic artery diminishes in caliber as it traverses the lower portion of the greater curvature of the stomach and never develops communication with the short gastric vessels. The middle omental artery arises from the right gastroepiploic artery.

PLACEMENT AND FIXATION OF OMENTAL PEDICLE

FIG. 8-10. The simplest maneuver is to divide the line of Toldt and reflect the colon medially while fixing the omentum to the retroperitoneal space.

The surgeon should check that the gastroepiploic artery is not under tension or at a severe angle to the rest of the omental apron.

By mobilizing either the left or right omentum, the surgeon can reach the area of the kidney, adrenal gland, and ureter. If a longer segment of omentum is needed, it is best to use the right gastroepiploic artery as the pedicle because of its lower position.

If the omentum is placed within the peritoneal cavity to cover a reconstructed bladder such as a continent pouch, the surgeon must take precautions to fix the omentum in such a way that no bowel herniations are possible.

FIG. 8-11. With the omentum already in a retroperitoneal position, it is relatively simple to interpose it over the entire urinary tract from the kidney to the ureter and down to the bladder. There are situations in which the ureter may need to be mobilized and freed first before a tension-free omental wrap or interposition is possible.[6]

FIG. 8-12. For vesicovaginal fistula repairs, the surgeon can incise the peritoneum and develop a dissection plane between the bladder and the anterior vagina for the omental fixation.

For inadvertent rectal lacerations during radical prostatectomies, the cul-de-sac is incised and the omentum is fixed over the rectal repair (see p. 267).

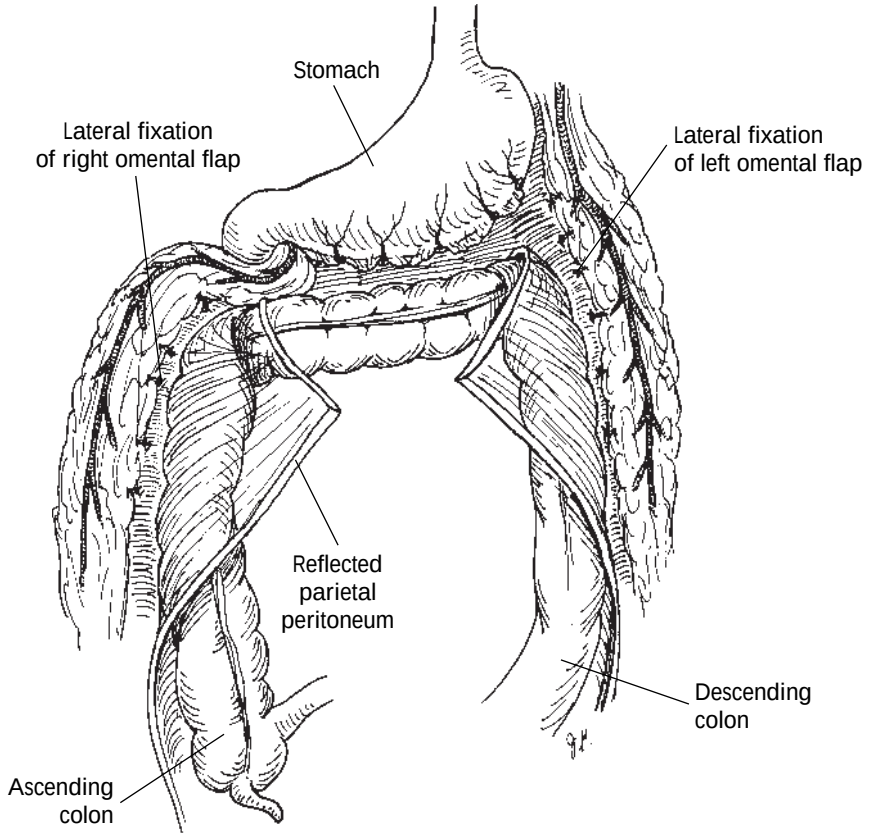

8-10

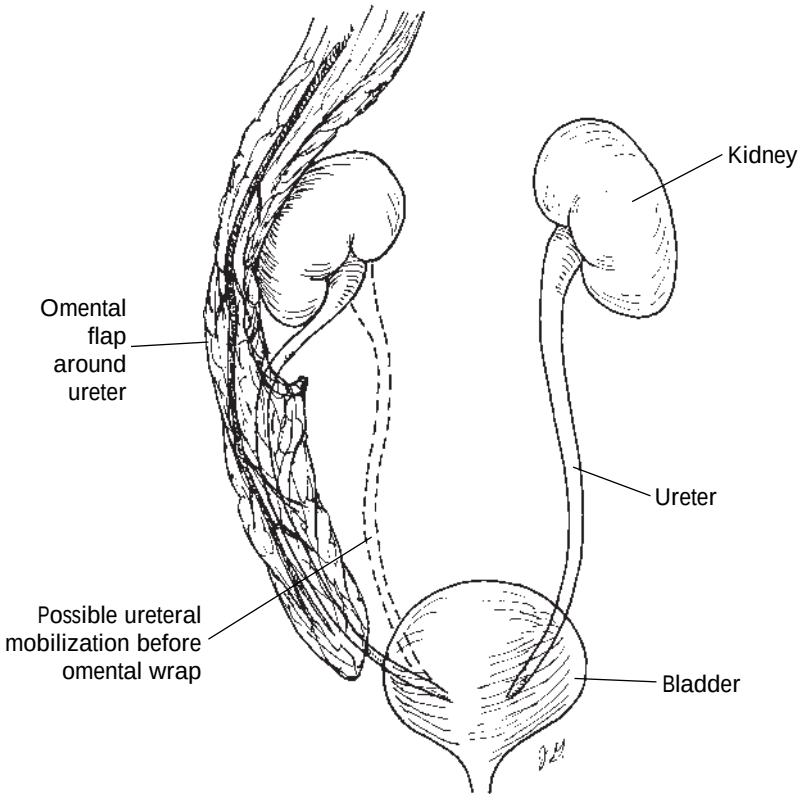
Kidney
Omental flap around ureter
Ureter
Possible ureteral mobilization before omental wrap
Bladder

8-11

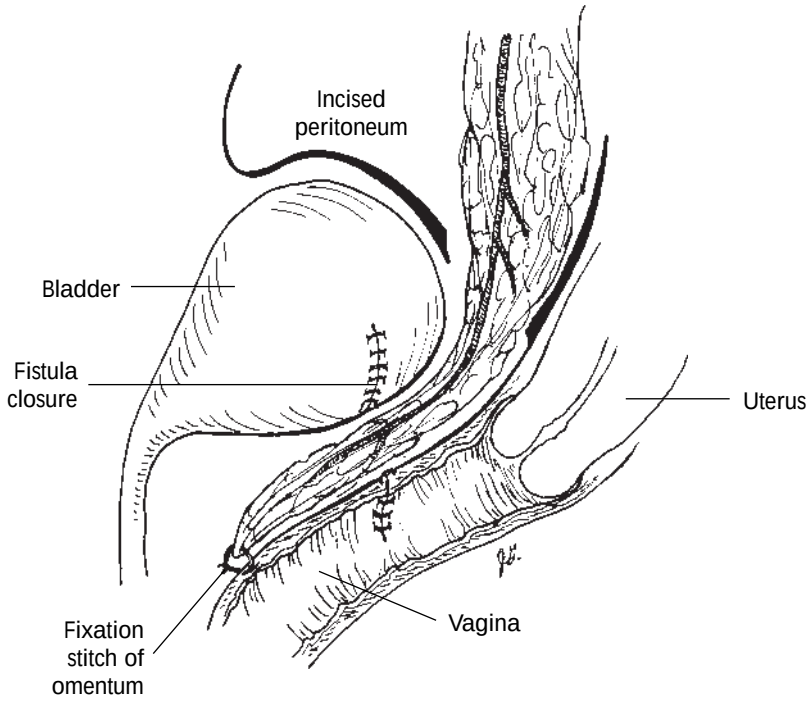
Incised peritoneum
Bladder
Fistula closure
Uterus
Vagina
Fixation stitch of omentum

8-12

FIG. 8-13. For posterior urethroplasties, the surgeon can use a similar dissection by incising the peritoneal cul-de-sac and developing a dissection plane between the bladder/prostate gland and the rectum as is done in a radical cystectomy procedure (see p. 268).

As an alternative, the surgeon can develop a space from the retroperitoneum and then under the "retroperitoneal pockets" into the retropubic spaces (see pp. 69 and 170).

If there is a need to cover a raw area after a groin dissection, the surgeon may tunnel the omentum over the inguinal ligament but within the subcutaneous tissue to reach the groin.

Omental Interposition at Partial Pubectomy Site for Urethroplasty Repair and After Rectal Injury

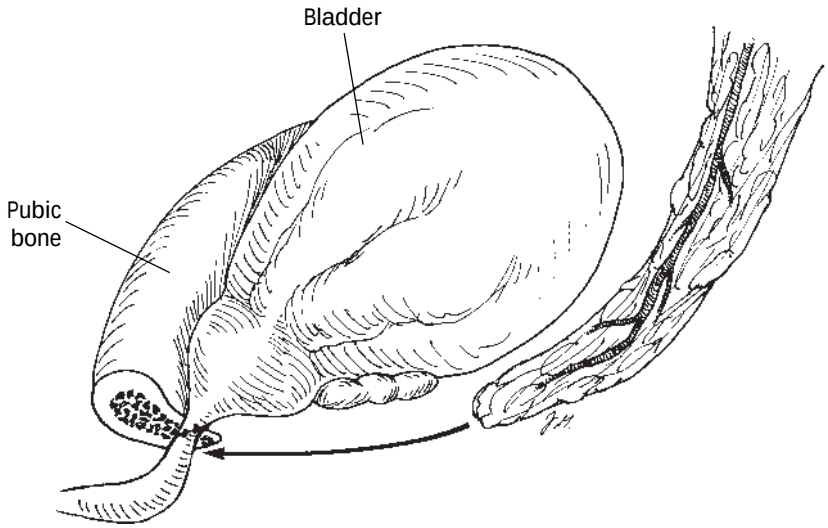

8-13

KEY POINTS

- The omental length needed is estimated. There are situations in which the omentum can easily stretch to the area concerned without further mobilization, such as when used as cover for a continent pouch.
- All possibilities and potentials of bowel entrapment and subsequent bowel obstruction must be considered when the omentum is fixed to a desired region.
- The omentum is mobilized from the stomach and transverse colon.
- The omental vascular arcade must be preserved on the omentum side. The left short gastric arteries are divided first and then the right side is approached.
- The right gastroepiploic artery is preferred over the left gastroepiploic artery for use as the vascular pedicle. There should be no tension on the pedicle.
- The lateral colon is mobilized for fixation of the omental pedicle in the retroperitoneal space.
- The various omental lengthening maneuvers are considered.
- The omentum can be mobilized to wrap around the ureter from the kidney to the lower end of the ureter.
- For vesicovaginal fistulas, the surgeon can place the omentum from the intraperitoneal position by developing a dissection plane through the peritoneum and between the bladder and vagina.
- For vesicorectal fistulas or difficult membranous urethroplasty repairs, the surgeon can use an intraperitoneal approach by developing a dissection plane through the peritoneal cul-de-sac between the rectum and the vagina or the rectum and the bladder/prostate gland.

POTENTIAL PROBLEMS

- *Mobilization of omentum from stomach leads to hematoma*: Apply finger compression to the area → inspect for and ligate bleeders to prevent larger hematoma
- *Mobilization of omentum with injury of its vascular arcade:* Wait and inspect the omentum later → use the right gastroepiploic artery as the main pedicle if at all possible → transluminate the omentum to select the best alternative
- *After omental fixation, there is possible risk of bowel herniation and future bowel obstruction:* Place and fix the omentum in a lateral position or even in a retroperitoneal position

REFERENCES

1 Turner-Warwick R, Wynne JC, Handley-Asken M: The use of the omental pedicle graft in the repair and reconstruction of the urinary tract, *Br J Urol* 54(10):849, 1967.

2 Turner-Warwick R: The use of omental pedicle graft in urinary tract reconstruction, *J Urol* 116:341-347, 1976.

3 Turner-Warwick R: Principles of sphincteroplasty. In Webster G et al, editors: *Reconstructive urology*, vol 2, Philadelphia, 1987, JB Lippincott.

4 Alday ES, Goldsmith HS: Surgical technique for omental lengthening based on arterial anatomy, *Surg Gynecol Obstet* 135:103, 1976.

5 Kiricuta I, Goldstein AMB: The repair of extensive vesicovaginal fistulas with pedicled omentum: a review of 27 cases, *J Urol* 108:724, 1972.

6 Tresidder GC, Blandy JP, Singh M: Omental sleeve to prevent recurrent retroperitoneal fibrosis around the ureter, *Current operative urology* ed 2, Philadelphia, 1983, Harper & Row.

SUGGESTED READINGS

Bunkis J, Walton RL: The rectus abdominis flap for groin defects. In Strauch B, Vasconez L, Hall-Findlay EJ, editors: *Grabbs encyclopedia of flaps*, vol 3, Boston, 1990, Little, Brown.

Powers JC, Fitzgerald JF, McAlvanah MJ: The anatomic basis for the surgical detachment of the greater omentum from the transverse colon, *Surg Gynecol Obstet* 143:105, 1976.

Routledge RT, Das SK: Omental flap. In Strauch B, Vasconez LO, Hall-Findlay EJ, editors: *Grabbs encyclopedia of flaps*, vol 3, Boston, 1990, Little, Brown, pp 1269-1272.

Samson RH: Omental flap for coverage of exposed groin vessels. In Strauch B, Vasconez LO, Hall-Findlay EJ, editors: *Grabbs encyclopedia of flaps* vol 3, Boston, 1990, Little, Brown, pp 1404-1407.

Samson R, Pasternak BM: Current status of surgery of the omentum, *Surg Gynecol Obstet* 149:437, 1979.

Stahl RS, Jurkiewicz MJ: Omental flap. In Strauch B, Vasconez LO, Hall-Findlay EJ, editors: *Grabbs encyclopedia of flaps* vol 3, Boston, 1990, Little, Brown, pp 1361-1366.

Trede M: Approaches to the pancreas and abdominal exploration. In Trede M, Carter DC, editors: *Surgery of the pancreas*, London, 1993, Churchill Livingstone, pp 141-145.

RADICAL CYSTECTOMY IN THE MALE

9

EXPOSURE

FIGS. 9-1 AND 9-2. The midline incision should incorporate the dissection of the urachus from the umbilicus.

FIG. 9-3. Proper bowel mobilization and packing for good exposure are essential in this operation. The lines of Toldt lateral to the colon are divided on both sides. On the *right side*, this incision extends around the cecum up to the mesenteric root toward the ligament of Treitz. On the *left side*, the descending colon and the sigmoid colon are mobilized, and a tunnel behind the sigmoid colon is immediately created with blunt dissection in preparation for the left ureteral mobilization to the right side.

Both ureters should be isolated with vessel loops.

Three dry laparotomy pads—one on each gutter *(1* and *2)* and one in the middle *(3)*—cover the bowel, and this in turn is covered by a dry towel *(4)*. The dry towel is "unrolled" down over the three laparotomy pads and tucked up to each lateral gutter to prevent the bowel from slipping into the operative field.

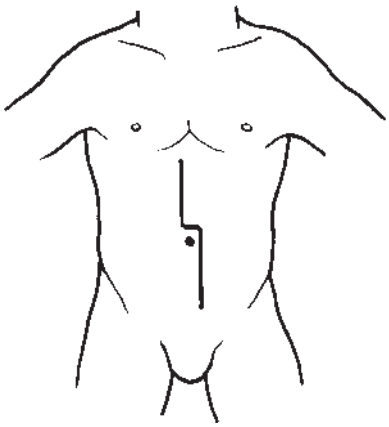

9-1

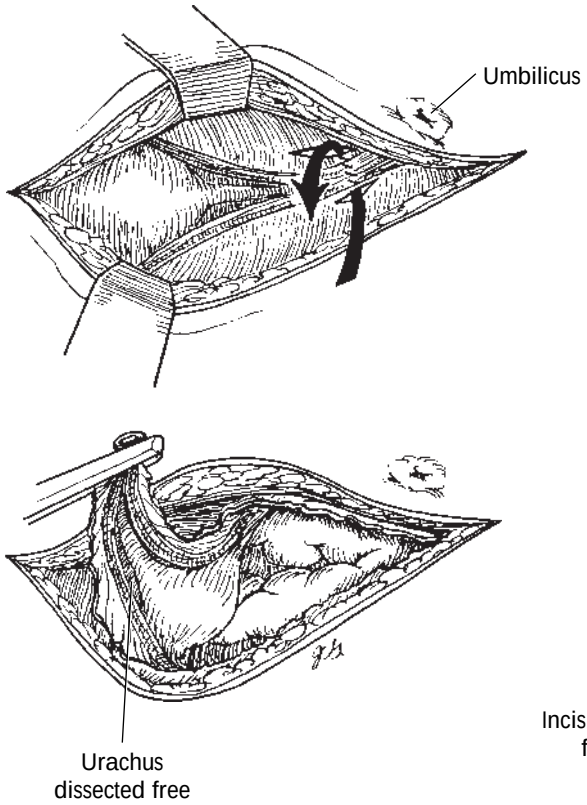

9-2

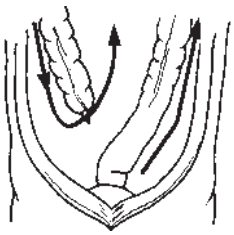

Incision of parietal peritoneum
for bowel mobilization

9-3

Laparotomy Pads and Towel Packing of Bowel

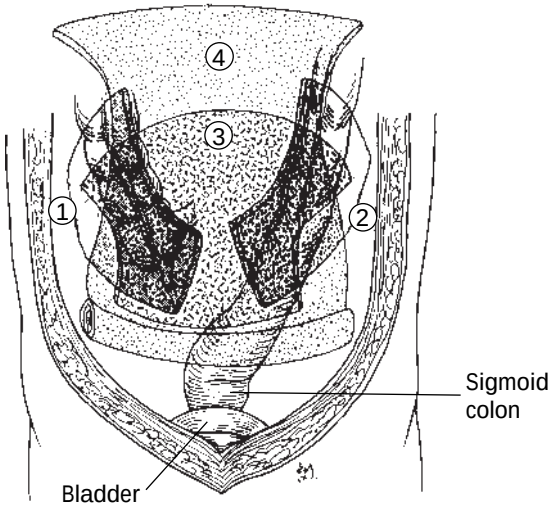

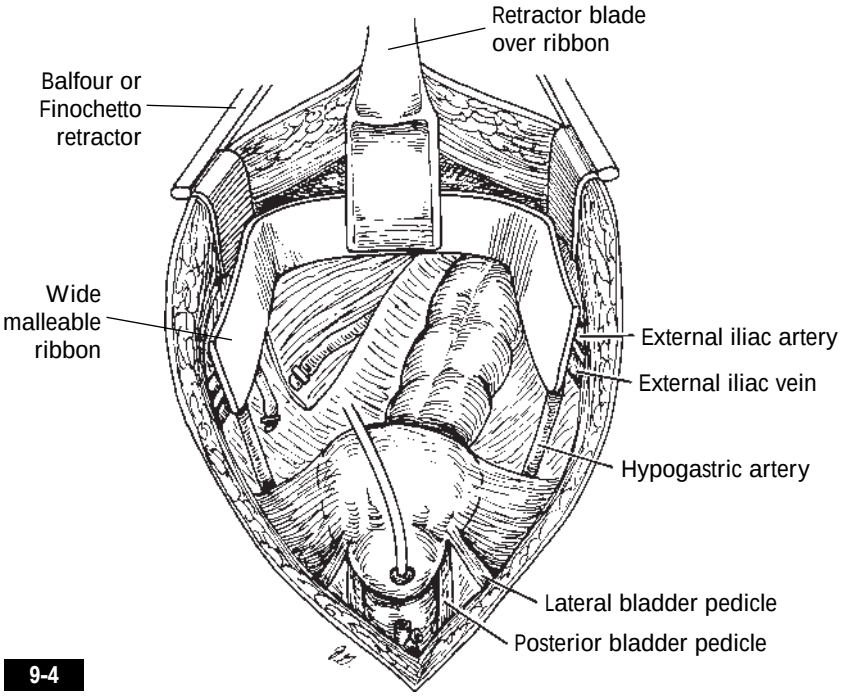

9-4

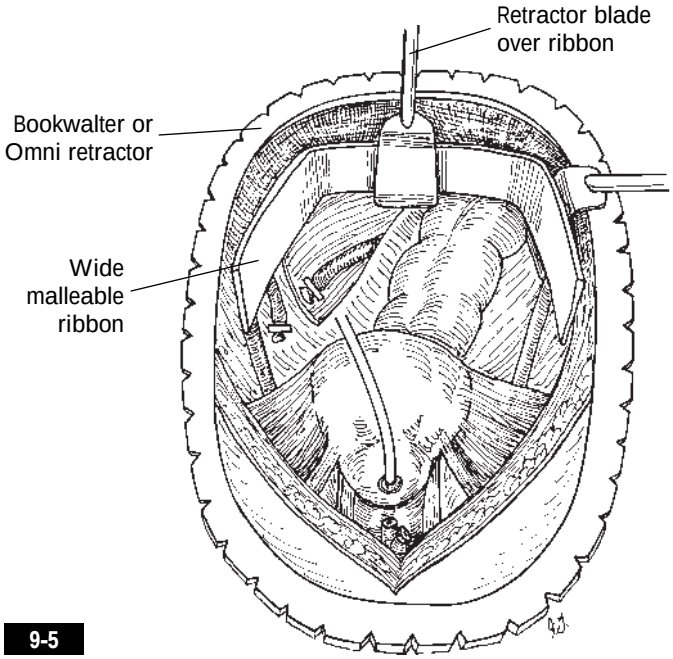

9-5

FIGS. 9-4, 9-5, AND 9-6. With a large Bookwalter, Balfour Grieshe, Finochetto, or Omni retractor in place, the surgeon can place a wide, malleable ribbon in the shape of a half-rectangle or semicircle configuration into the operative field to keep the bowel packing cephalad. The illustrations show a later stage of the operation, but the exposure, in which the ribbon with the retractor is incorporated, facilitates the entire pelvic dissection.

After the lymphadenectomy, the ureters are divided and clipped at the proximal opening. This maneuver permits the ureters to dilate, facilitating the ureterointestinal anastomosis. Frozen section biopsy of the distal ureters is performed to determine cancer involvement.

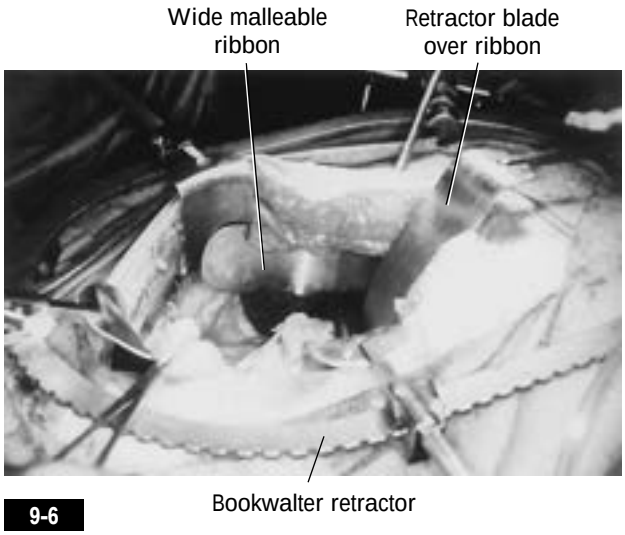

9-6

PROXIMAL POSTERIOR DISSECTION AFTER LYMPHADENECTOMY AND URETERAL DIVISION

FIG. 9-7. We prefer first to divide the posterior peritoneum (cul-de-sac) and establish the dissection plane between the rectum and the bladder before dividing the four pedicles. It is critical to incise the peritoneal reflection at the cul-de-sac on the rectal side rather than on the bladder side. This ensures that a proper dissection plane is established between the rectum on one side and the bladder, prostate gland, and Denonvilliers' fascia on the other side *(arrow)*.

After dividing the peritoneum, the surgeon uses blunt dissection to establish a definite space between the prostate/bladder and the rectum. The surgeon should be able to palpate the Foley catheter balloon inside the bladder.

FIGS. 9-8 AND 9-9. By performing this dissection, the surgeon can now identify the lateral (*1* and *2* in Fig. 9-8) and posterior (*3* and *4* in Fig. 9-8) bladder pedicles on both sides.

The neurovascular bundles for potency are located in the posterior pedicles at the level of the seminal vesicles (*dots* on posterior pedicles in Fig. 9-8). The Foley catheter balloon is palpated at the same level.[1]

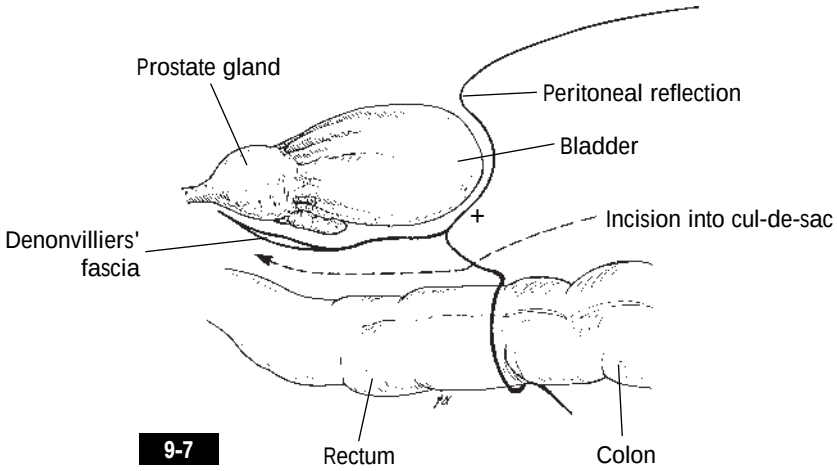

9-7

Top View

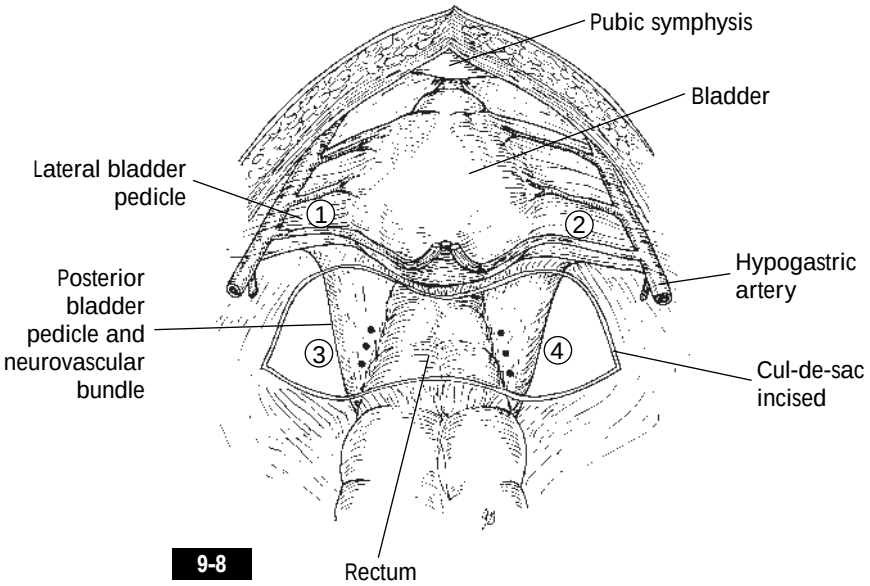

9-8

Frontal View **Oblique View**

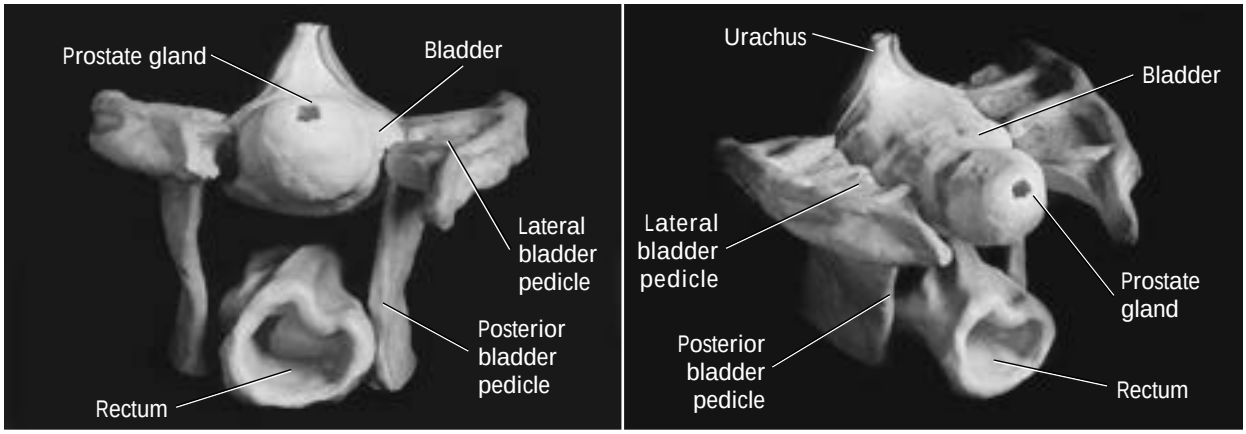

9-9

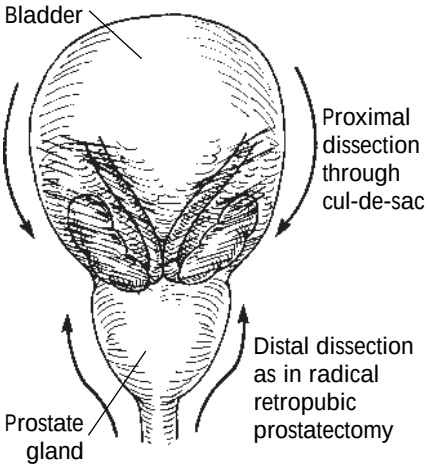

9-10

DISTAL/ANTERIOR DISSECTION

FIG. 9-10. The surgeon focuses now on the distal/anterior end at the prostatic apex and performs the same maneuvers as in radical retropubic prostatectomy (see p. 170).[2]

FIGS. 9-11 AND 9-12. The surgeon opens the endopelvic fascia bilaterally, divides the puboprostatic ligaments if wide, and then ligates and divides the dorsal venous complex. Alternatively, the surgeon can incorporate a tie (1-0 Vicryl) around the dorsal venous complex and the puboprostatic ligaments as one unit and divide the structures proximal to the tie (see p. 178).

The urethra is isolated and two ties (0 silk) are placed, securing the urethra to the Foley catheter proximally. The urethra and Foley catheter are divided distal to the ties. Urethrectomy is performed simultaneously from below or postponed.

The free end of the cut Foley catheter is retracted up, thereby retracting the prostate gland cephalad and exposing Denonvilliers' fascia and the seminal vesicles beneath. The lateral prostatic pedicles should be divided.

FIG. 9-13. Using both hands, the surgeon can now feel a thin web of tissues separating the proximal and distal dissections. This thin web is punctured with the surgeon's fingers. It is important to puncture the thin layer of tissues *closest* to the prostate gland and bladder side to avoid injury to the rectum (see p. 268).

The surgeon can now lift the prostate gland and bladder, defining the bladder pedicles for division.

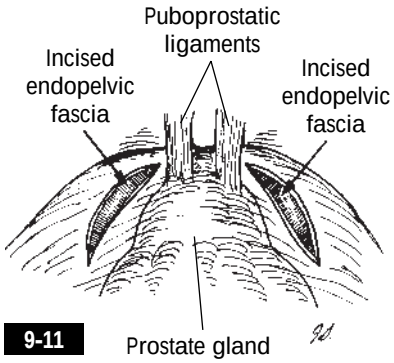

9-11

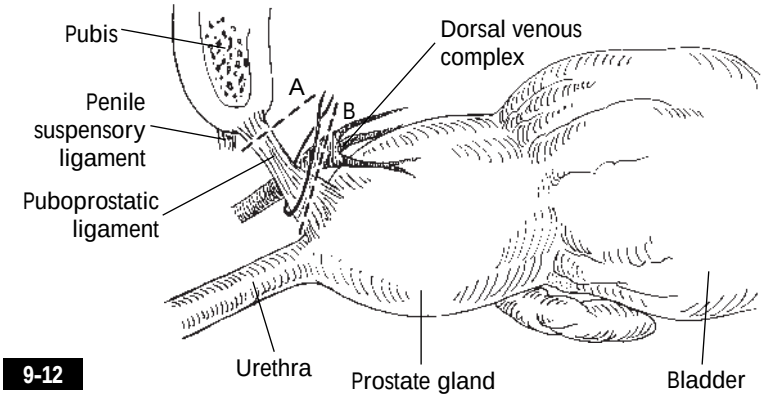

9-12

Lateral View

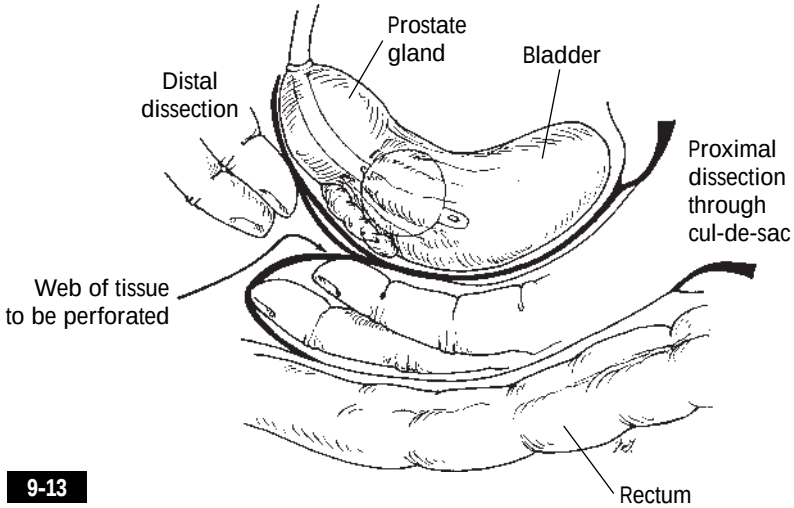

9-13

TRADITIONAL DIVISION OF LATERAL AND POSTERIOR BLADDER PEDICLES

The right-handed surgeon is positioned at the patient's left side for the entire operation.

FIG. 9-14. Using the left hand to hold the bladder and rectum medially, the surgeon can slide the index finger and middle finger adjacent to the right hypogastric artery. Both the index finger and the middle finger pull the bladder and rectum medially, thereby exposing the right lateral pedicle. If the lateral pedicle is thick and fatty, the surgeon can use a finger-pinching maneuver whereby the thumb compresses the fatty tissue against the index and middle fingers to "thin out" the pedicle for easier ligation and division.

If not concerned with potency, the surgeon can ligate the entire hypogastric artery distal to the superior gluteal artery. If the goal is to preserve potency and the tumor does not invade the lateral walls of the bladder, the surgeon can divide the obliterated umbilical artery and the vesical arteries and preserve the main hypogastric artery.

FIG. 9-15. Optimal clipping means the placement of two clips 1 cm apart on the proximal end, with a 1 cm margin on the free end to avoid clip slippage. The surgeon uses the left hand to mobilize the bladder and rectum medially while using the right-angle clip applier to ligate the right lateral bladder pedicle.

Division of Lateral Bladder Pedicle

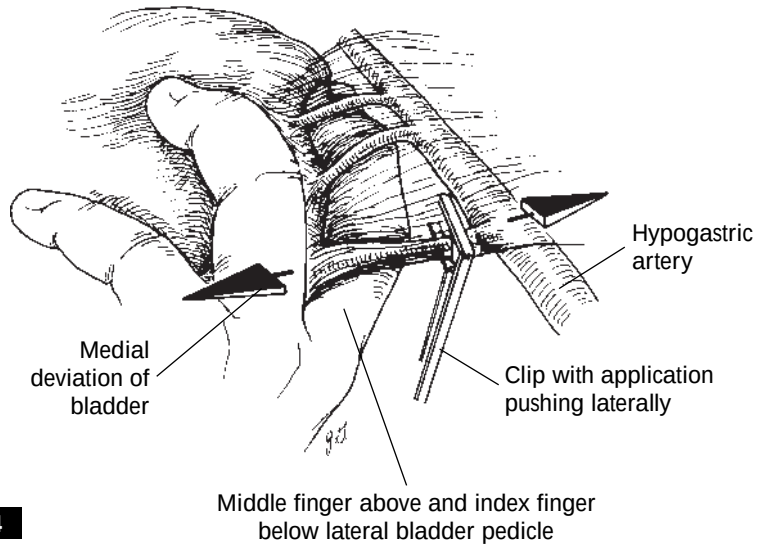

9-14

1 cm Rule with Two Clips on Proximal Side

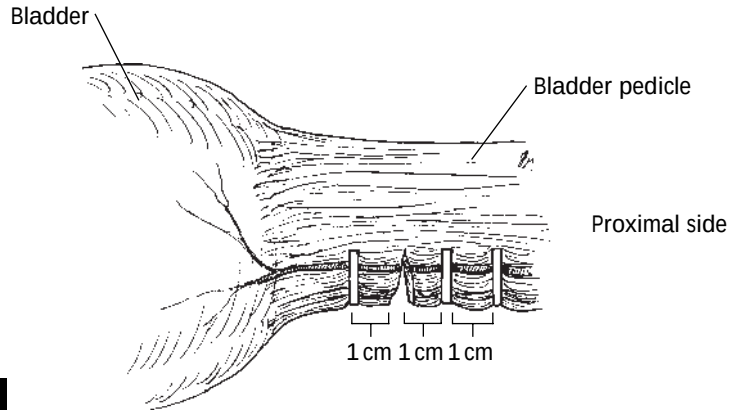

9-15

Haney or Ballantine Clamp

A

B

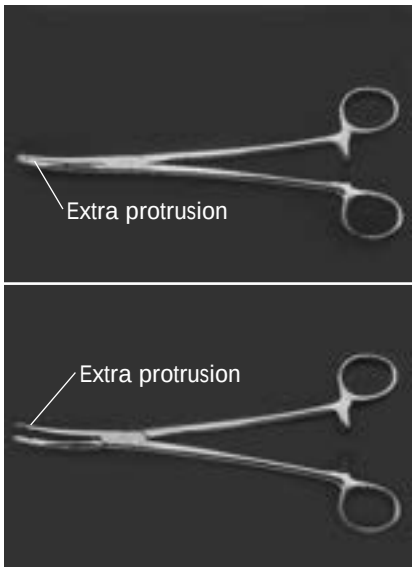

Tip of Haney or Ballantine Clamp

C

D

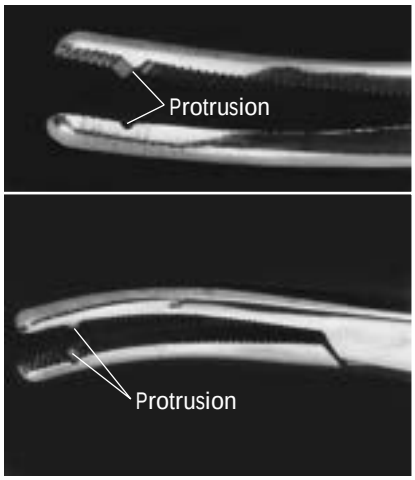

9-16

Jaws of Haney Clamp

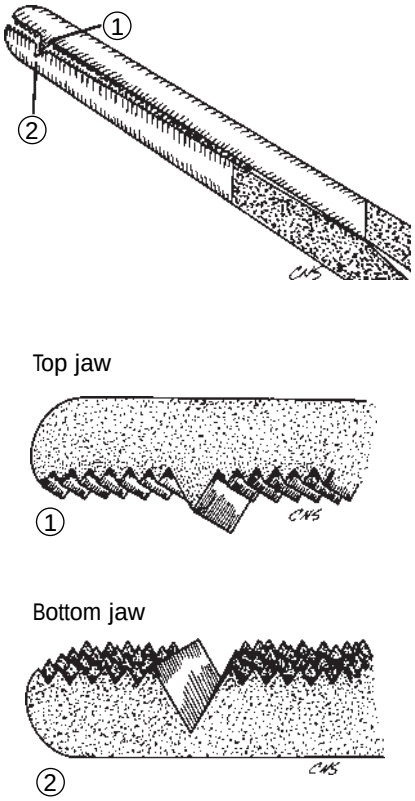

9-17

FIGS. 9-16, 9-17, AND 9-18. If the anatomic pelvis is narrow and the tumor is large with minimal space for maneuverability, the surgeon can use Haney or Ballantine clamps for pedicle division. These clamps can incorporate thick pedicles and have a tooth in the middle to prevent slippage. A pulley stitch (0 silk) can be used to ligate the divided pedicles.

Using the same technique, the surgeon divides the posterior pedicles after lateral pedicle division is completed.

FIGS. 9-19, 9-20, AND 9-21. The posterior bladder pedicles should be divided as close as possible to the bladder side to preserve the neurovascular bundles. Note the position of the neurovascular bundles in relation to the seminal vesicles.

Use of Haney or Ballantine Clamp for Pedicle Division

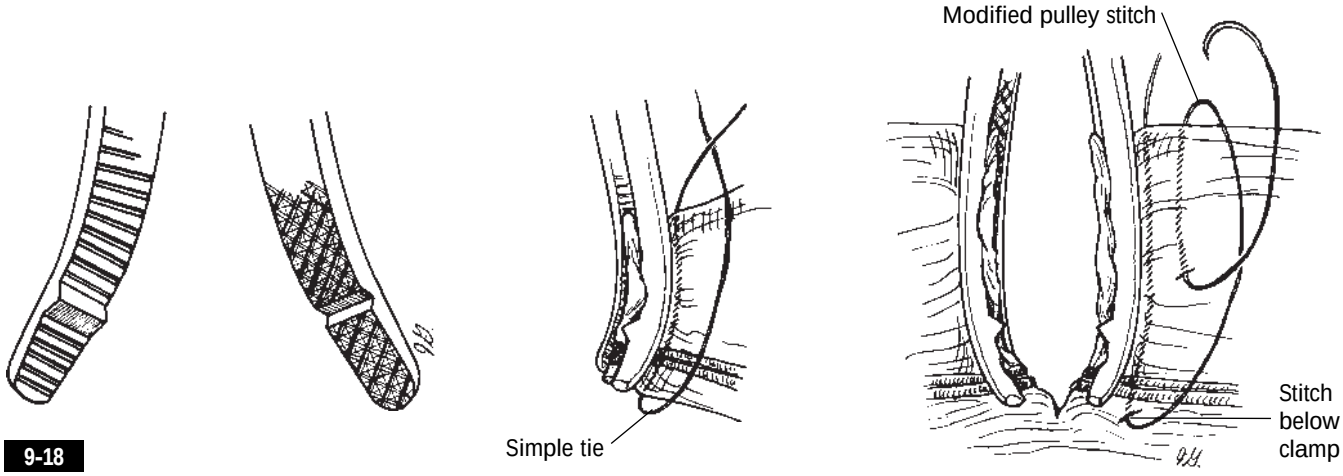

9-18

Top View

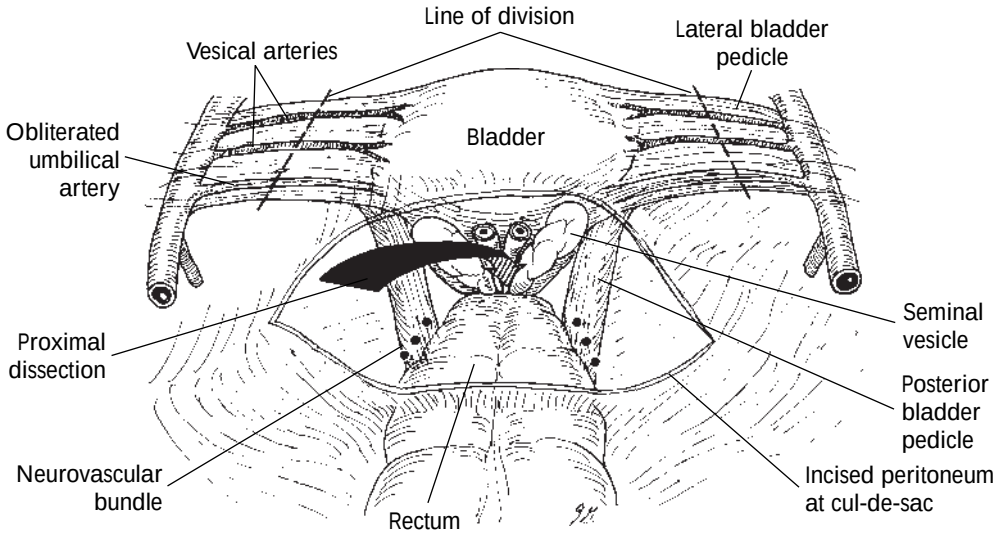

9-19

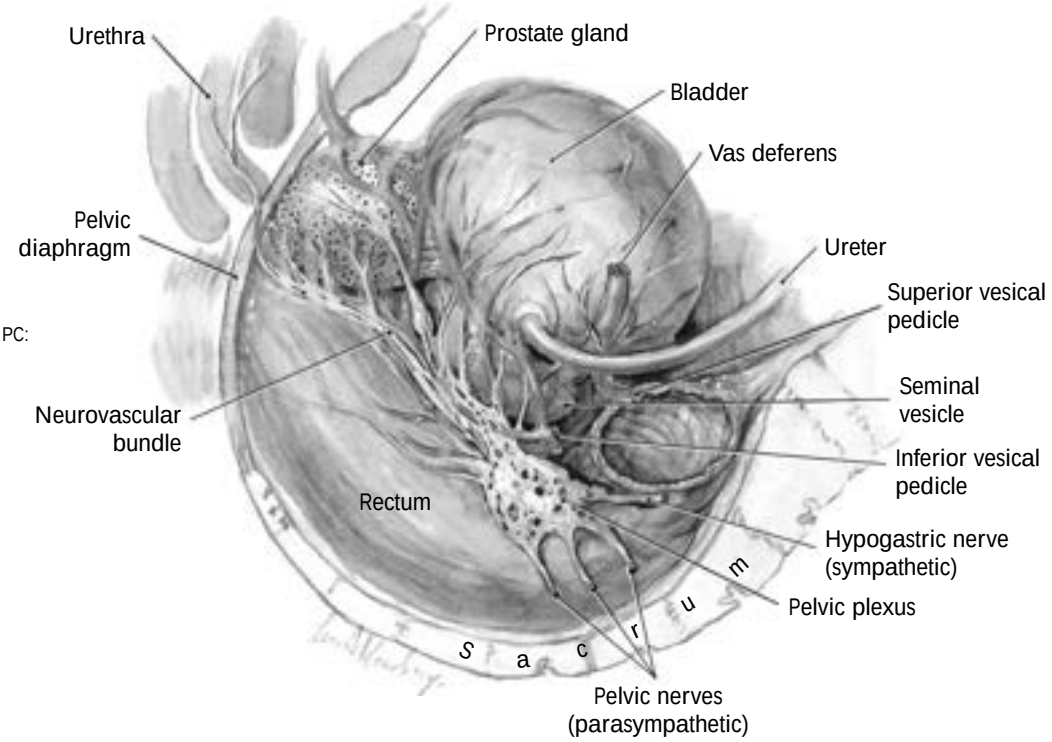

From Schlegel P, Walsh PC: *J Urol* 138:1402, 1987.

9-20

Lateral View

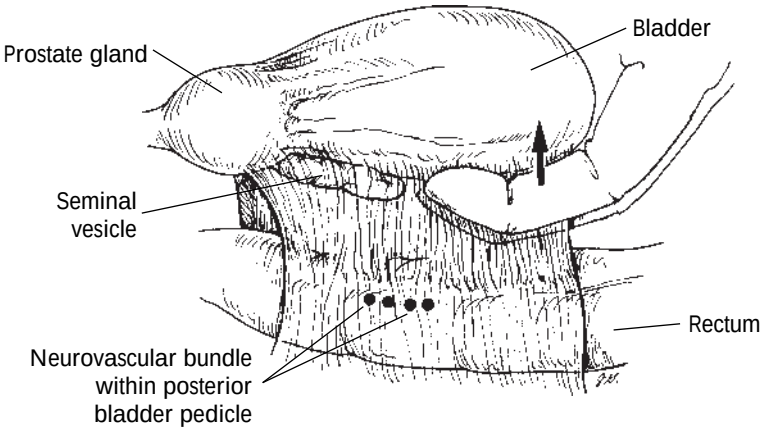

9-21

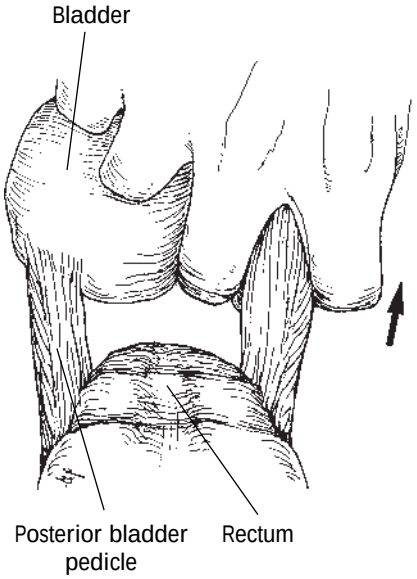

9-22

FIG. 9-22. It is easiest first to ligate and divide the right posterior pedicle completely and then to approach the left side by simply lifting up the free prostate gland and bladder.

STAPLER DIVISION OF BLADDER PEDICLES

The clear advantage of stapler division is the time-saving and blood-saving factor.[3]

Once the prostatic pedicles have been divided from the distal dissection, the surgeon should have enough maneuverability to insert the Endo GIA 60 stapler (U.S. Surgical, Norwalk, Conn.) with the 4.8 mm staple cartridge (green) or the GIA 60 stapler. We prefer the six rows of staples of the Endo GIA 60 to the four rows of the GIA 60.

FIG. 9-23. Finger-pinching the bundled lateral and posterior pedicles as previously described will thin out the fatty components of the pedicles and facilitate placement and engagement of the stapler.

FIGS. 9-24 AND 9-25. The Endo GIA 60 or GIA 60 is placed and engaged with the surgeon's fingers beneath it to prevent injury to the rectum. The stapler lip should extend 2 cm beyond the pedicle when engaged.

The surgeon should now check again for optimal placement of the stapler. It should be lateral to the bladder but medial enough to protect the rectal vasculature and neurovascular bundles. If the position is unsatisfactory, the surgeon should disengage and reposition the jaws.

The gas-powered Endo GIA 60 with 4.8 mm staples (green cartridge) will discharge four times with a fresh cartridge. It is important to engage the *red* button to prevent loss of the gas power.

The GIA 60 can be used as many times as needed with fresh cartridges.

FIGS. 9-26 AND 9-27. In general, two discharges are necessary to divide the bundled lateral and posterior pedicles together. Small residual tissues can be cut and ligated.

The surgeon should always check the stapled lines for persistent bleeding and oversew anything oozing.

Finger-Pinching of Bladder Pedicle

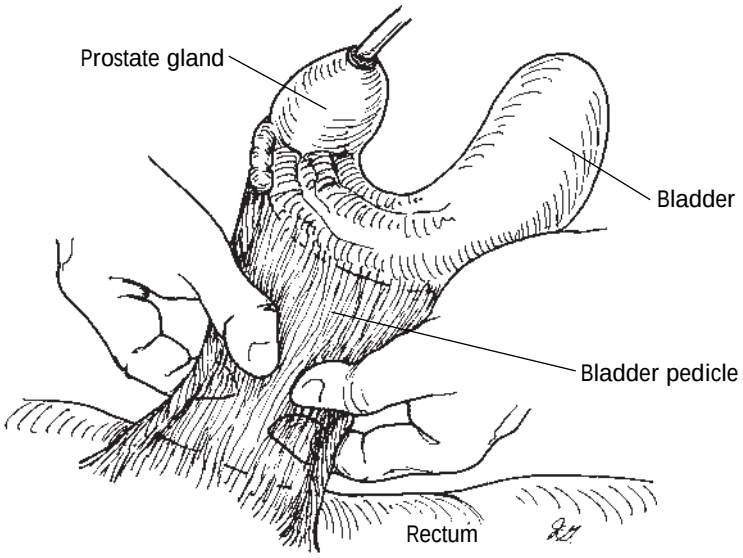

9-23

Stapling with GIA 60 for Bladder Pedicle Division

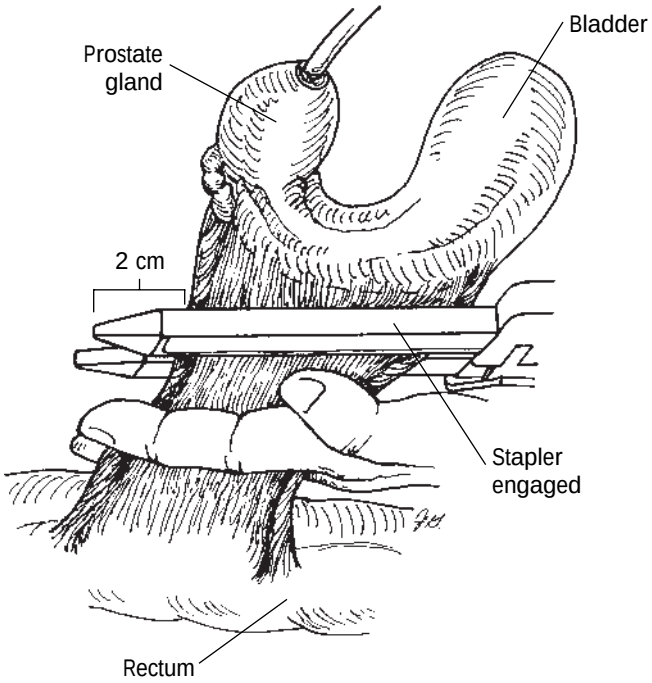

9-24

Stapling Lateral Bladder Pedicle with Endo GIA 60

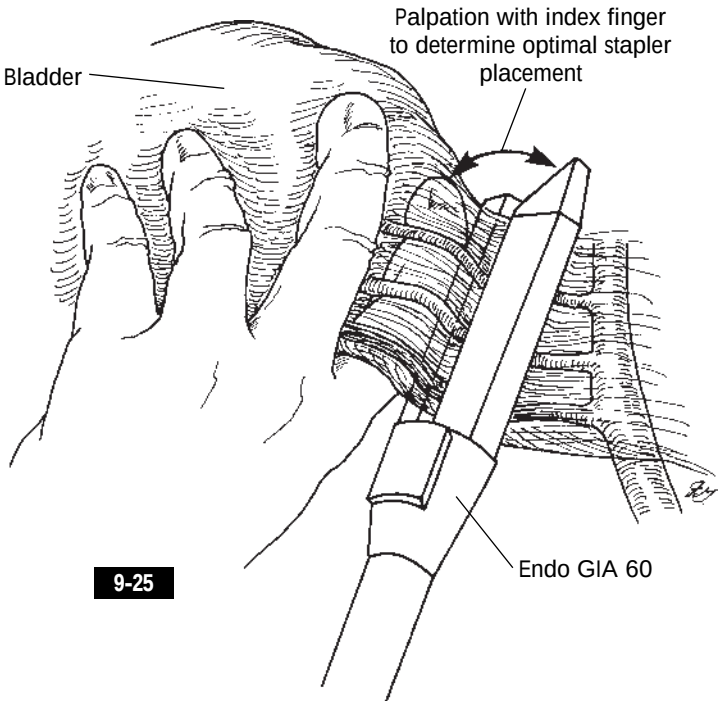

9-25

Pedicle Division

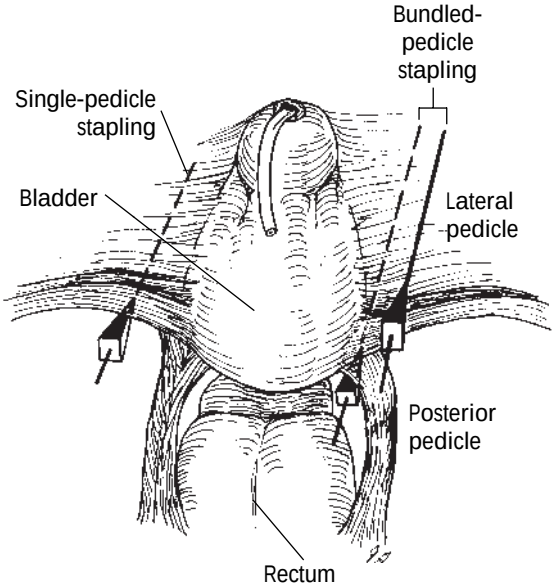

9-26

Bundled-Pedicle Stapling

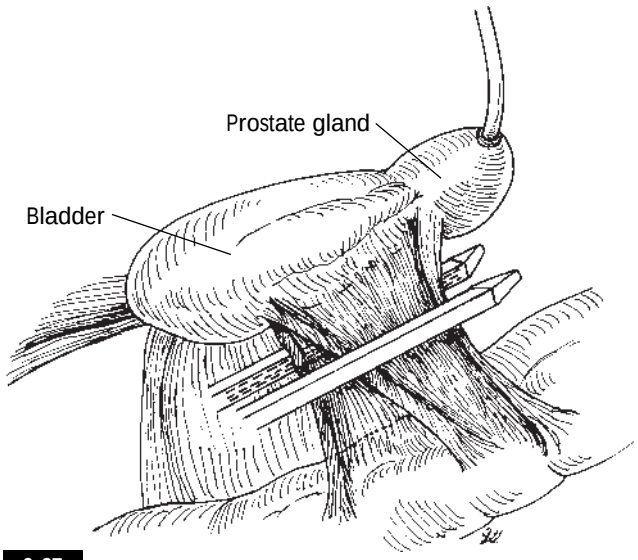

9-27

KEY POINTS

- Bowel mobilization and packing are performed.
- The ureters are isolated with vessel loops.
- A Bookwalter, Balfour Greishe, Finochetto, or Omni retractor is placed with a folded malleable ribbon into the operative field.
- After lymphadenectomy, the hypogastric artery may be ligated distal to the superior gluteal artery if there is no concern with potency.
- The ureters are clipped and divided, and the distal margins are sent for biopsy.
- A dissection plane and space are developed between the bladder/prostate gland and the rectum.
- The neurovascular bundles are located in the posterior bladder pedicles at the level of the tips of the seminal vesicles. If the Foley catheter is pulled taut distally, the surgeon can palpate the Foley balloon through the bladder. This is approximately the same level as the location of the proximal seminal vesicles.
- Distal dissection of the prostate gland is performed as in a radical retropubic prostatectomy.
- The prostatic pedicles are divided.
- The proximal and distal dissections are joined, leaving two pedicles on each side of the bladder. The web of tissue separating the two dissections should be divided or punctured on the prostate gland/bladder side rather than on the rectal side.
- The lateral and posterior pedicles are divided separately or in a bundled fashion.
- Division is performed by Endo GIA 60 stapler application with a 4.8 mm staple cartridge (green) or by the use of clips or Haney or Ballantine clamps.

POTENTIAL PROBLEMS

- *Rupture of hypogastric veins during lymphadenectomy:* Obtain distal/proximal vascular control and perform suture ligation → if necessary, ligate the entire vessel
- *Difficulty in establishing posterior dissection plane between rectum and bladder:* Start the anterior dissection first
- *Pelvis is too small and pedicle ligation and division are difficult:* Use Haney clamps with modified pulley stitches
- *Pelvis is too small to extract large bladder tumor:* Consider partial pubectomy
- *Bleeding from dorsal venous complex:* Perform stitch ligation → use urethral Foley balloon (inflated to 40 ml) as tamponade
- *Difficulty with ligation and division of posterior pedicles:* Ligate and divide the right side first
- *Rectal injury:* Close the rectal tear in two layers → perform loop colostomy (see Chapter 27)

REFERENCES

1 Schlegel PN, Walsh PC: Neuroanatomical approach to radical cystoprostatectomy with preservation of sexual function, *J Urol* 138:1402, 1987.

2 Burgers JK, Brendler CB: Anatomic radical cystoprostatectomy, *Urol Clin North Am* 18(4):659, 1991.

3 Chung S et al: Bladder pedicle stapling in radical cystectomy, *Contemp Urol* January 1996.

SUGGESTED READINGS

Skinner DG: Radical cystectomy. In Crawford ED, Borden TA, editors: *Genitourinary cancer surgery*, Philadelphia, 1982, Lea & Febiger, pp 207-217.

Skinner DG, Lieskovsky G: Technique of radical cystectomy. In Skinner DG, Lieskovsky G, editors: *Diagnosis and therapy of genitourinary tumors*, Philadelphia, 1988, WB Saunders, pp 607-621.

RADICAL CYSTECTOMY IN THE FEMALE

10

FIGS. 10-1 AND 10-2. For radical cystectomy in the female patient, the surgeon makes a midline incision, as is done in the male patient, and then divides and frees the following ligaments and blood vessels of the female reproductive organs:

1. Ligation and division of the round ligaments.
2. Ligation and division of the broad ligaments.
3. Ligation and division of the infundibulopelvic ligaments (suspensory ligaments of the ovary).
4. Ligation and division of the ovarian vessels.
5. Division of the posterior peritoneum between the rectum and the uterus after pelvic lymphadenectomy.

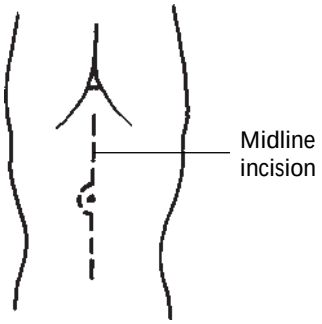

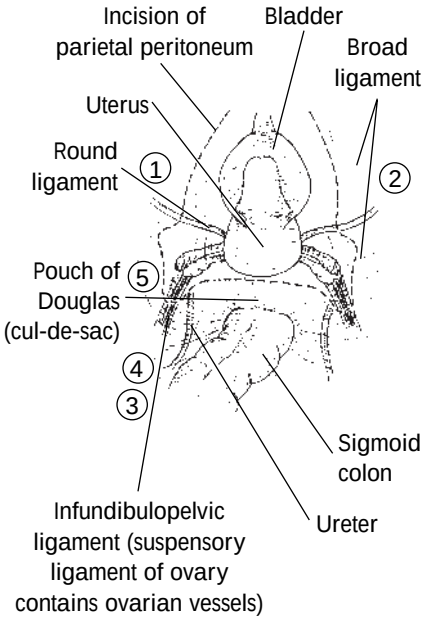

10-1

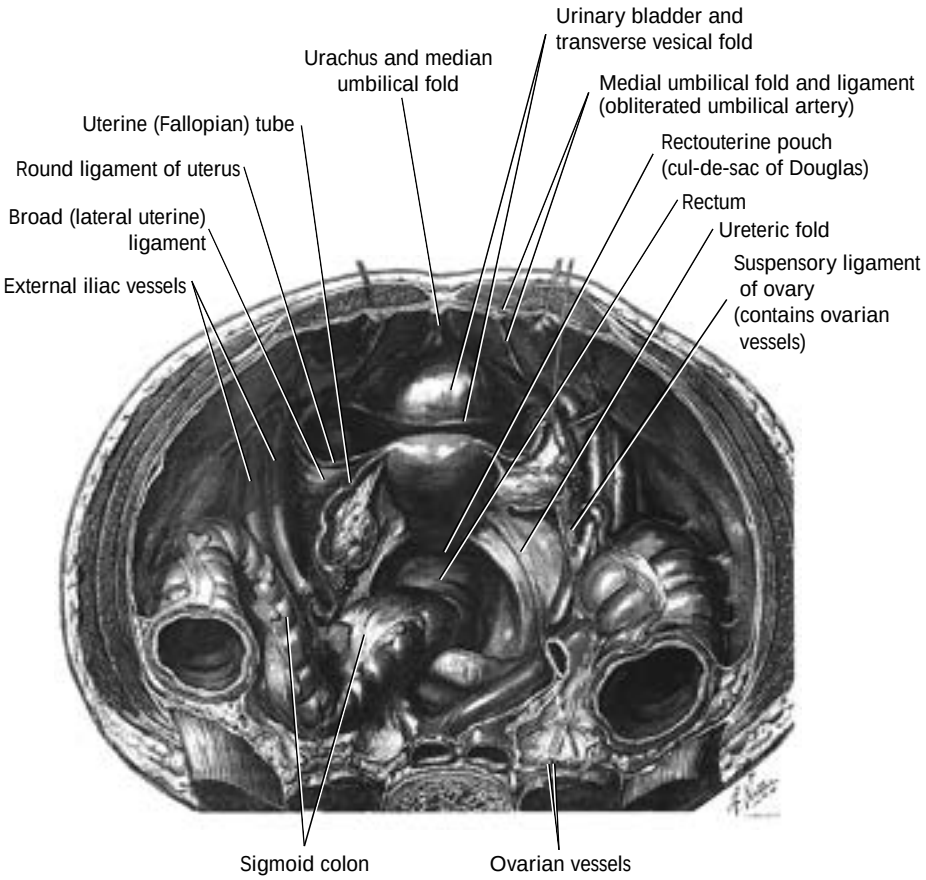

10-2

PROXIMAL DISSECTION AFTER LYMPHADENECTOMY AND URETERAL DIVISION

We prefer first to establish the space between the uterus and rectum before the ligation and division of the lateral bladder pedicles.

After the peritoneal incision is made across and between the uterus and rectum (cul-de-sac or pouch of Douglas), the surgeon uses the fingers to bluntly dissect a plane between the uterus and rectum down to the point at which the Foley catheter balloon (which is inflated with 30 ml of saline solution) can be palpated in the bladder through the vaginal walls.

By placing one or even two laparotomy pads into this space between the bladder and uterus on one side and the rectum on the other for a few minutes, the surgeon can create a well-defined space for the next steps of the cystectomy.

FIGS. 10-3 AND 10-4. While the assistant passes a sponge stick into the vagina from below and presses it up against the most cephalad position of the vagina posterior to the cervix, the surgeon palpates the sponge stick from the proximal dissection through the cul-de-sac (pouch of Douglas). Directly over the site at which the sponge stick can be palpated, the surgeon incises the vaginal wall, thus creating the proximal opening into the vagina.

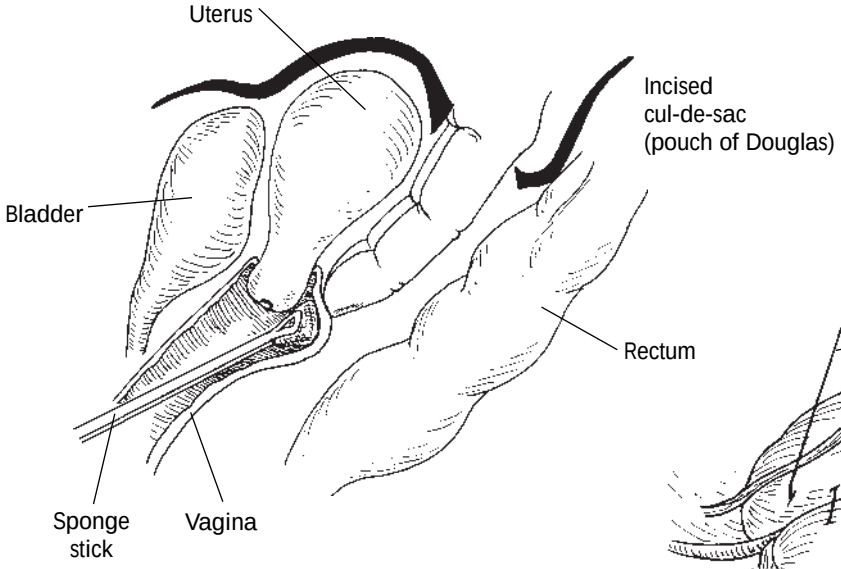

10-3

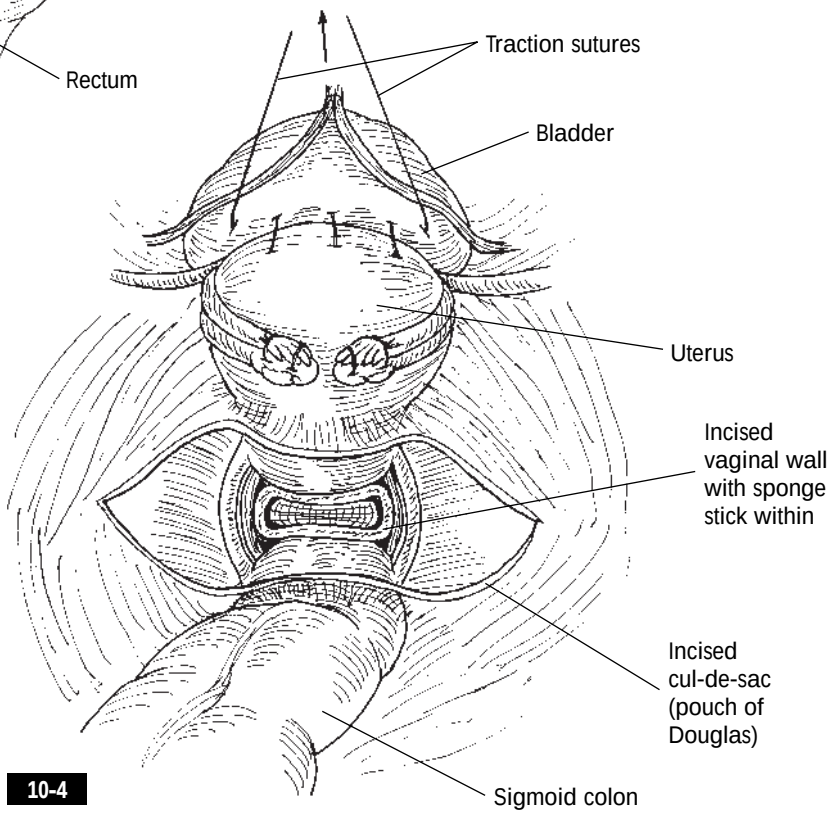

10-4

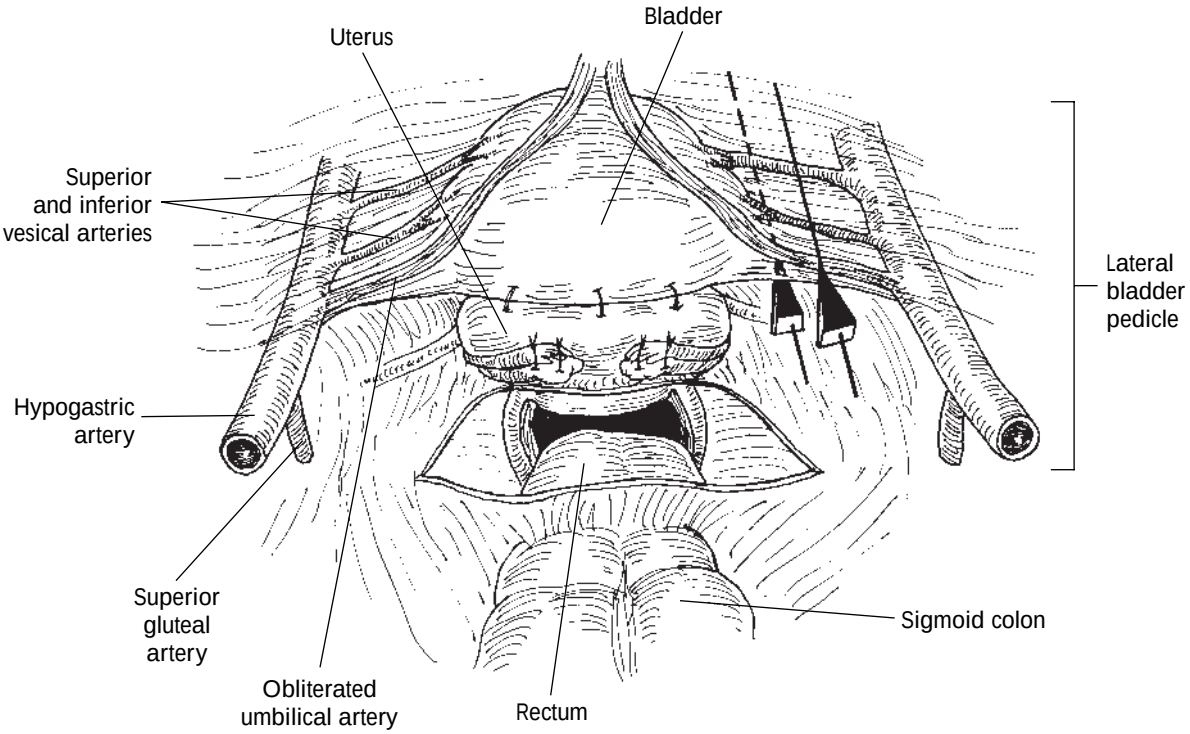

10-5

LATERAL BLADDER PEDICLE DIVISION

FIG. 10-5. The lateral bladder pedicles, which consist of the obliterated umbilical artery, superior vesical artery, inferior vesical artery, and uterine vessels, can be ligated and divided by GIA 60 or Endo GIA 60 staplers, large clips with right-angle clip applicators, or Haney or Ballantine clamps with modified pulley stitches as described in Chapter 9 (see pp. 90-93).

The hypogastric artery can be tied off distal to the superior gluteal artery in the female patient.

Thinning out the lateral pedicle by finger-pinching the fatty tissue will facilitate ligation and division (see p. 92).

The lateral bladder pedicles are divided distally to the endopelvic fascia.

DISTAL/ANTERIOR DISSECTION

If the patient is placed in a semilithotomy position, the surgeon can work from above while an assistant works from below at the vaginal opening for distal bladder and urethral dissection. For convenience, we prefer to perform this part of the operation first, even before making the midline abdominal incision for the cystectomy.

FIG. 10-6. With the patient in a lithotomy position **(A),** the surgeon performs a distal bladder neck dissection as is done in the Raz needle suspension procedure (see pp. 141-143).

After palpating the Foley catheter balloon at the bladder neck region, the surgeon injects saline solution to separate a plane between the vaginal epithelium and the vesical tissues above.

Instead of creating two parallel incisions as is performed in the Raz procedure, the surgeon makes an inverted-U incision to include the urethral meatus **(B).**

Lithotomy Position for Distal Urethral Dissection

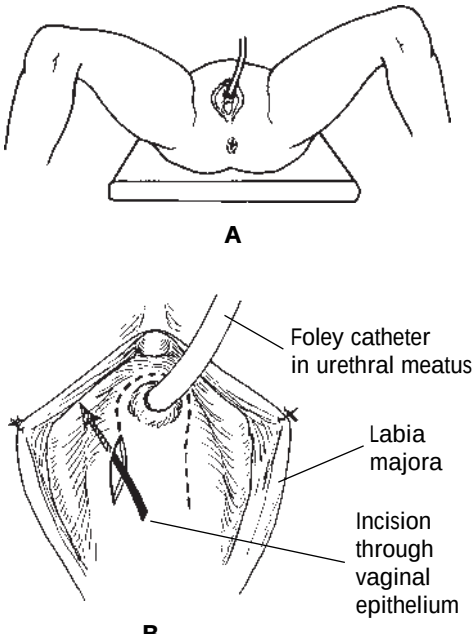

10-6

FIGS. 10-7 AND 10-8. With sharp and blunt dissection, the surgeon punctures the pelvic fascial complex (urethropelvic and the endopelvic fascial layers) to enter the paravesical space bilaterally. Mayo scissors are used with a spreading rather than a cutting action and the surgeon uses the index fingers to further develop the two lateral fascia defects. The horizontal part of the incision around the urethra is minimally developed such that the vaginal epithelium is divided but no further dissection proximally is performed at this time.

Sponge packings are inserted into these two periurethral spaces to serve as tamponades to prevent potential venous bleeding.

Once this stage of the procedure is completed, the patient can be placed into a supine flexed position for the start of the cystectomy with the midline incision.

DISTAL URETHRAL DISSECTION FROM PROXIMAL APPROACH

FIG. 10-9. From the abdominal approach, now the pubourethral ligaments are divided, and the dorsal veins are ligated. Unlike in men, the dorsal venous complex in women often consists of only a few veins.

FIG. 10-10. From the previous dissection on the vaginal side, the surgeon first inserts the left index finger from the vaginal side up through the endopelvic fascial complex into the retropubic space.

Mayo Scissors Perforation of Fascial Complex

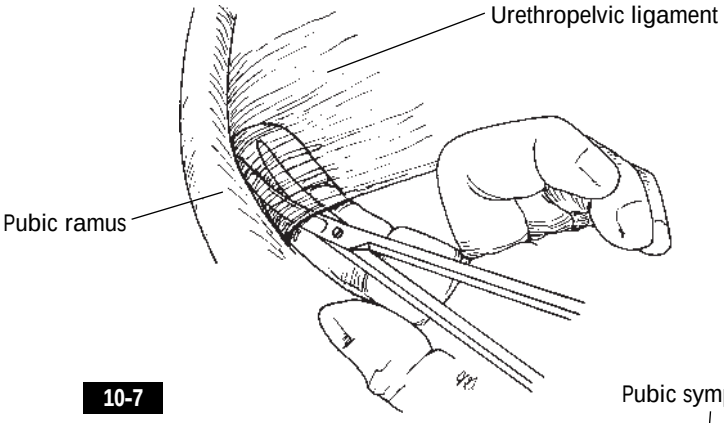

10-7

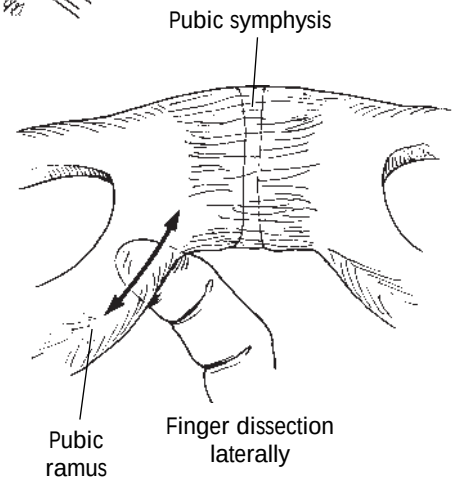

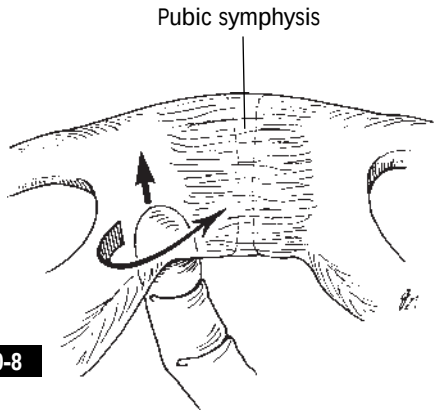

10-8

Dissection superiorly

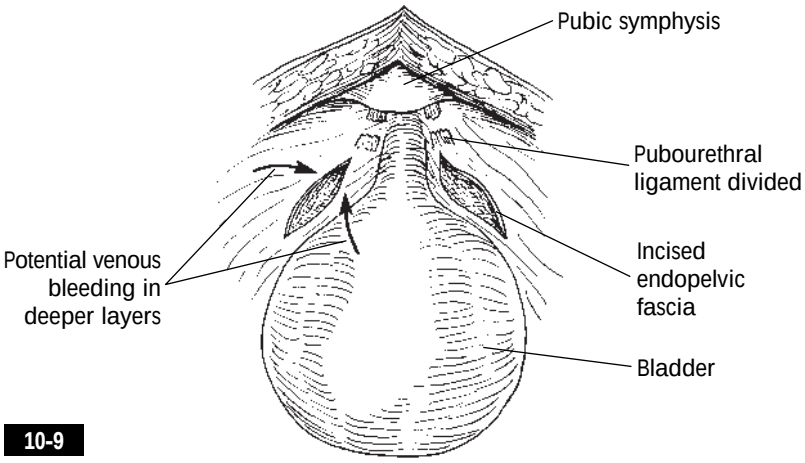

10-9

Retropubic View

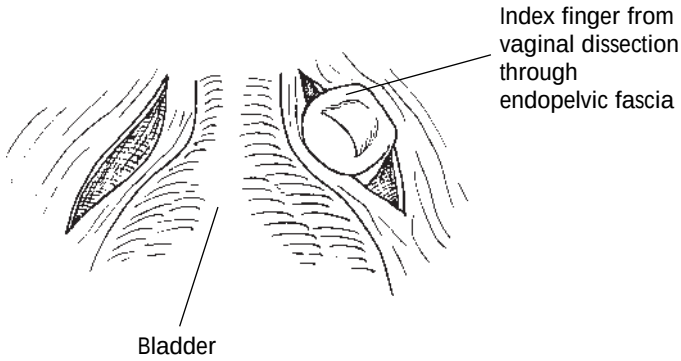

A

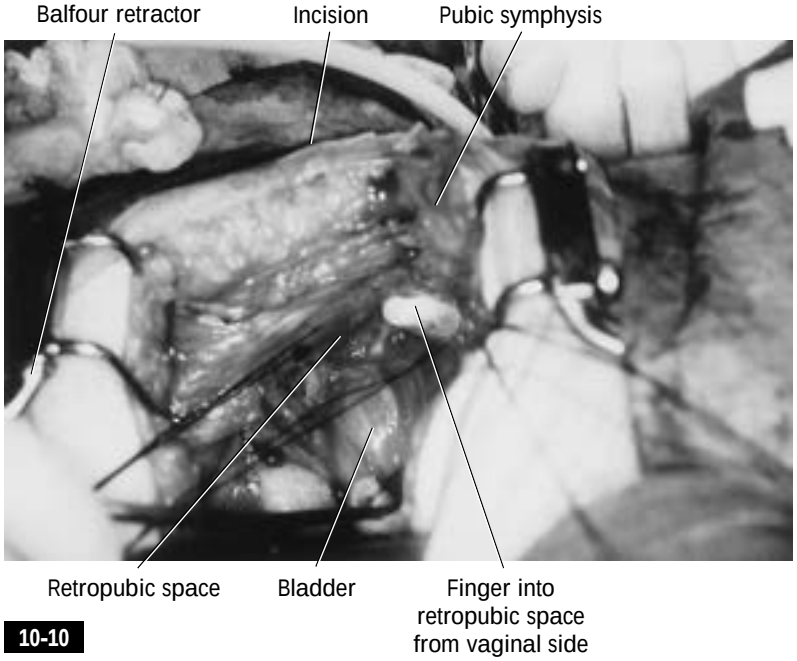

B

10-10

Retropubic View

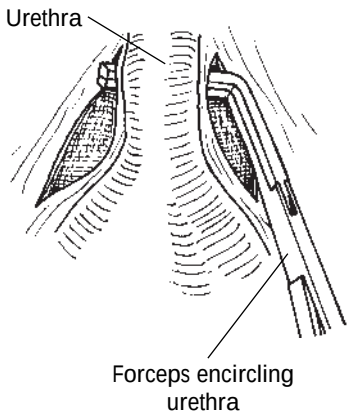

10-11

FIG. 10-11. With the point of a right-angle clamp held in the right hand, the surgeon can follow the left finger down the retropubic space to encircle the urethra.

FIG. 10-12. Three ties (0 Vicryl) are passed around the urethra and Foley catheter and tied. The urethra, the lip of the anterior vaginal epithelium, and the dorsal venous complex are essentially tied as one unit.

The remaining attachments to the distal urethral meatus are ligated and divided to free the urethra entirely. The Foley catheter and urethra are retracted up into the pelvis. When freeing the urethra, the surgeon may encounter venous bleeding from the rich vascular plexus on either side of the urethra and within the pelvic fascial complex. Figure-of-eight stitches on both sides are helpful in controlling venous bleeding.

FIG. 10-13. This connection thus establishes a communication between the distal vaginal opening and the proximal vaginal opening from above.

FIG. 10-14. The two lateral walls of the vagina are incised along with the posterior bladder pedicles and the uterine sacral ligaments. Whether using scissors or an electrocautery device to divide the attachments, the surgeon must protect the rectum by placing the fingers above it.

FIGS. 10-15 AND 10-16. The remaining vaginal wall can be reconstructed to form a tubular structure. The surgeon should suspend the proximal neovagina to the Cooper's ligaments bilaterally, thus obviating future herniation and prolapse.

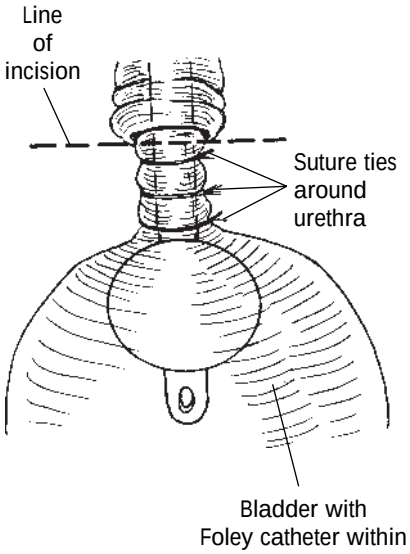

10-12

Joining of Distal and Proximal Dissections (Lateral View)

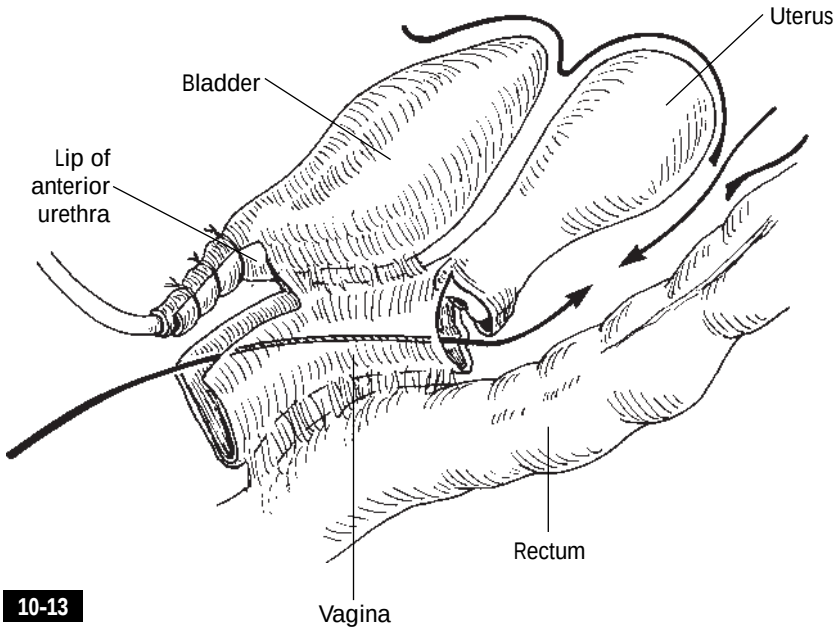

10-13

Lateral View

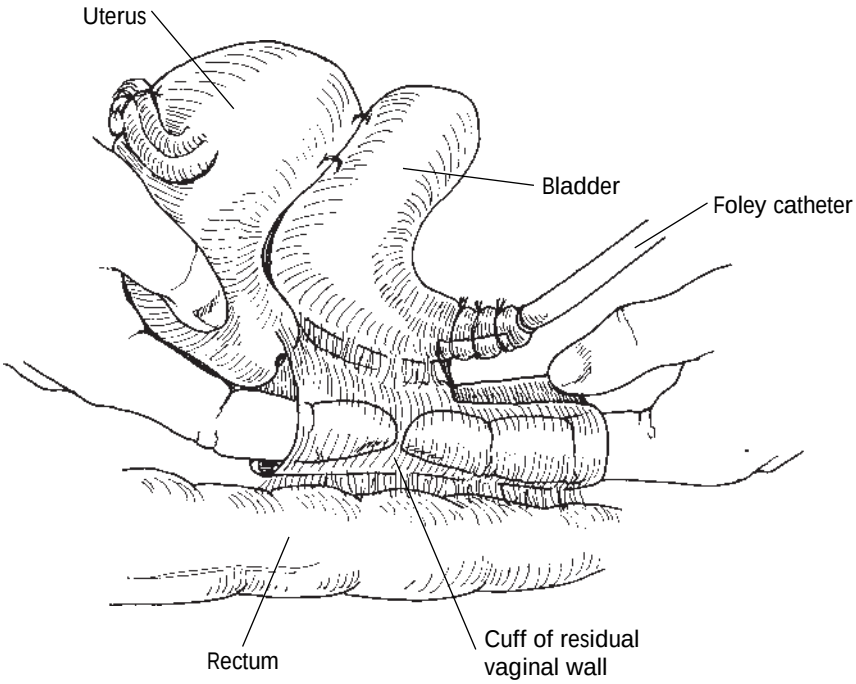

10-14

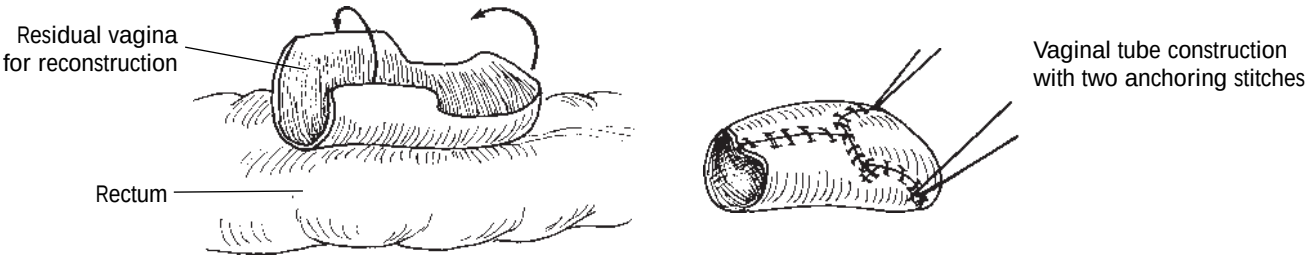

10-15

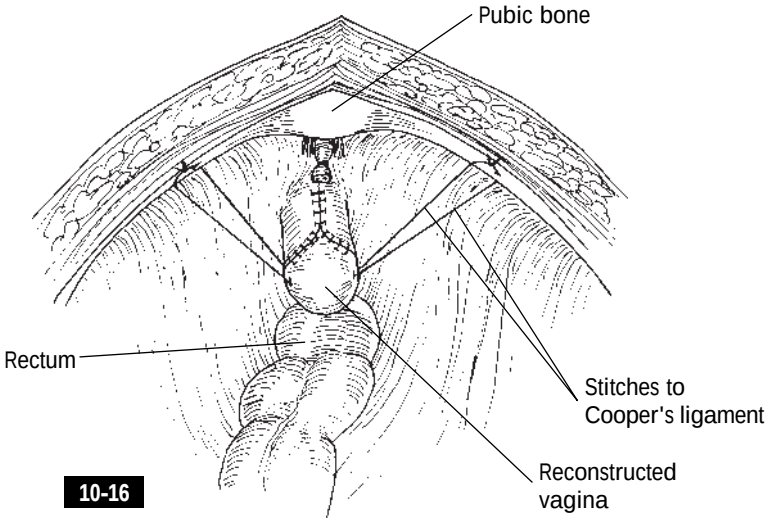

10-16

Dissection for Maximal Preservation of Vagina

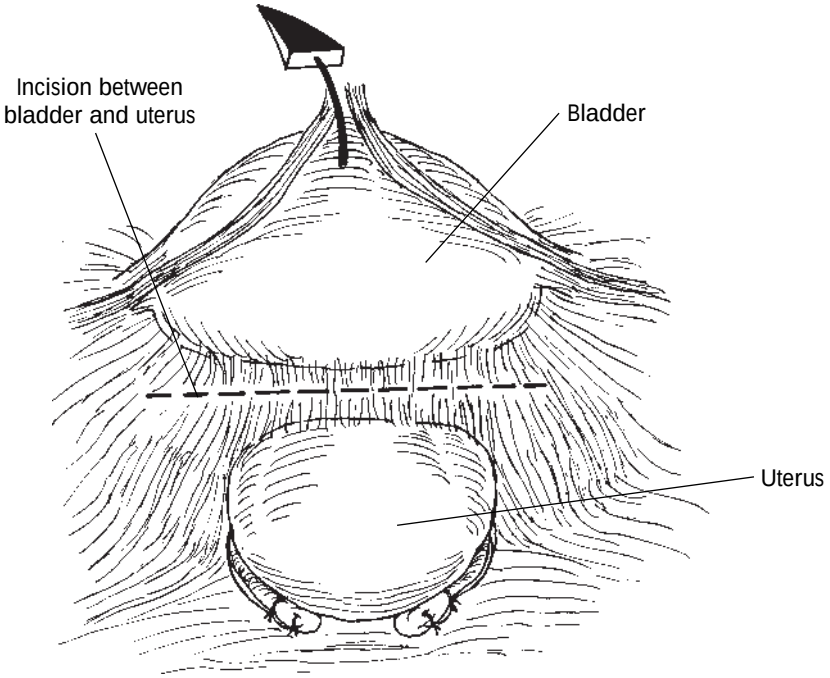

10-17

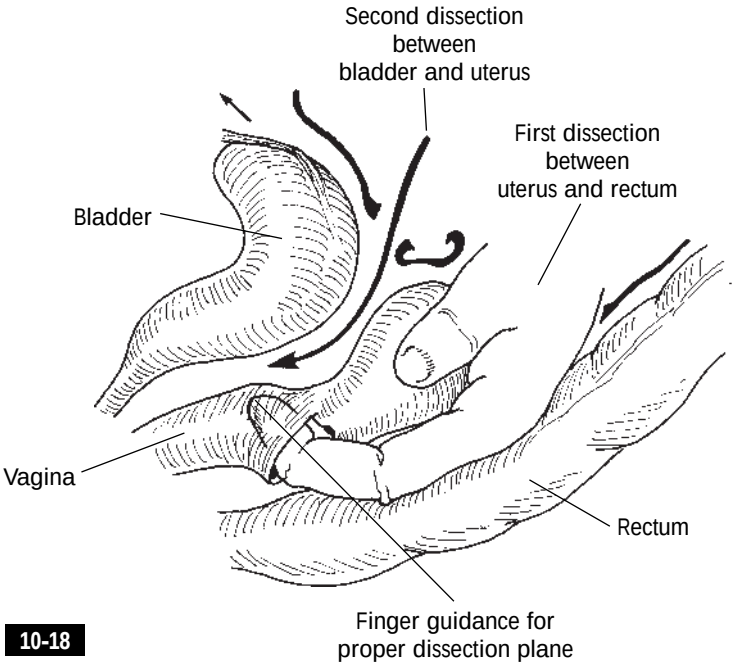

10-18

PRESERVATION OF ANTERIOR VAGINA

In sexually active women who have limited disease confined to the anterior or anterolateral bladder, it is reasonable to preserve the anterior vagina and still perform an effective cancer operation. However, if there is any indication of tumor extension toward the anterior vaginal wall during the dissection, then the surgeon should excise the vaginal wall with the bladder as previously described.

FIG. 10-17. To preserve more of the anterior vagina, the surgeon must first establish a dissection plane between the bladder and the anterior vaginal wall.

FIG. 10-18. By inserting the left fingers into the vagina, the surgeon can perform this dissection with the right hand from above while constantly feeling for the fingers on the other side of the vagina.

This maneuver can be incorporated with the proximal and distal vaginal dissection to preserve as much of the vagina as possible.

PROXIMAL VAGINAL DISSECTION IN POSTHYSTERECTOMY PATIENT

FIG. 10-19. In patients in whom hysterectomy has been previously performed and in whom scarring has obliterated the clear space between the rectum and the site of the previous uterus, the surgeon should carefully open the peritoneum at the cul-de-sac and immediately incise the vaginal wall at the site at which the sponge stick is palpable. This maneuver quickly establishes the proximal opening of the vagina without any chance of rectal injury.

Posthysterectomy Retrovesical Dissection

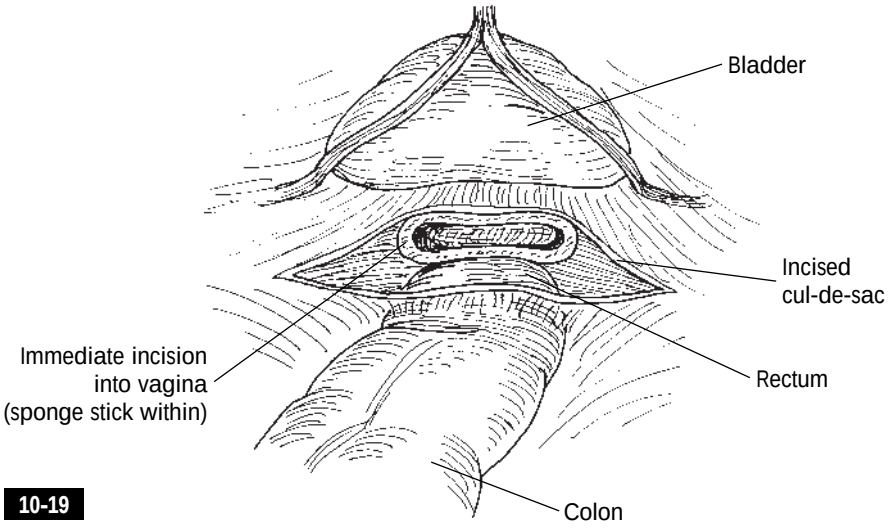

10-19

KEY POINTS

- The suspensory ligaments, ovarian vessels, round ligaments, and broad ligaments are divided.
- The posterior peritoneum between the rectum and the uterus is divided to develop the proper plane.
- The rectum is separated from the uterus and a proximal opening is made in the vagina at the site at which a sponge stick can be palpated through the proximal vaginal wall.
- The lateral bladder pedicles are divided.
- Distal urethral dissection is performed, and the fascial layers are punctured through the endopelvic fascia. This maneuver can be performed first before making the abdominal incision.
- Distal urethral dissection and division are performed.
- The lateral vaginal walls and the uterine sacral ligament are incised.
- The vagina is reconstructed.

POTENTIAL PROBLEMS

- *Injury to hypogastric vein during lateral bladder pedicle ligation and division:* Tie off the hypogastric vein distally and proximally
- *GIA stapling of lateral bladder pedicle causes residual arterial bleeding:* Stitch the bleeding sites
- *Bleeding from dorsal venous complex:* Apply figure-of-eight stitches
- *Bleeding from incised vaginal wall:* Repair with absorbable running stitch
- *Rectal injury during dissection of vaginal wall:* Perform primary repair → create colostomy (see p. 268)

SUGGESTED READINGS

Frieha FS: Radical cystectomy in the female. In Walsh PC et al, editors: *Campbell's urology*, ed 6, Philadelphia, 1992, WB Saunders, pp 2762-2765.

Marshall FF, Treiger BFG: Partial and total bladder reconstruction, surgical craft: radical cystectomy (anterior exenteration) in the female patient, *Urol Clin North Am* 18(4):770, 1991.

Skinner D: Radical cystectomy. In Crawford ED, Borden TA, editors: *Radical cystectomy in genitourinary cancer surgery*, Philadelphia, 1982, Lea & Febiger, pp 207-217.

ILEAL LOOP CONDUIT DIVERSION AND BOWEL REANASTOMOSIS

11

SELECTION OF ILEAL SEGMENT AND ITS MESENTERY

At 10 cm from the ileocecal valve, the selected segment of ileum should be short enough to act as a conduit (generally 10 to 15 cm long). In determining the length of the ileal segment, the surgeon must consider the following three factors:

1. Position of the ureters, especially the possible tension of the left ureterointestinal anastomosis
2. Individual variation of fat and muscle depth between the abdominal skin and the peritoneal cavity
3. Creation of a good nipple stoma that prevents urine leakage from the conduit bag.

FIG. 11-1. The surgeon first approximates the stomal end of the conduit, selects a point 3 to 4 cm above the horizontal plane of the abdominal skin, and then estimates the length of ileum needed proximally to meet the ureters at the level of the retroperitoneum posteriorly. There should be no tension in approximating the ureter to the ileal segment (especially the left ureter).

The selected length of the ileum can be marked with silk stitches, and the surgeon checks for proper mesentery vascularity and the lines of division. The easiest method is to transluminate with a light source behind the mesentery in a darkened room. The surgeon can visualize the entire mesenteric

Estimation of Ileal Segment Necessary for Conduit (Cross-sectional View)

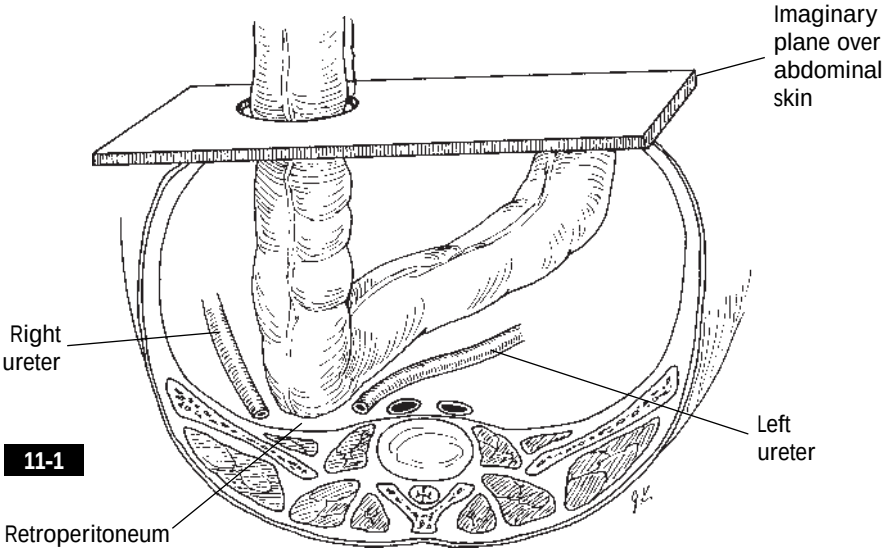

11-1

vasculature from the opposite side. The mesentery division of the stomal end is longer than the mesentery division for the proximal end of the conduit.

For creation of a good stoma, it is important for the surgeon first to select a segment of the mesentery that is flexible and pliable (not fixed) and then to divide the mesentery so that it is long enough that when the open end of the loop is pulled through the fascia and skin for fixation there is no tension.[1]

DIVISION OF MESENTERY

FIG. 11-2. After the superficial layers of the mesentery have been divided with the knife, we have found that by finger-pinching the fatty mesentery, the mesenteric tissue is compressed and bluntly divided while the residual blood vessels are easily visualized and tied.

FIG. 11-3. The gas-powered LDS stapler (Autosuture, U.S. Surgical, Norwalk, Conn.) can also be used to divide the mesentery **(A).** If the tissues are thin, it is not necessary for the LDS stapler to loop around two mesenteric openings before firing. We have placed the LDS stapler into one opening and discharged the staples effectively over the tissues without mechanical problems **(B).**

The surgeon must be careful not to injure the root of the mesentery vasculature when stapling.

Three-Finger Pinching Maneuver

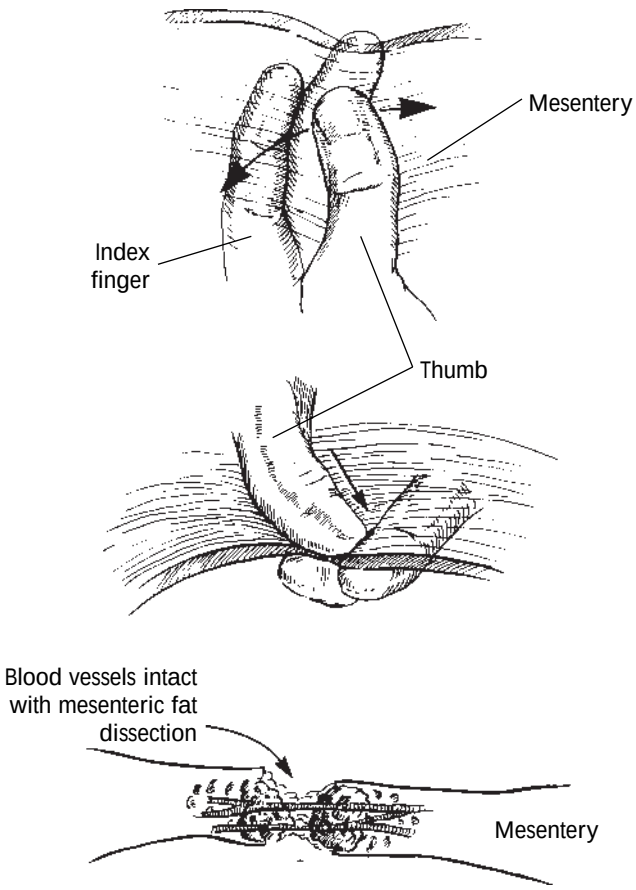

11-2

Traditional Method of LDS Stapling

One-Margin Method of LDS Stapling

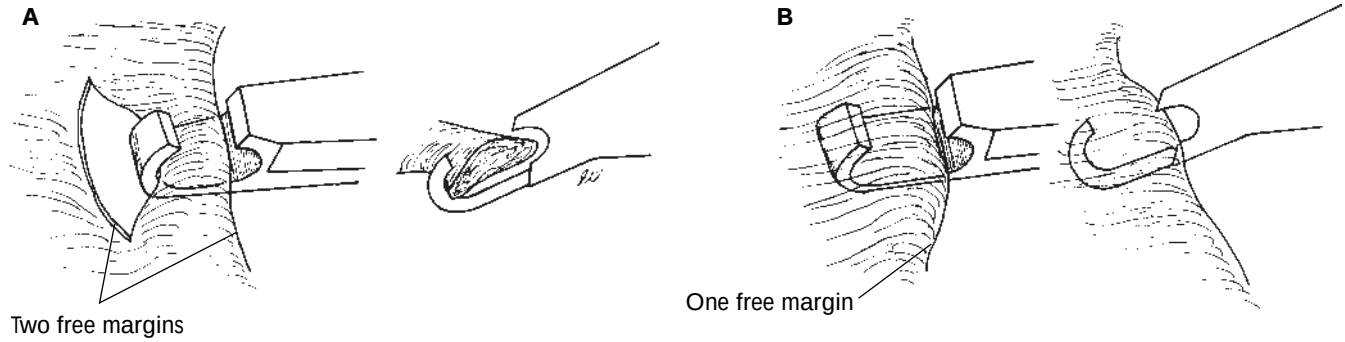

11-3

GIA STAPLING TECHNIQUE FOR BOWEL REANASTOMOSIS

FIG. 11-4. For bowel division, the surgeon can either use the GIA 60 stapler or perform traditional bowel division with clamps. If using the GIA stapler, the surgeon can simply apply the stapler at a right angle to the selected ileal segment.

FIGS. 11-5 AND 11-6. After a segment of the ileum has been divided for the conduit using the GIA 60 stapler and placed posteriorly behind the two bowel segments to be reanastomosed, a small opening is made at the antimesenteric border on the two stapled butt ends of the bowel. The GIA 60 stapler is placed inside the bowel lumen in a side-to-side configuration, engaged, and then discharged.

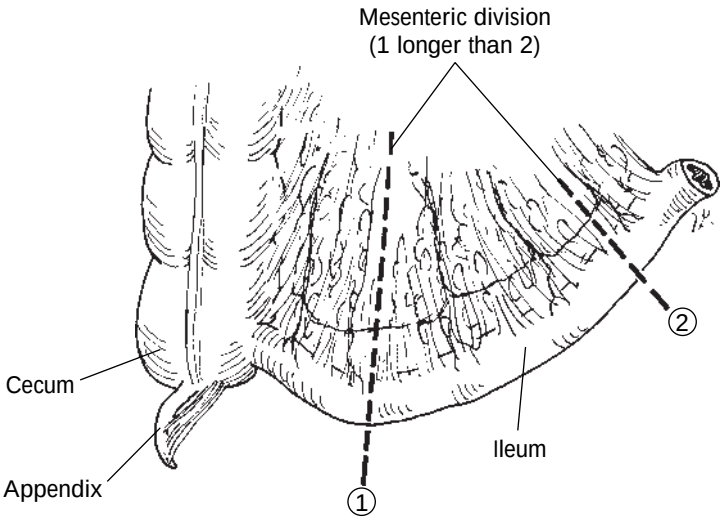

11-4

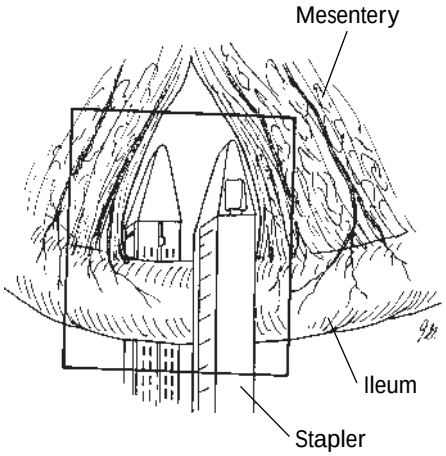

11-5

Reanastomosis of Ileum

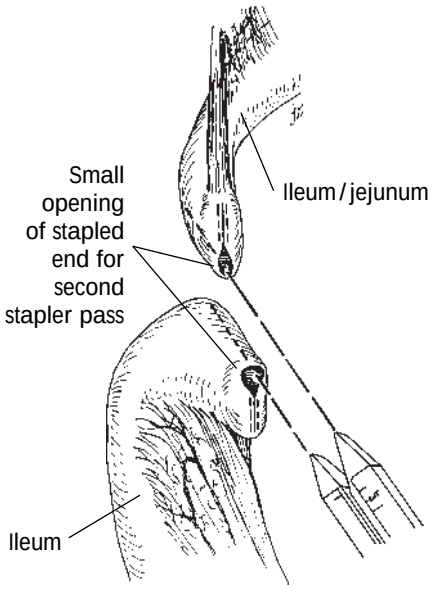

11-6

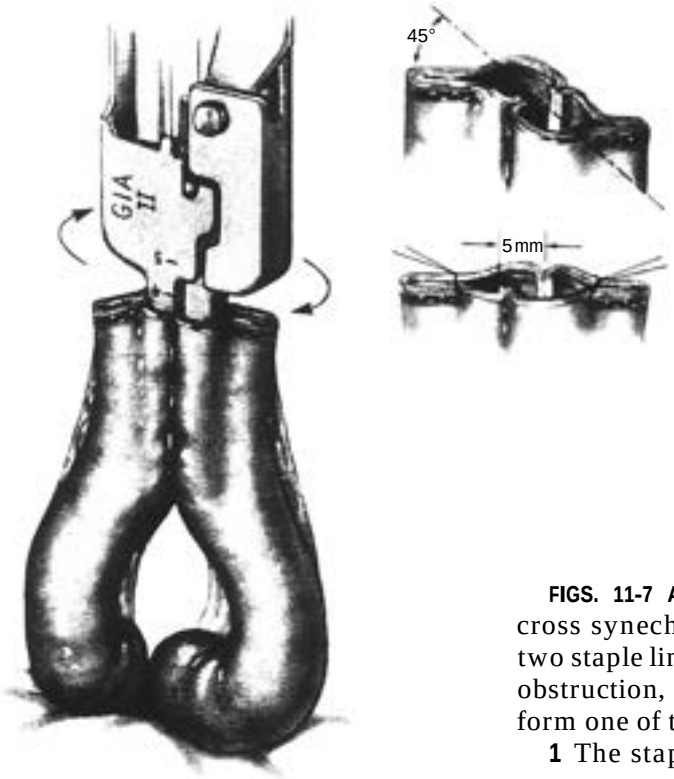

From Steichen PM, Ravitch MM: Mechanical sutures in operations on the small intestine. In Nelson RL, Ravitch MM, editors: *Surgery of the small intestine,* Norwalk, Conn, 1987, Appleton & Lange.

11-7

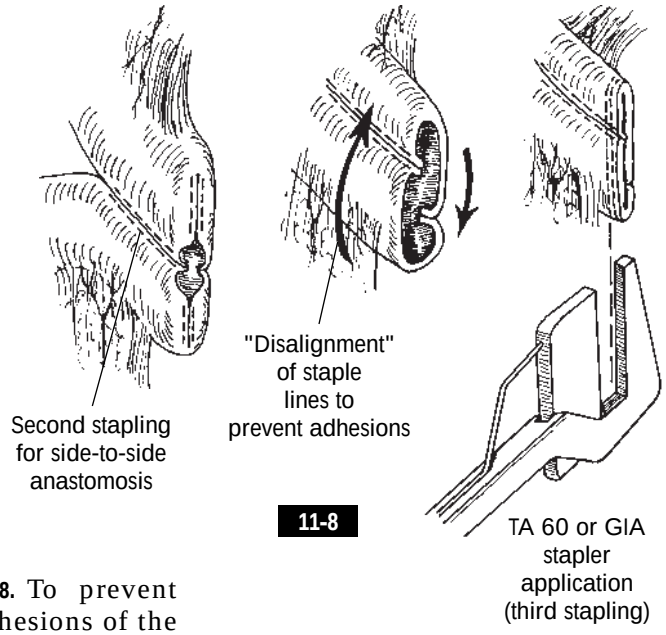

11-8

FIGS. 11-7 AND 11-8. To prevent cross synechial adhesions of the two staple lines, which can lead to obstruction, the surgeon can perform one of two maneuvers:

1. The stapler is rotated before engagement, thus causing the two staple lines to be offset (Fig. 11-7).[2,3] We have not always found this method effective and therefore use a more definitive maneuver.
2. After creating the wide side-to-side anastomosis, we cut the butt-end staples out and rotate the bowel so that the two lines of stapling do not oppose each other. Then we place Babcock clamps over the new configuration of the butt end. The surgeon can use the GIA 60 or 80 stapler or the TA 60 stapler for the closure (Fig. 11-8).

FIGS. 11-9 AND 11-10. The crotch end of the side-to-side anastomosis is reinforced with a few stitches. Compared to an end-to-end anastomosis, the side-to-side anastomosis clearly has the advantage of creating a larger anastomotic lumen. The mesentery is reapproximated to prevent any herniation of bowel segments. The reapproximation should not be so tight that it compromises the vasculature to the ileal loop segment.

Side-to-Side Bowel Anastomosis

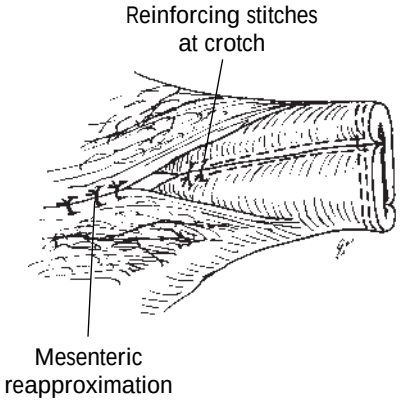

11-9

Intestinal Luminal Enlargement with Side-to-Side Anastomosis

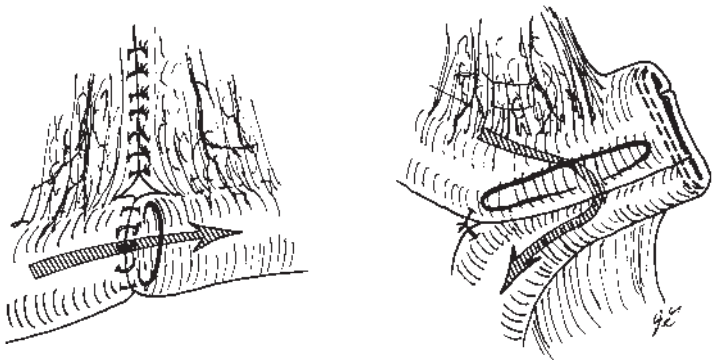

11-10

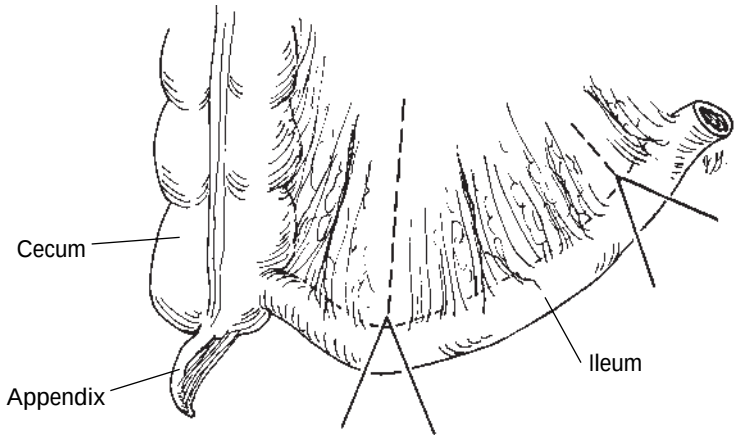

11-11

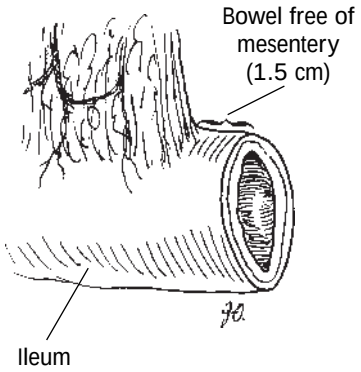

11-12

Continuous Stitch

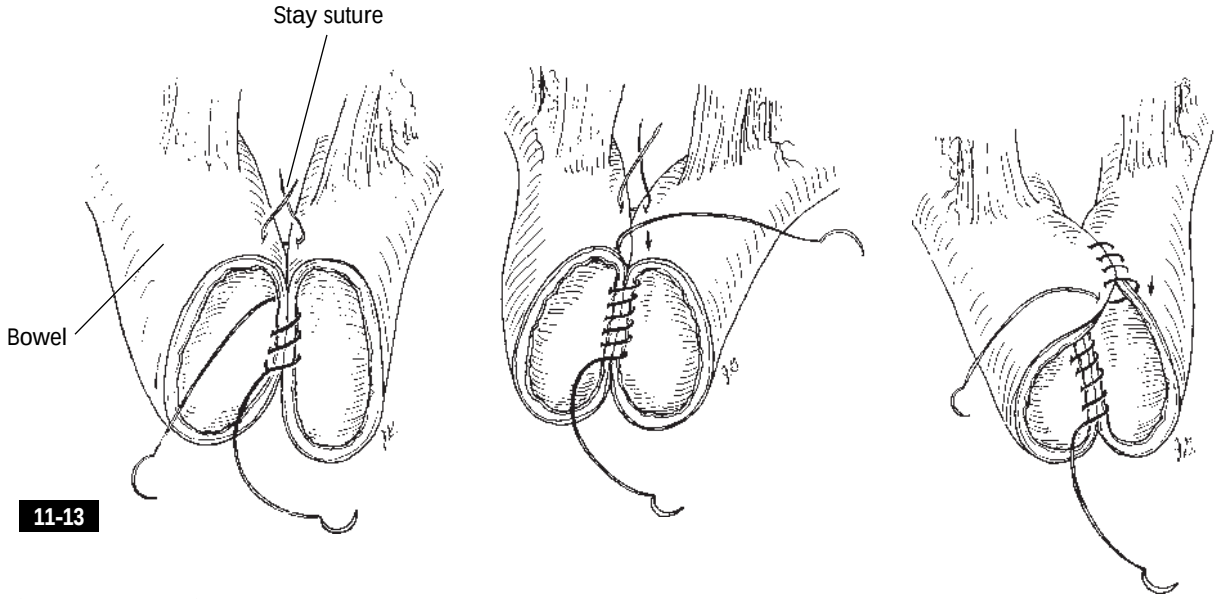

11-13

END-TO-END TRADITIONAL STITCHING METHOD FOR BOWEL ANASTOMOSIS

FIG. 11-11. Unlike the technique of applying the GIA 60 at right angles to the bowel, the surgeon must apply the clamps at a slight angle to avoid bowel ischemia.

The bowel is clamped in a wedge configuration and then divided.

FIG. 11-12. A free margin of bowel measuring 1.5 cm should be cleared of the mesentery for the reanastomosis.

FIGS. 11-13 AND 11-14. A simple continuous stitch all the way around or a combined continuous and anterior Connell stitch can be used for the first layer of closure. The arrows point to the placement of the next stitch.

Anterior Connell Stitch

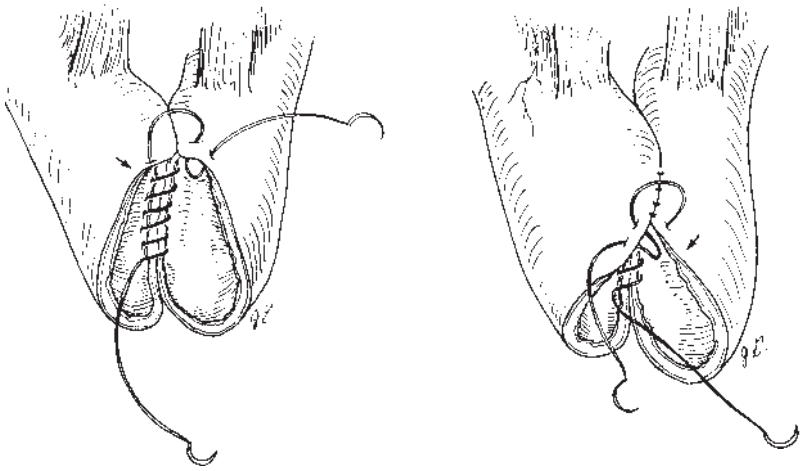

11-14

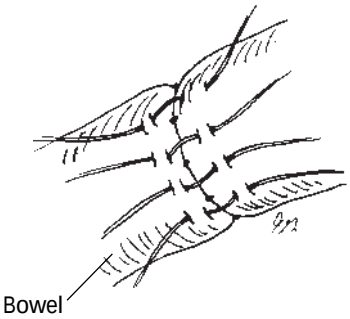

11-15

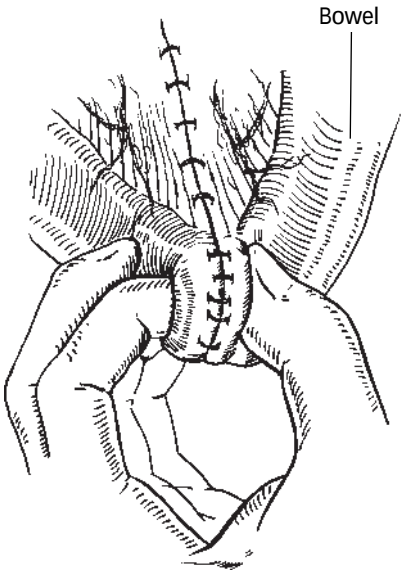

11-16

FIG. 11-15. A second layer of a horizontal mattress silk stitch can be used to reinforce the anastomosis.

FIG. 11-16. After the anastomosis, the surgeon should always check for luminal patency by pushing the index finger across the anastomosis against the thumb as illustrated.

PARKER-KERR STITCH AT PROXIMAL END OF CONDUIT

FIG. 11-17. The ileal loop segment is opened and irrigated clear of mucous contents. A bowel clamp is placed over the proximal end first. This end of the ileum is closed using a Parker-Kerr stitch (**A** and **B**) and then a running horizontal mattress stitch **(C).** Both layers of suture invaginate the bowel. This closure can be performed with one or two stitches.

Parker-Kerr Stitch for Ileal Conduit

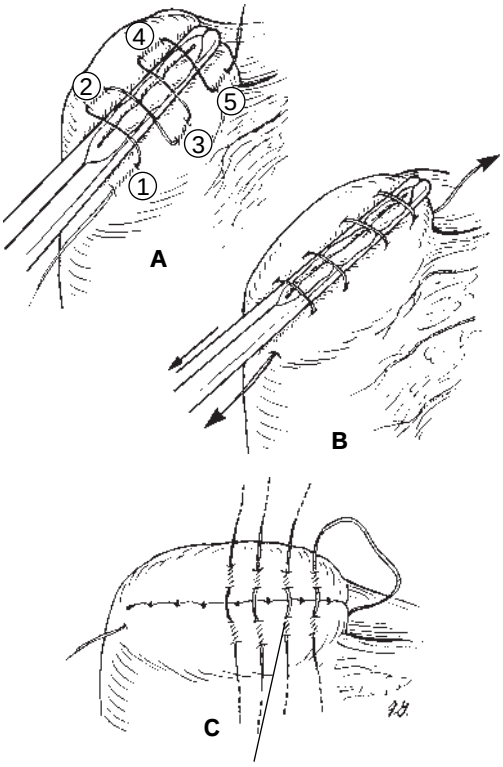

11-17

LEFT URETERAL MOBILIZATION AND PARIETAL PERITONEAL TUNNEL

While making the initial incision lateral to the right or left colon, the surgeon should continue the right lateral incision so that it sweeps around the cecum and up the mesenteric root. This incision actually facilitates the mobilization of the left ureter to the right side by decreasing the width of the parietal peritoneal tunnel.

After making the left lateral incision along the line of Toldt, the surgeon immediately uses the left fingers to bluntly dissect a plane between the parietal peritoneum and the retroperitoneal structures to create the tunnel for the left ureteral transposition, as similarly described for transureteroureterostomy (see p. 65). A wide tunnel, allowing three fingers to pass through, is adequate. The inferior mesenteric artery should not be in the way of the tunnel.

The left ureter is freed to the level of the lower pole of its kidney before it is passed through the tunnel.

URETEROILEAL ANASTOMOSIS

If the ureters were clipped after their division earlier in the operation, by this time there should be a hydronephrotic dilated ureter, which will facilitate the ureteral intestinal anastomosis.

FIG. 11-18. Proper spatulation (3 to 4 mm) of the ureter is imperative to ensure an adequate anastomotic lumen. The first three stitches at the vertex are the most important in any type of ureteral bowel anastomosis.

As in all anastomoses, the apposition of mucosa or epithelium to each other is vital to prevent strictures. There must be contact between ileal mucosa and the ureteral urothelial epithelium in the anastomosis.

FIG. 11-19. Before complete closure of the anastomosis, a ureteral self-retaining diversionary stent (Bard 8 Fr) is placed up to the kidney. The self-retaining stent will not slip out during subsequent surgical maneuvers. The stent is brought out through the distal ileal end and fixed in place with a stitch (4-0 chromic), which is later removed. The end of the stent draining the right side is cut at a right angle to the tubing, and the end of the stent draining the left side is cut at an oblique angle.

STOMA CREATION

FIG. 11-20. The stoma should be placed at a location that will be away from the waistline, beltline, and skin folds when the patient is in either the standing or sitting position. An experienced stomal therapist and/or the surgeon should choose the stomal location 1 or 2 days before surgery so the patient can test the stoma ad-

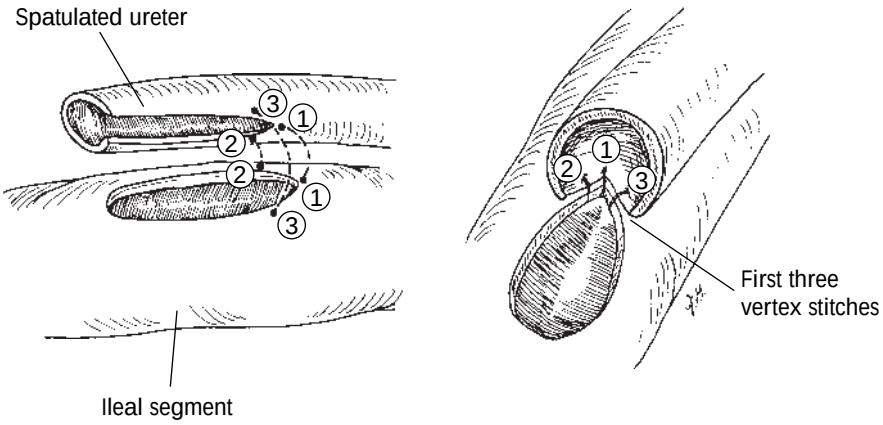

11-18

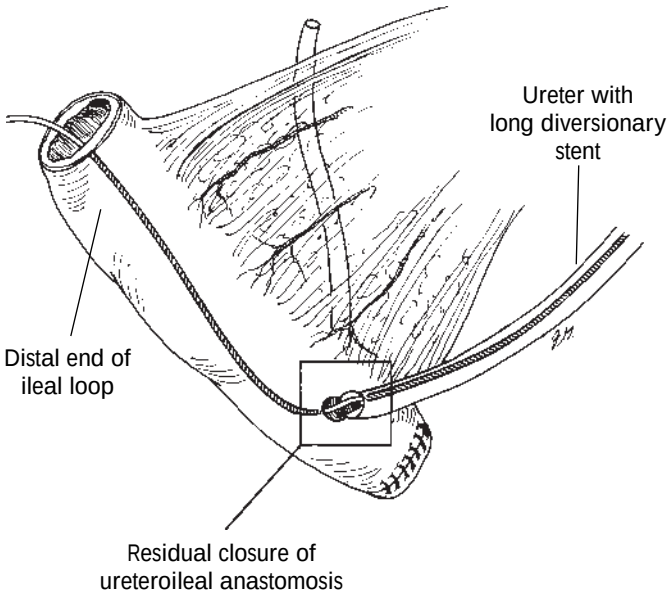

11-19

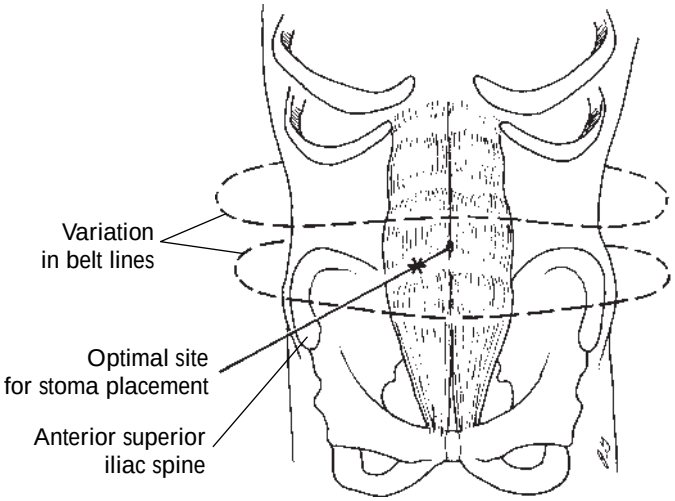

11-20

Variation in Stomal Skin Incisions

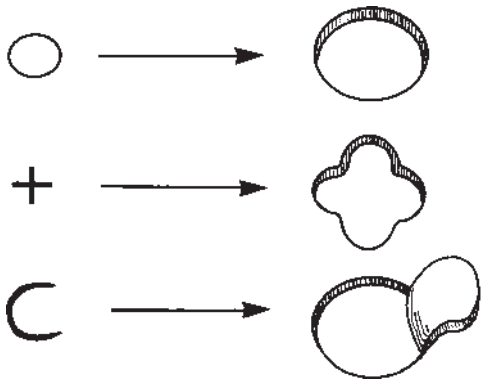

11-21

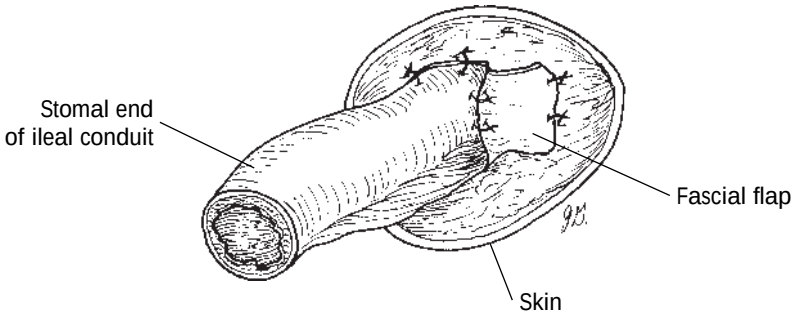

11-22

Anterior Rectus Fascia Flap with Fixation

Lateral View

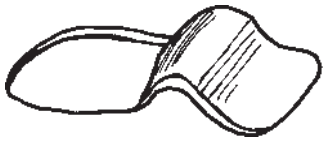

Top View

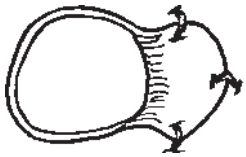

11-23

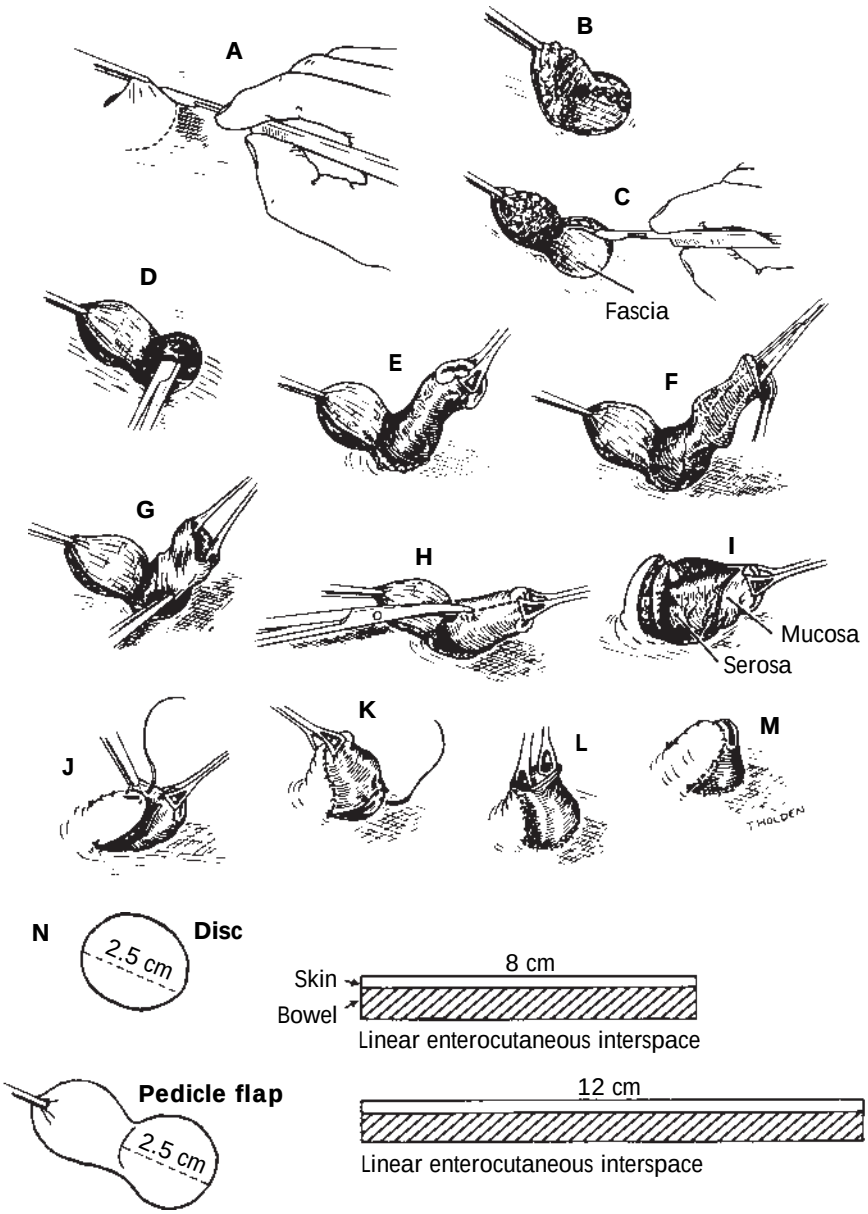

From Mahoney EM, Harrison JH: *J Urol* 123:475, 1980.

11-24

hesive ring for proper positioning and comfort.

The rectus fascia and rectus abdominis muscle should be used as a support and backing for the stoma.[4,5]

FIG. 11-21. The inexperienced surgeon invariably makes the circular stomal skin incision too large. The surgeon must keep in mind that a circular skin incision 7 mm in diameter can easily be enlarged to double its original size to 14 to 16 mm if necessary. Alternative incisions with a cross or a horseshoe configuration also have been successfully used.

FIGS. 11-22 AND 11-23. Below the skin incision, the surgeon can simply make an incision of the anterior and posterior fascia or make a horseshoe flap of the rectus fascia and fix it laterally to prevent fascial contractions.[6,7]

FIG. 11-24. Patients with previous irradiation or poor nutritional status are at risk for the development of skin and fascial contractures. In this situation, a horseshoe incision of the skin and/or rectus fascia can be used instead of a circular incision.

The technique is performed as follows.[6] Via a subcutaneous horseshoe incision **(A** and **B),** a pedicled fascial flap is elevated **(C).** The underlying rectus abdominis muscle is incised at a 90-degree angle to the muscle fibers **(D),** thus obviating the noose effect when the ileum is brought through for stoma construction **(E).** A standard turned-back ileal stoma is constructed by grasping the ileal wall intraluminally with a Babcock clamp 4 cm from the cut edge **(F)** and turning the distal 4 cm of the ileum back on itself **(G).** Beginning at the distal turned-back edge of the ileum, the surgeon incises through the full thickness of the turned-back ileal segment to the apex, avoiding the mesenteric attachment **(H).** The pedicled skin flap is then stitched to the cut edges of the ileum using circumferential interrupted sutures **(I** and **J),** with care taken to include not only the skin and ileal edges but also the serosa of the inner ileum in the suture bites. These stitches ensure that the stoma will remain protruding **(K).** Sutures are placed intraperitoneally between the mesentery and peritoneum to ensure closure at this site, which is at risk for hernia. However, sutures are placed only at the cutaneous and peritoneal levels; the muscle and fascia are left free and are not sutured to the ileum. The surgeon evaluates the lumen for narrowing, constriction, or torsion **(L).** The final result is a stoma that protrudes 3 to 4 cm above the skin and is protected by the pedicled flap from trauma **(M).**

The pedicled flap created with the horseshoe incision prevents significant contracture and has greater linear enterocutaneous interspace, which means improved vascularity **(N).**

STOMAL NIPPLE CREATION

The patient's lifestyle and comfort will depend on the creation of a proper stomal nipple by evagination of a segment of ileal conduit. For a good evaginating nipple, the surgeon needs to accomplish the following:

1. A 3 to 4 cm ileal segment above the skin level.
2. Sufficient length of division of the bowel mesentery to avoid retractile tension of the distal ileal conduit segment. Any retractile tension will either pull the loop back into the peritoneum or create an uneven nipple.
3. Fixation of the ileum at the level of the fascia circumferentially, avoiding the fixation stitch at the mesentery.

FIG. 11-25. By first sewing the anterior and posterior rectus fasciae together and then fixing them to the ileum circumferentially (avoiding the mesentery), the surgeon can avoid retraction of the entire conduit.

FIG. 11-26. A second set of stitches evaginates the ileum while fixing it to the skin subepithelium. No stitches are placed on the mesentery.

FIG. 11-27. The ureteral stents are fixed to the skin.

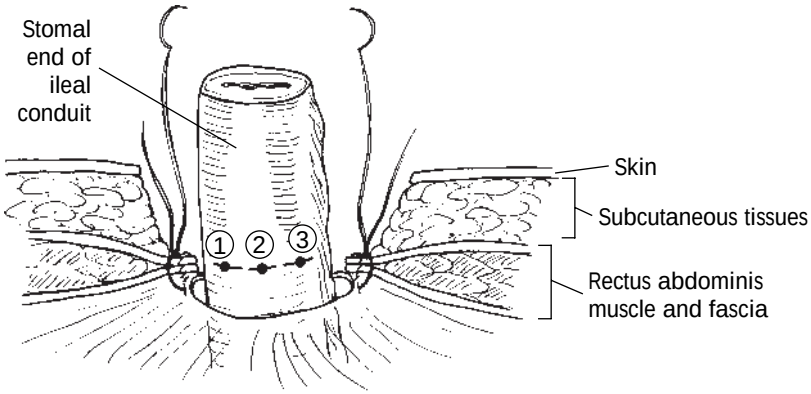

First Level of Ileofascial Fixation

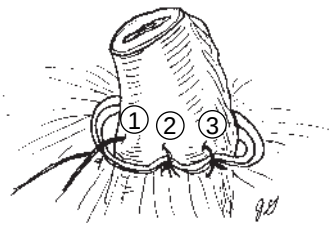

11-25

Second Level of Ileal Evagination

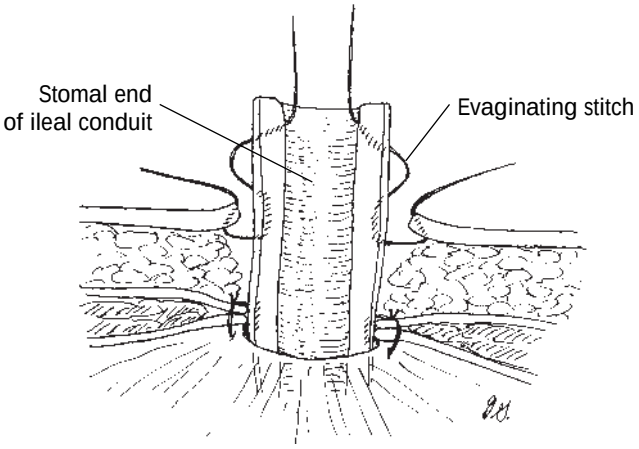

11-26

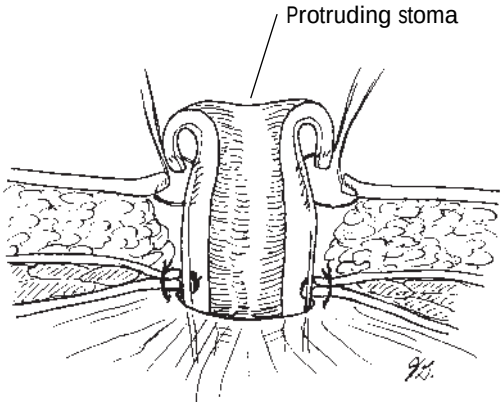

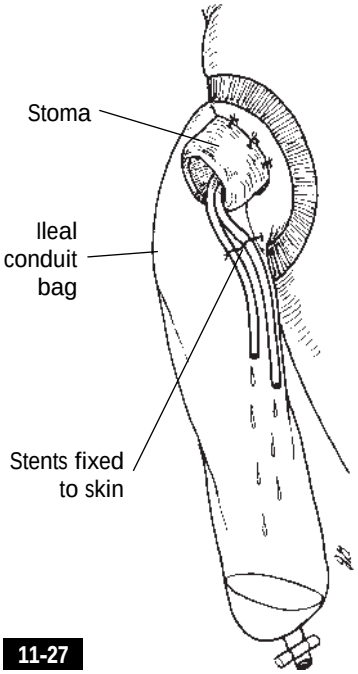

11-27

TURNBULL STOMA

FIG. 11-28. If the patient is excessively obese, it may be impossible to perform a traditional stomal procedure. In this situation a Turnbull stoma can be created.[8] The Turnbull stoma is similar to a loop ileostomy or colostomy. The distal end is closed and a loop of the ileal segment is brought out to the skin surface for fixation. Once the anterior rectus fascia is fixed to the ileum, the surgeon opens the exposed ileum and fixes the divided edge of the bowel to the skin.

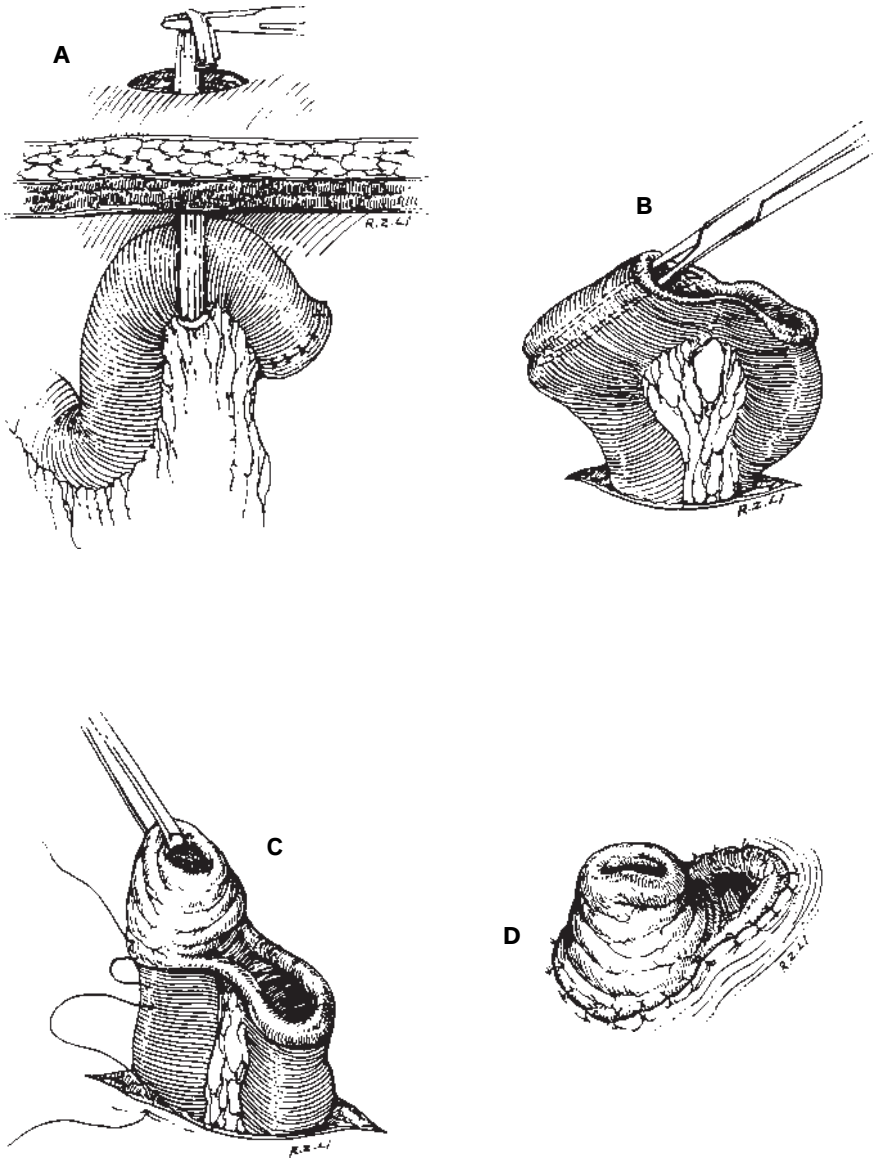

From Fowler JE Jr: *Manual of urologic surgery,* Boston, 1990, Little, Brown.

11-28

KEY POINTS

ILEAL CONDUIT

- The proper length of ileum to be used for the conduit with no tension at the ureteroileal anastomosis and with enough ileum for good stomal nipple creation is estimated.
- The mesentery is divided so that it is long at the stomal end and short at the blunt end.
- Bowel reanastomosis anterior to the ileal loop is performed.
- A Parker-Kerr stitch and a horizontal mattress stitch are used to close the proximal end.
- Careful attention is given to the ureteral spatulation and the first three vertex stitches of the anastomosis, which are the most critical.
- The stent is placed and fixed in position.
- The creation of a good stomal nipple requires circumferential fixation of the rectus fascia to the ileum with a second set of circumferential stitches to create the ileal evagination and nipple formation.
- Self-retaining stents should be fixed to the skin.

TRADITIONAL BOWEL REANASTOMOSIS

- Clamps are applied at an angle to avoid bowel ischemia.
- Two-layer closure is performed using either continuous stitch or a combination of a continuous and an anterior Connell stitch for the first layer and a horizontal mattress silk stitch for the second layer of closure with subsequent mesentery closure.
- Luminal patency is verified by finger palpation.

POTENTIAL PROBLEMS

ILEAL CONDUIT

- *Entire ileal conduit segment is dusky or ischemic:* Select another segment and start over
- *Ileal loop was placed anterior instead of posterior to reanastomosis of ileum:* Take down the mesentery and pass the ileal conduit segment posteriorly
- *Difficult left ureteral mobilization:* Check adequacy of the parietal peritoneal tunnel if the left ureter is free from adjacent tissue such as the gonadal vessels → make sure the inferior mesenteric artery is not obstructing the left ureteral transposition
- *Both ureters are short:* The ileal conduit segment must be made longer to accommodate this discrepancy
- *Stent accidentally falls out:* Replace the stent by opening the ureteral ileoanastomosis at the end opposite the vertex stitches
- *Ileal conduit nipple is too flat:* Check to see if primary stitches at the fascial level can be revised
- *Patient is obese and stomal nipple cannot be created:* Consider creating a Turnbull stoma

TRADITIONAL BOWEL REANASTOMOSIS

- *Bowel ischemia of two open ends:* Resect this area until good tissue is established → perform the anastomosis
- *Small luminal opening of end-to-end anastomosis:* Take down the anastomosis and perform a side-to-side anastomosis
- *Hematoma of mesentery:* Ligate the bleeding vessels or area with attention to preservation of the main vasculature

REFERENCES

1 Burgers JK, Quinlan DM, Brendler CB: Improved technique for creation of ileal conduit stoma, *J Urol* 144:1188, 1990.

2 Steichen FM, Ravitch MM: Mechanical sutures in operations on the small intestine. In Nelson RL, Ravitch MM, editors: *Surgery of the small intestine,* Norwalk, Conn, 1987, Appleton & Lange.

3 Steichen FM, Ravitch MM: Contemporary stapling instruments and basic mechanical suture techniques, *Surg Clin North Am* 64:425, 1984.

4 Abrams JS: Indications, operative techniques and patient care. In *Abdominal stomas: indications, operative techniques and patient care,* Boston, 1984, John Wright PSG.

5 Abrams JS: The abdomen and its contents. In *Abdominal stomas: indications, operative techniques and patient care,* Boston, 1984, John Wright PSG.

6 Mahoney EM, Harrison JH: Successful prevention of ileal conduit stomal stenosis: experience during a 12-year period, *J Urol* 123:475, 1980.

7 Mahoney EM, Kearney GP, Docimo SG: Cutaneous ureterostomy in adults, *Urology* 40:1, 1992.

8 Fowler JE Jr: *Manual of urologic surgery,* Boston, 1990, Little, Brown.

SUGGESTED READING

Nelson RL, Nyhus LM, editors: *Surgery of the small intestine,* Norwalk, Conn, 1987, Appleton & Lange.

CONTINENT DIVERSION: THE INDIANA POUCH

12

There are numerous surgical variations from which the surgeon may choose for performing a continent urinary diversion.[1-3] We believe the Indiana pouch to be the simplest and easiest of these procedures; it is associated with the fewest late postoperative complications.[4]

SELECTION OF INTESTINAL SEGMENT

FIG. 12-1. Although a 30 cm segment is the common recommendation, we have found that a 40 cm colonic segment is necessary for a pouch to hold 400 to 600 ml of urine. An ileal segment of 10 cm is used for the continent segment and stoma creation.

The ascending colon as well as part of the transverse colon must be freed. Before the selected bowel segment is divided, the omentum must be taken off the transverse colon. The more proximal side of the transverse colon must be mobilized for the ileocolonic anastomosis.

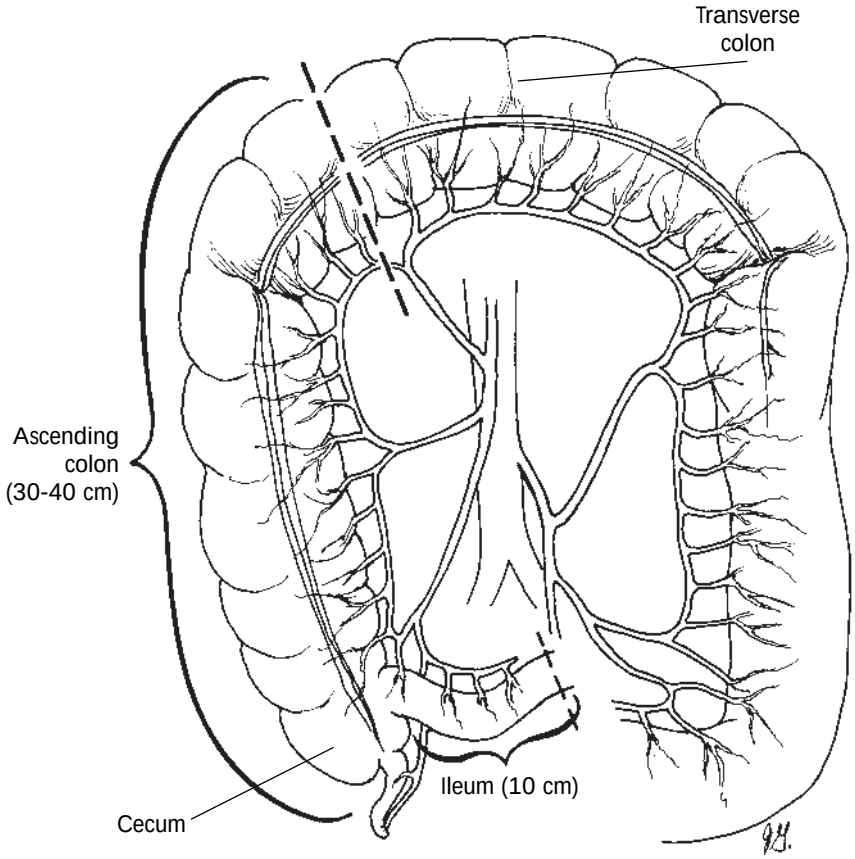

12-1

Variations in Colic Arteries

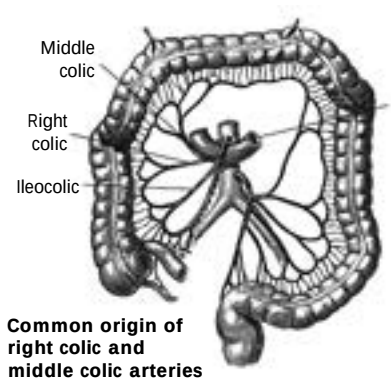

Common origin of right colic and middle colic arteries

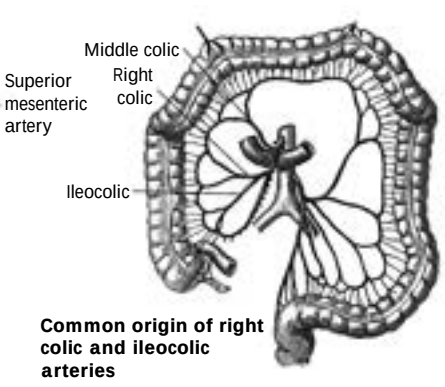

Common origin of right colic and ileocolic arteries

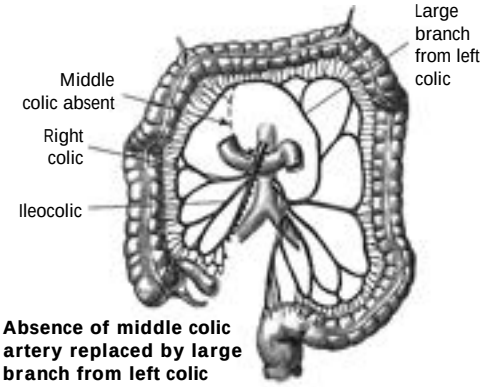

Absence of middle colic artery replaced by large branch from left colic

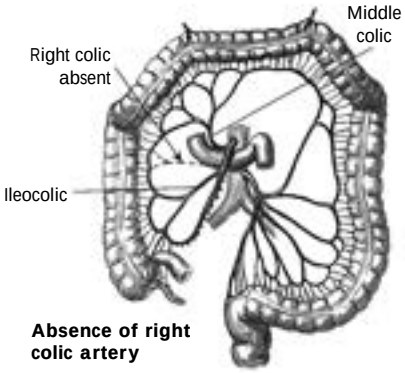

Absence of right colic artery

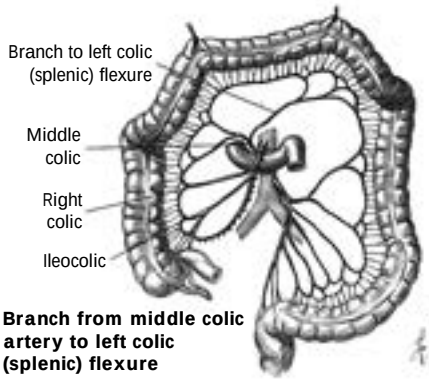

Branch from middle colic artery to left colic (splenic) flexure

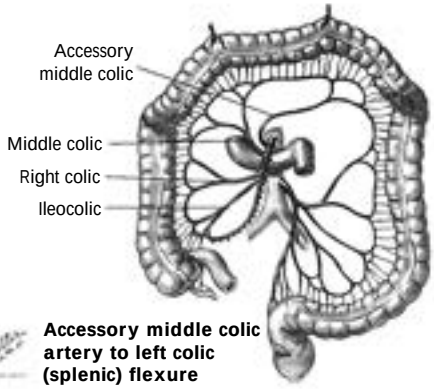

Accessory middle colic artery to left colic (splenic) flexure

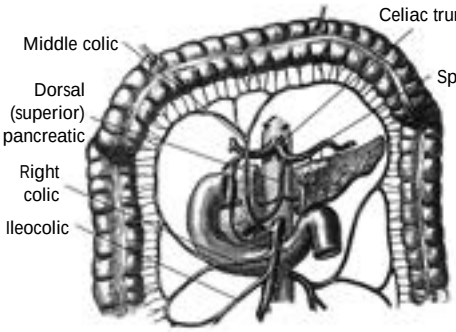

Middle colic artery originates from celiac trunk via dorsal pancreatic artery

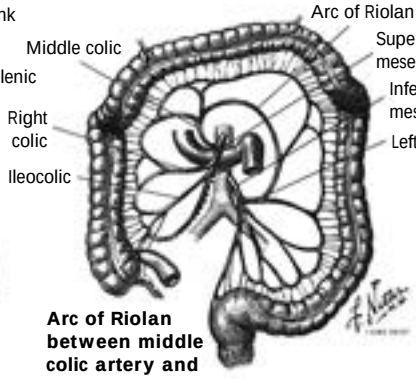

Arc of Riolan between middle colic artery and left colic artery

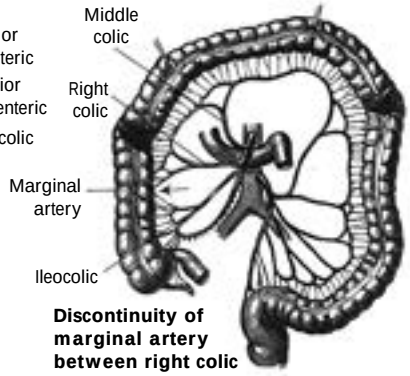

Discontinuity of marginal artery between right colic and ileocolic arteries

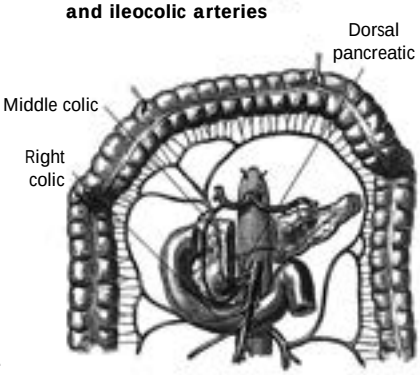

Middle colic artery gives origin to dorsal pancreatic artery

FIG. 12-2. There are many variations of the vasculature of the ascending and descending colon.[5]

DETUBULARIZATION OF COLONIC SEGMENT AND POUCH CREATION

The surgeon divides the entire antimesenteric length from part of the transverse colon all the way down to the cecum for complete detubularization.

Before dividing the antimesenteric side of the colon, the surgeon should consider the location of the cecostomy tube placement and the potential sites for the ureterocolonic anastomosis.

Depending on the type of ureterocolonic anastomosis to be performed, the location of the colonic teniae may be important.

FIG. 12-3. As many teniae as possible should be preserved with the antimesenteric division.

FIG. 12-4. The open colonic segment is folded and reapproximated with a running stitch (2-0 chromic) first and then a running horizontal mattress stitch (2-0 Vicryl).

FIG. 12-5. We prefer to use either straight-needle (Davis and Geck) sewing for creation of the pouch or a "no-forceps" curved-needle sewing technique because both are timesaving compared with traditional methods.

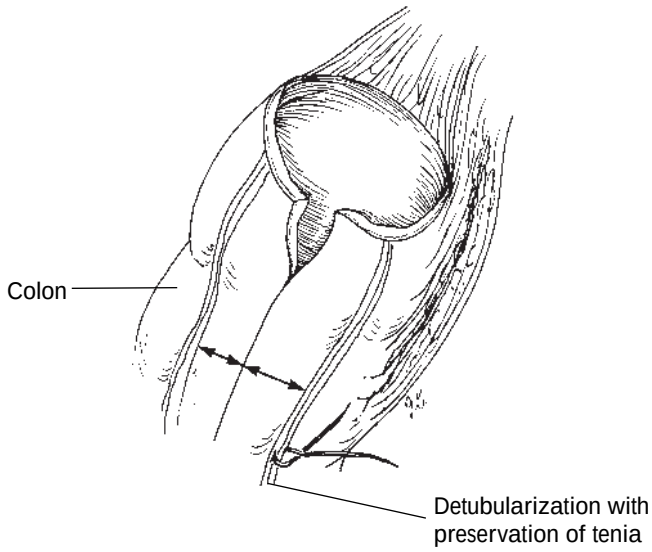

12-3

Complete Detubularization of Colon and Reapproximation

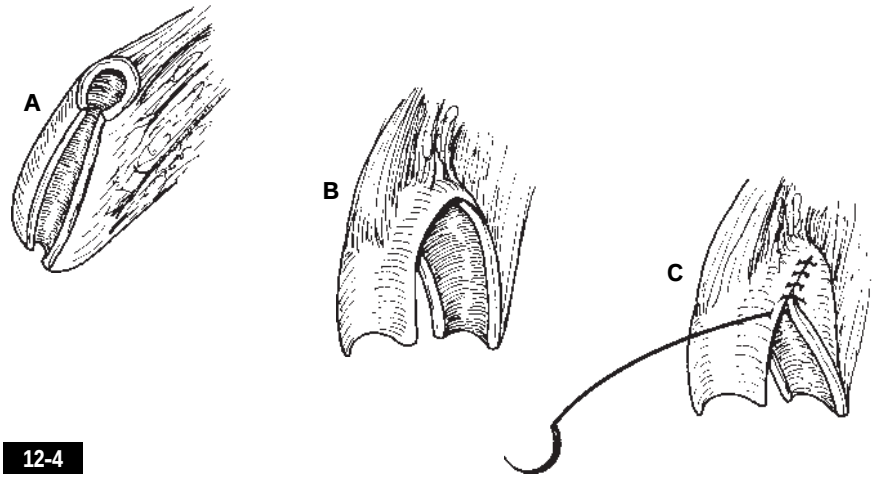

12-4

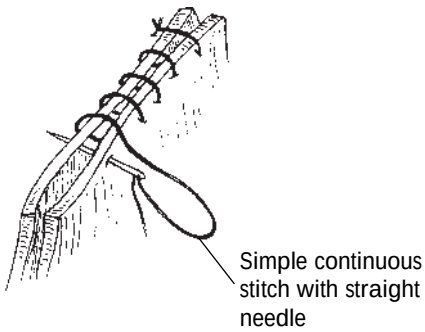

12-5

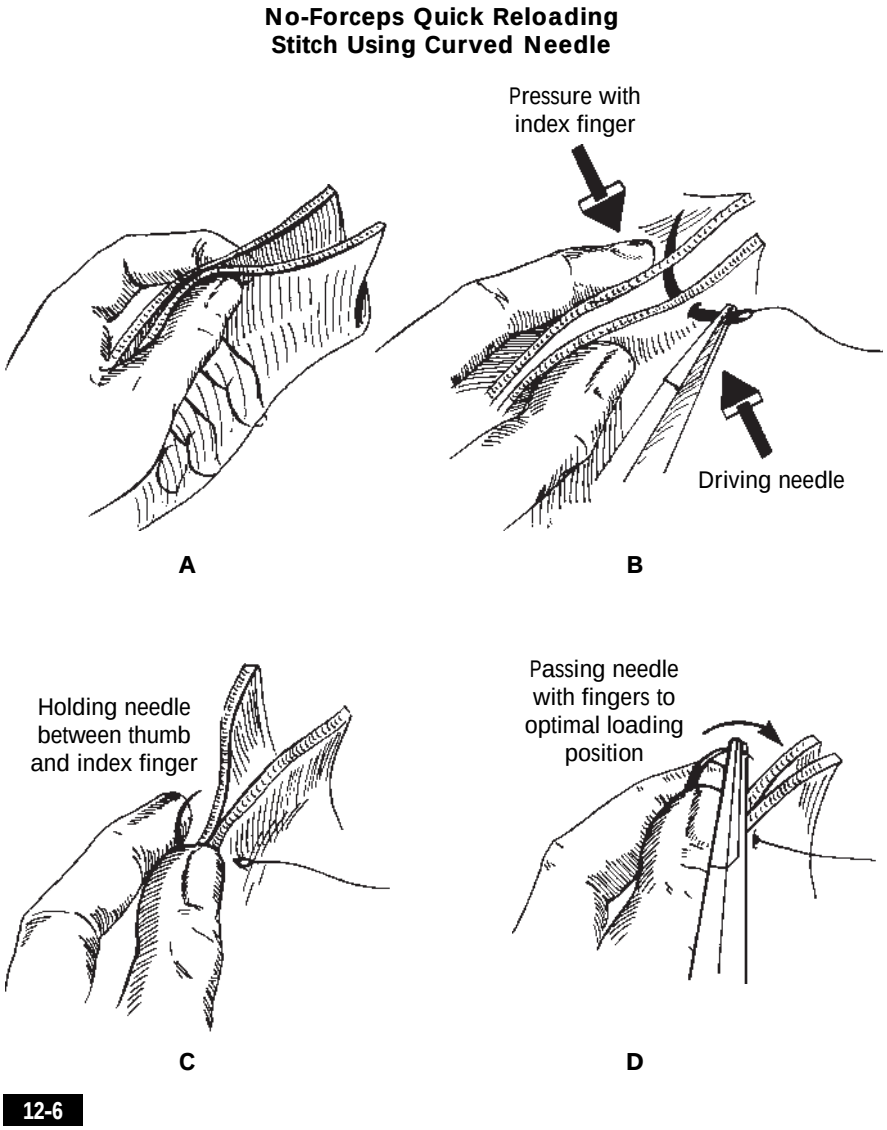

FIG. 12-6. With the no-forceps sewing technique, a right-handed surgeon uses the left thumb and index finger to secure the two layers of tissue to be sewn together **(A).** The other three fingers hold the bowel in place.

The surgeon's right hand drives the needle through the tissues while the left index finger and thumb apply slight counterpressure against it **(B).**

When the needle comes through the other side, the surgeon's left index finger and thumb grasp the needle while the right hand repositions the needleholder for the next stitch (**C** and **D**). In essence, this maneuver facilitates a continuous stitching motion with the right hand on the needleholder.

ABSORBABLE STAPLES FOR POUCH CONSTRUCTION

GIA 75 (Autosuture, U.S. Surgical, Norwalk, Conn.) absorbable staples are an excellent and quick way to construct the pouch.[6]

FIG. 12-7. After an opening is made in the cecum (**A** and **B**), the two arms of the stapler gun are passed into the folded lumen at the antimesenteric line **(C).**

The engaged stapler is discharged after satisfactory placement **(D).**

Detubularization and Pouch Construction Using Absorbable GIA 75 Staples

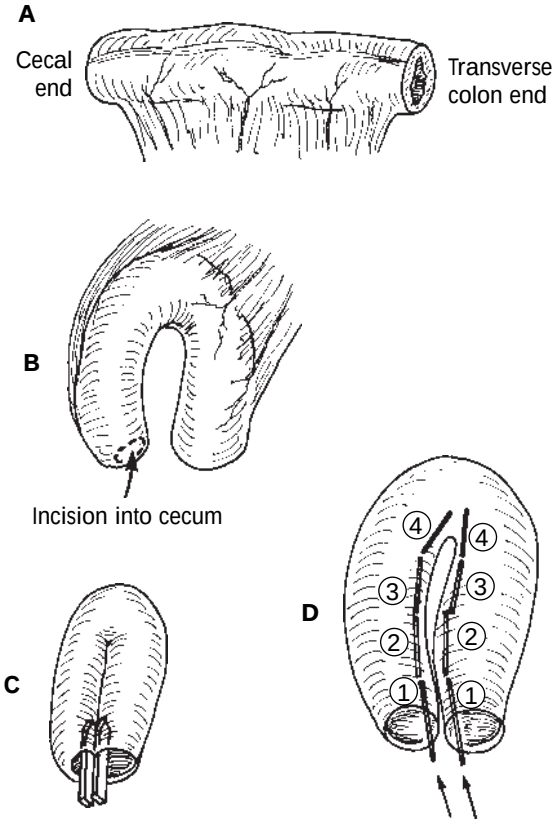

12-7

Three or Four Stapler Discharges Necessary for Pouch Construction

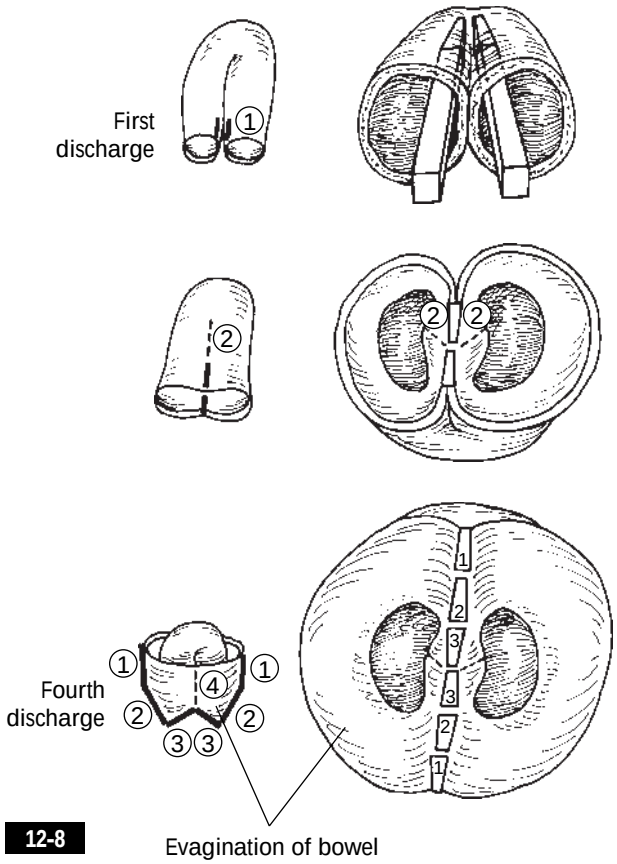

12-8

FIG. 12-8. On the average, three or four discharges using reloadable staples are necessary to complete the pouch.

FIG. 12-9. Redundant staples are cut off the distal end **(A).**

Because these staples are thick, the surgeon must clear a space at the crotch for the placement of the subsequent stapler **(B).**

These small spaces between the staples rarely require extra stitches.

We prefer to use this method over manual sewing for the creation of the Indiana pouch.

The pouch should be checked for fluid leakage at the staple lines after the pouch is completely closed.

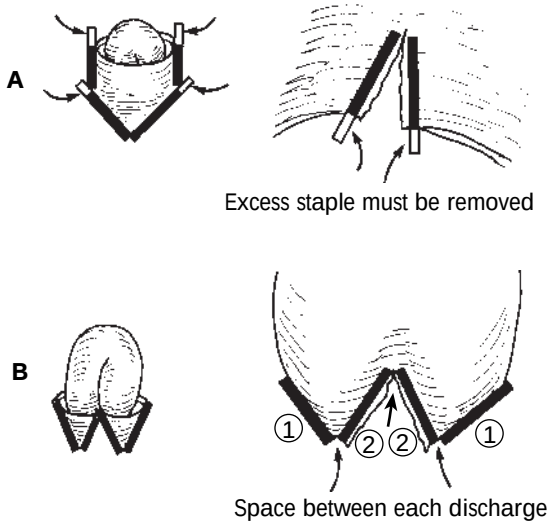

12-9

Incomplete Pouch Construction in Preparation for Ureterocolonic Anastomosis and Cecostomy Tube Placement

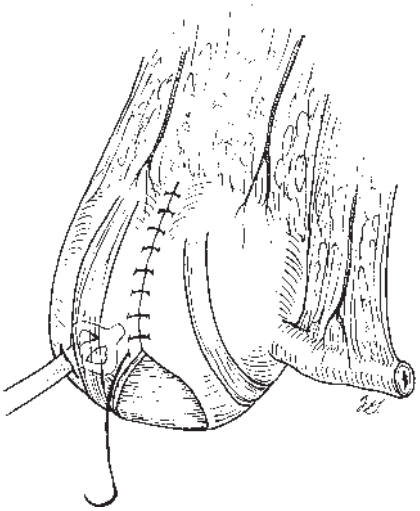

12-10

Ureterocolonic Anastomosis Using Teniae

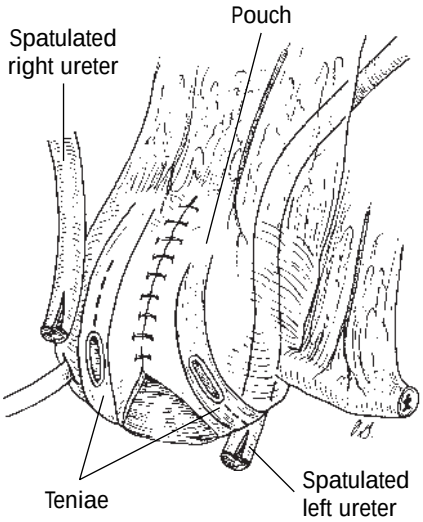

12-11

CECOSTOMY AND URETEROCOLONIC ANASTOMOSIS

FIG. 12-10. With the pouch placed in the right pelvic gutter, the surgeon selects the position for the placement of the cecostomy tube (Malecot or 26 Fr Foley catheter with a 30 ml balloon). The cecostomy tube is placed and secured with a pursestring stitch (0 chromic).

URETEROCOLONIC ANASTOMOSIS

The ureters have been clipped at the time of their division earlier in the operation and now have had time to become dilated and hydronephrotic. This dilated state makes spatulation and reimplantation of the dilated ureters simple.

On the left side, it is critical that the ureter have a gradual descent without any twisting. If the ureters have been clipped and dilated full of urine, they will not twist. If the ureters are open, the surgeon can pass an 8 Fr red rubber catheter or stent to the left kidney to prevent twisting.

If there is too much tension on the left ureter after it is brought through to the right side, the surgeon should reexamine the retroperitoneal tunnel to make sure that there are no sharp angles. The surgeon also should make sure that the ureter and its adventitia are free from the level of the left kidney down. The surgeon must decide the optimal position of the left ureteral anastomosis in relation to the pouch.

For the ureterocolonic anastomosis, we use either the Le Duc method or implantation through the teniae of the colon.

The advantage of traditional ureteral implantation is that a good, long antirefluxing segment is covered with the colonic teniae. The disadvantage is that after the pouch is created, there are few teniae in the correct position for ureteral implantation.

The advantage of the Le Duc procedure is its versatility in placement anywhere in the pouch. The disadvantage is the reconstruction of a less satisfying antirefluxing segment, which may be shorter than planned.

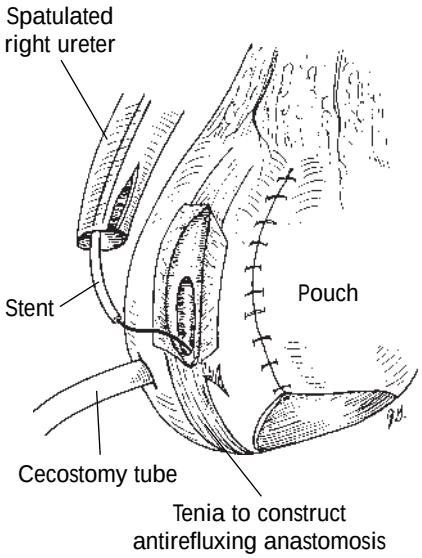

12-12

URETEROCOLONIC ANASTOMOSIS USING TENIAE OF COLON

FIG. 12-11. Teniae are selected, and the surgeon first addresses the more difficult left ureterocolonic anastomosis. We usually bring the left spatulated ureter under the pouch and into a position for implantation.

FIG. 12-12. Teniae should be opened with sharp dissection and should be undermined on either side approximately 4 cm.

Many techniques of implantation are available but the principle of ureteral spatulation and creation of an antirefluxing segment are the same. Spatulation ensures a wide-open anastomosis and the tunneled or fixed segment of 4 cm or more ensures the antireflux mechanism. Generally, a ratio of 1:4 (width of the ureter to the length of the tunnel) is a good rule.

After the spatulation has been accomplished, the first three

stitches at the vertex are the most important. The ureterocolonic anastomosis is completed using large stitches placed circumferentially around the ureter for support and fixation.

After the first three stitches are placed, the surgeon inserts a Bard 8 Fr ureteral diversionary stent up the ureter to the kidney and then brings it into the cecum and out the cecum through a separate opening. The surgeon then places a holding stitch (2-0 chromic) around the stent at the point where it exits the cecum. Any diversionary stent with a self-retaining mechanism at its proximal end is acceptable.

The undermined tenia can be reapproximated over the ureter to create an antirefluxing mechanism.

Le Duc ureterocolonic anastomosis is described in Chapter 13 (see p. 131).

TAPERING OF ILEAL SEGMENT AND STOMA CREATION

The pouch is completely closed after ureterocolonic anastomosis and cecostomy tube placement.

By instilling saline solution via the cecostomy tube, the surgeon can now test for pouch capacity and for any leakage at the suture lines.

Although rarely seen, any leakage at the open ileostomal end implies an incompetent ileocecal valve.

FIGS. 12-13 AND 12-14. In addition, the surgeon can now estimate the proper orientation of the stomal end for the shortest and easiest straight line for catheterization.

In general, the stoma will favor a position on the right side; however, we have had rare occasions in which the stoma favored either a midline position at the umbilicus or the left side.

FIG. 12-15. The ileal segment is 10 cm long. We insert a Foley catheter (14 Fr) with a balloon inflated to 15 ml with saline solution.

With the catheter balloon inflated, the location of the ileocecal valve can be palpated.

Temporary 2-0 chromic stitches are placed through the ileum and around the Foley catheter along the mesenteric border to hold the catheter in position. The stitches are spaced out and tied down without excessive tension. These holding stitches can be pulled out without difficulty after the stapling is performed. This maneuver helps to facilitate the stapling process and temporarily fixes the catheter in an optimal position against the intestinal wall.

Babcock clamps placed along the antimesenteric side are used for countertraction. The GIA 60 stapler is placed snugly against the catheter and engaged over the ileum. The surgeon should check for any undesirable angles or pockets before discharging the staples.

Testing for Optimal Placement of Stoma

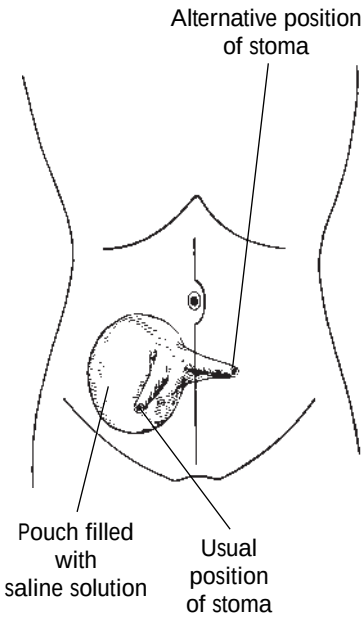

12-13

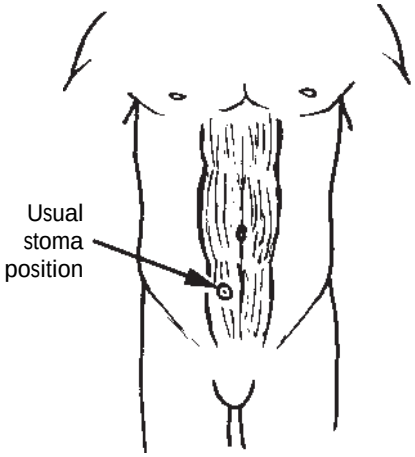

12-14

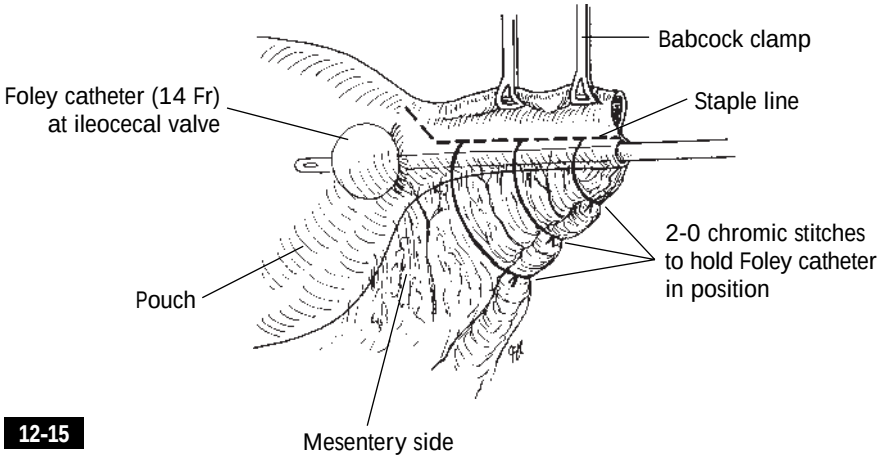

12-15

FIG. 12-16. It is absolutely critical that the newly created lumen be straight and have no sharp angles; otherwise self-catheterization will be difficult for the patient.

As the stapling approaches the end of the ileum and the cecum, diagonal stapling is sufficient. The diagonal stapling is close to the junction of the ileocecal valve. Simple stitches at the ileocecal junction over the staples are helpful.

FIG. 12-17. Often the fatty mesentery of the ileum may overlap the area for the stapling **(B).** The surgeon can simply dissect the fat and vessels from the ileum on either side while leaving the main branches in the middle (**C** and **D**). Once adequate space is established, the surgeon proceeds with the stapling **(E).**

The stoma should be flat against the abdominal skin.

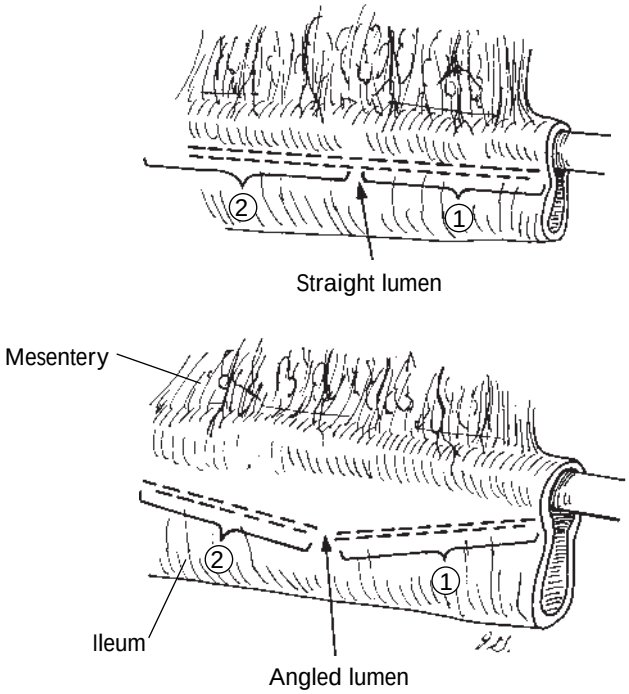

12-16

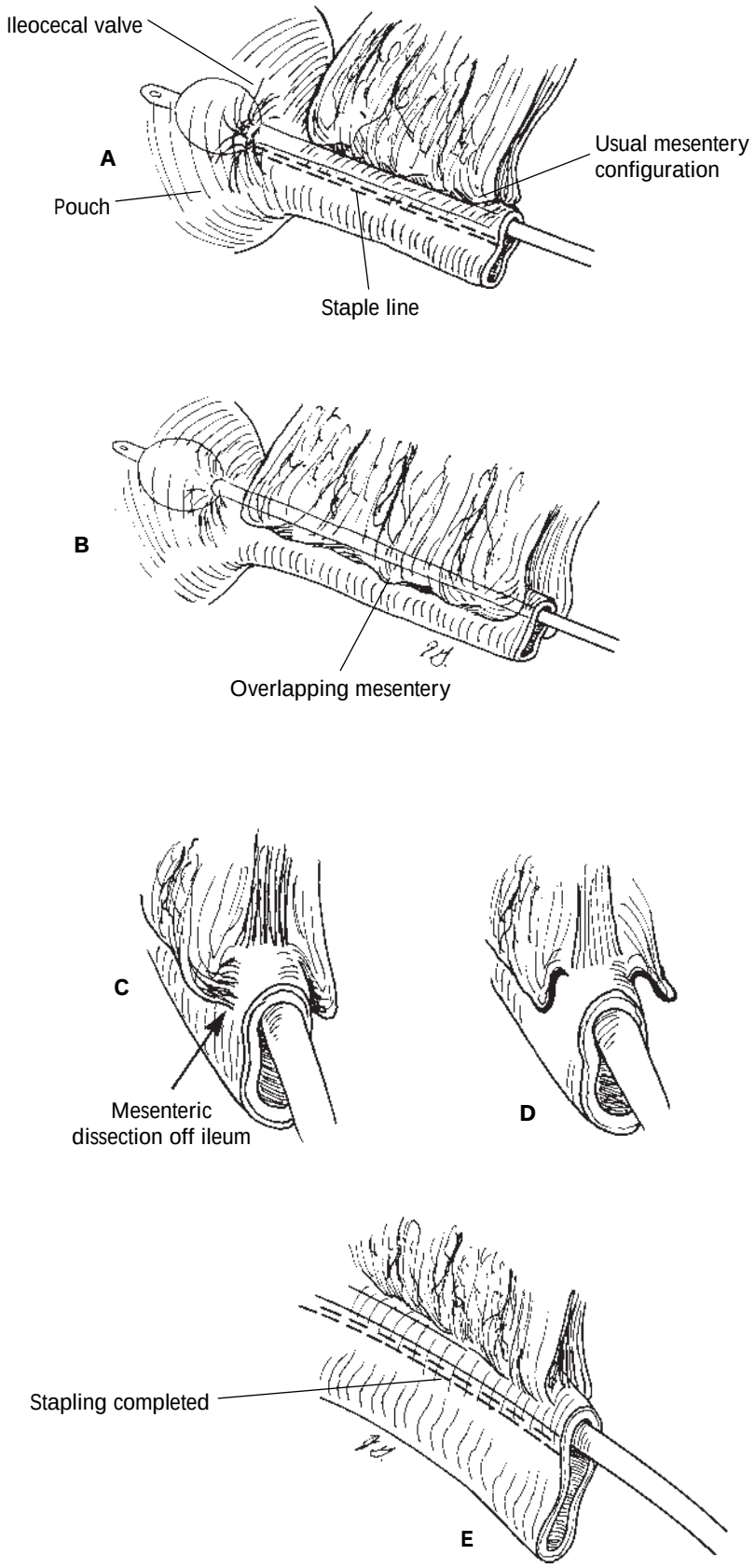
Ileocecal valve
A
Pouch
Usual mesentery configuration
Staple line
B
Overlapping mesentery
C
Mesenteric dissection off ileum
D
Stapling completed
E

12-17

KEY POINTS

- To create the pouch, a 30 to 40 cm colonic segment from the cecum up to the transverse colon and 10 cm of ileum are necessary.
- The selected bowel segment is divided and the transverse colon is mobilized.
- Detubularization of the colonic segment is performed and the pouch is constructed.
- The use of absorbable GIA 75 staples for pouch construction can be considered.
- Ureterocolonic anastomosis using the teniae of the colon or the Le Duc method is performed and a stent is placed.
- The cecostomy tube is placed and pouch closure is completed.
- The pouch is tested for capacity and leakage at suture or staple lines.
- The competence of the ileocecal valve is checked.
- Optimal placement of the stoma is determined.
- The ileal segment is tapered using a GIA 60 stapler over a Foley catheter (14 Fr).
- The stoma is flushed with the Foley catheter in place.

POTENTIAL PROBLEMS

- *Unexpected cecal or ascending colon lesion:* Use alternative ileal conduit and intraoperative general surgical consult (preoperative barium enema is useful in planning the surgery)
- *Difficulty bringing transverse colon down for anastomosis:* Mobilize transverse colon more and create a side-to-side anastomosis
- *Left ureter brought over to right side with some tension:* Mobilize ureter all the way up to the kidney → ensure that parietal peritoneal tunnel is wide → ensure that inferior mesenteric artery is not in the way
- *Unable to find suitable tenia for ureterocolonic anastomosis:* Use Le Duc procedure
- *Incompetent ileocecal valve:* Open pouch and add more sutures to fix the valve against the cecal wall
- *Angled tapering of ileum:* Redo the region

REFERENCES

1 Skinner DG, Boyd S, Lieskovsky G, et al: Lower urinary tract reconstruction following cystectomy: experience and results in 126 patients using the Kock ileal reservoir with bilateral ureteroileal urethrostomy, *J Urol* 146:756, 1991.

2 Fisch J, Wammack R, Muller SC, et al: The Mainz pouch II (Sigma rectum pouch), *J Urol* 149:258, 1993.

3 Cedron M, Gearhart JP: The Mitrofanoff principle: technique and application in continent urinary diversion, *Urol Clin North Am* 18:615, 1991.

4 Rowland RG, Bihrle R, Scheidler D, et al: Update on the Indiana continent reservoir, *Prob Urol* 5:269, 1991.

5 Netter FH, Colacino S: Variation of colic arteries. In *Atlas of human anatomy*, Summit, NJ, 1994, Ciba-Geigy.

6 Olsson CA, Kirsh AJ, Whang MIS: Rapid construction of right colon pouch, *Curr Surg Tech Urol* 6(3):1, 1994.

SUGGESTED READINGS

Kock NG, Ghoneim MA, Lycke KG, et al: Urinary diversion to the augmented and valved rectum, *J Urol* 140:1375, 1988.

Steiner MD, Morton RA: Nutritional and gastrointestinal complications of the use of bowel segments in the lower urinary tract, *Urol Clin North Am* 18:743, 1991.

ILEONEOBLADDER (HAUTMANN TYPE)

13

BOWEL DETUBULARIZATION AND W FORMATION

FIG. 13-1. From a point 20 cm proximal from the ileocecal valve, 60 to 70 cm of the bowel is measured. This segment and its mesentery are divided to accommodate its placement in the pelvis. The bowel is reanastomosed posterior to the ileoneobladder segment.

FIG. 13-2. The 60 to 70 cm small bowel segment is folded into a W formation and temporarily fixed with 2-0 stay sutures *(1)*. The right arm of the W formation *(2)* should be longer and should be placed lower than the left arm since it will be used as the neobladder neck to be anastomosed to the distal urethral stump.

After the bowel is opened and cleared of its contents by saline solution irrigation, it is divided at its antimesenteric line *(3)* for detubularization. The surgeon places the left index finger within the lumen and maintains tension against the antimesenteric line of the bowel while the right hand applies the Bovie cutter to open the bowel.

At the lower arm of the W formation, the detubularization is *not* performed at the antimesenteric line. At this point it is critical that the surgeon divide the bowel heading toward the mesenteric side, thus creating a lip or a flap at the lowermost part of the W formation *(4)*. This lip of extra tissue will be important not only to create the neobladder neck but also to add extra length to reach the distal urethral stump with this W formation.[1]

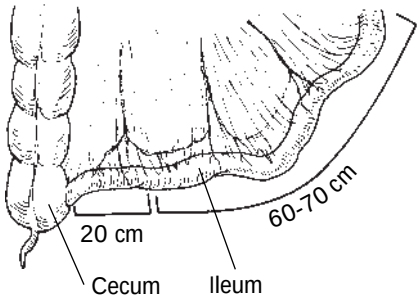

13-1

Division of Ileum

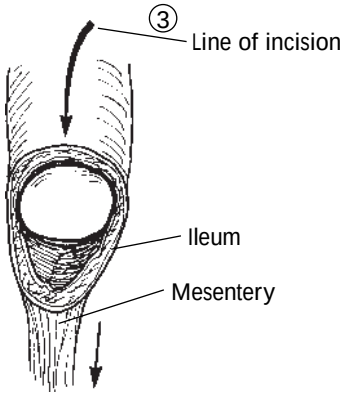

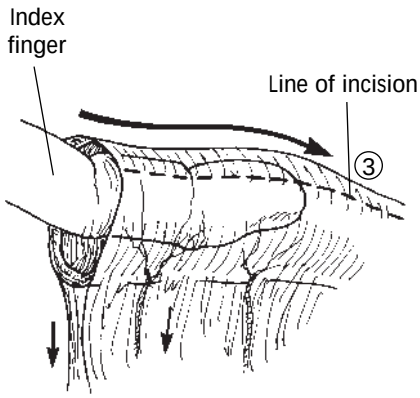

Modified W Formation

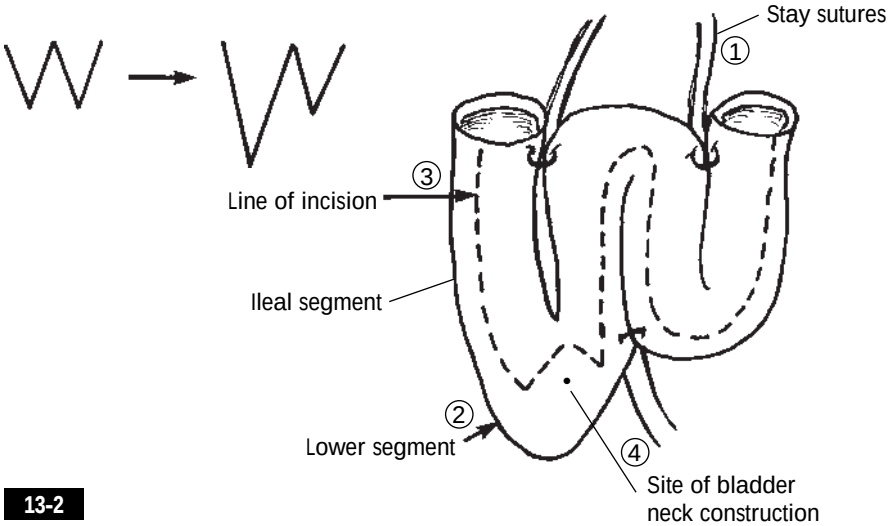

13-2

FIG. 13-3. The edges of the divided bowel are sewn together **(A).** The simplest and fastest approach is to perform a continuous stitch (2-0 Vicryl) using an atraumatic straight needle (Davis & Geck). An alternative maneuver is to use a "quick reloading" technique with a half-circle needle (see p. 122). Absorbable staples are awkward to apply and not efficient for the creation of this neobladder.

For the neobladder neck, there are two reconstructive options: at the lowermost W configuration of the neobladder, the surgeon can (1) simply puncture the lip **(B)** or (2) create a neobladder neck by sewing together the cut edges, thus gaining another 2 to 3 cm in length and bringing the neck closer to the distal urethral stump **(C).** We prefer the latter option. If tension already exists when the neobladder is placed down into the pelvis, this extra 3 cm can be critical in producing the desired outcome.

While checking for tension of the mesentery and the bladder neck when the neobladder is in the pelvis, the surgeon should also estimate the position of ureterointestinal anastomoses on the middle and left leaves of the W formation.

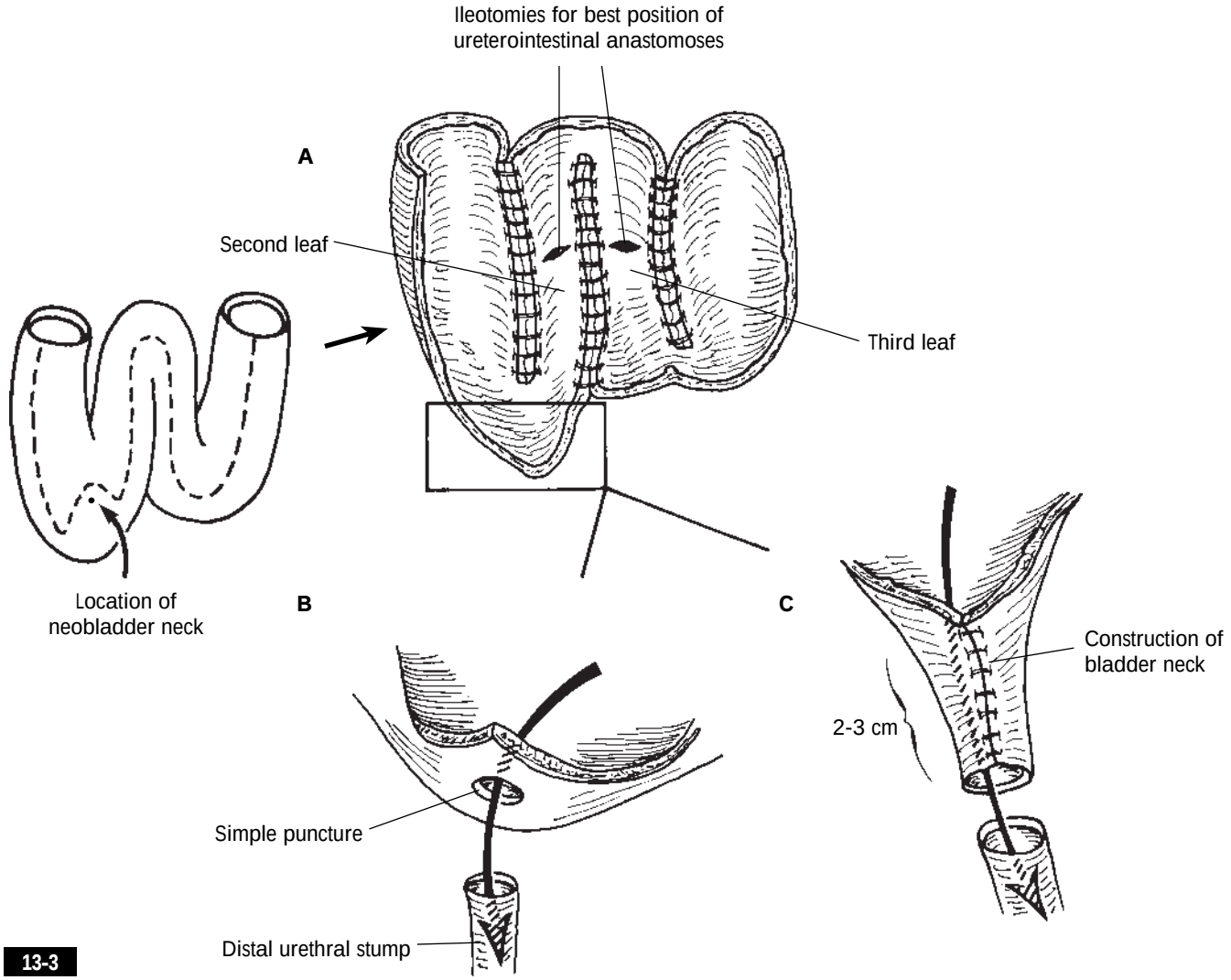

13-3

URETERAL DISSECTION

As previously discussed in the section of radical cystectomy (see p. 85), the avascular line of Toldt is incised and both ureters are isolated. We continue the right incision around the cecum and up the mesenteric root. This maneuver makes the left ureteral tunneling much easier and shorter (see p. 85).

As in all urinary diversions, whether an ileal conduit, continent pouch, or neobladder, the more difficult ureteral anastomosis is always the left side. Therefore the surgeon should make sure that the left ureter and its adventitia are free up to the level of the lower pole of the kidney. The posterior parietal peritoneal tunnel must be wide enough to avoid any ureteral angulation, and the inferior mesenteric artery should not obstruct the passage of the left ureter to the right side. Some surgeons bring the ureter anterior to the peritoneum, but we prefer the peritoneal tunneling approach.[2,3] By the time the cystectomy has been completed, the ureters will have become dilated with hydronephrosis if clipped as soon as the ureters are divided. This maneuver not only makes the ureterointestinal anastomoses easier but also prevents the ureters from twisting.

URETEROINTESTINAL ANASTOMOSES

It is important that the surgeon estimates the best position of the ureteral implantation while the neobladder is down in the deep pelvis.

In general, the left ureter is brought in on the left segment, whereas the right ureter is brought in on the middle segment of the W formation (see Fig. 13-3, **A**). It is better to make the ureteral entry too high than too low in the neobladder, thus avoiding ureteral tension, especially of the left ureter.

LE DUC URETEROINTESTINAL ANASTOMOSIS

The left ureterointestinal anastomosis should be completed first because it is the more difficult to perform.

FIG. 13-4. The puncture of the neobladder for the ureteral implantation must be wide enough so that the ureter can slide back and forth freely. A common error is to make this puncture too small.

While the assistant applies traction upward on a ¼- to ½-inch (0.5 to 1 cm) Penrose drain through the puncture site, the surgeon secures the thumb and index finger over the bowel segment, which is wrapped around a cylindric tube (i.e., Poole suction device).

After injecting saline solution into the mucosa, the surgeon cuts away a trough of mucosal and submucosal tissues.

Le Duc Ureterointestinal Anastomosis

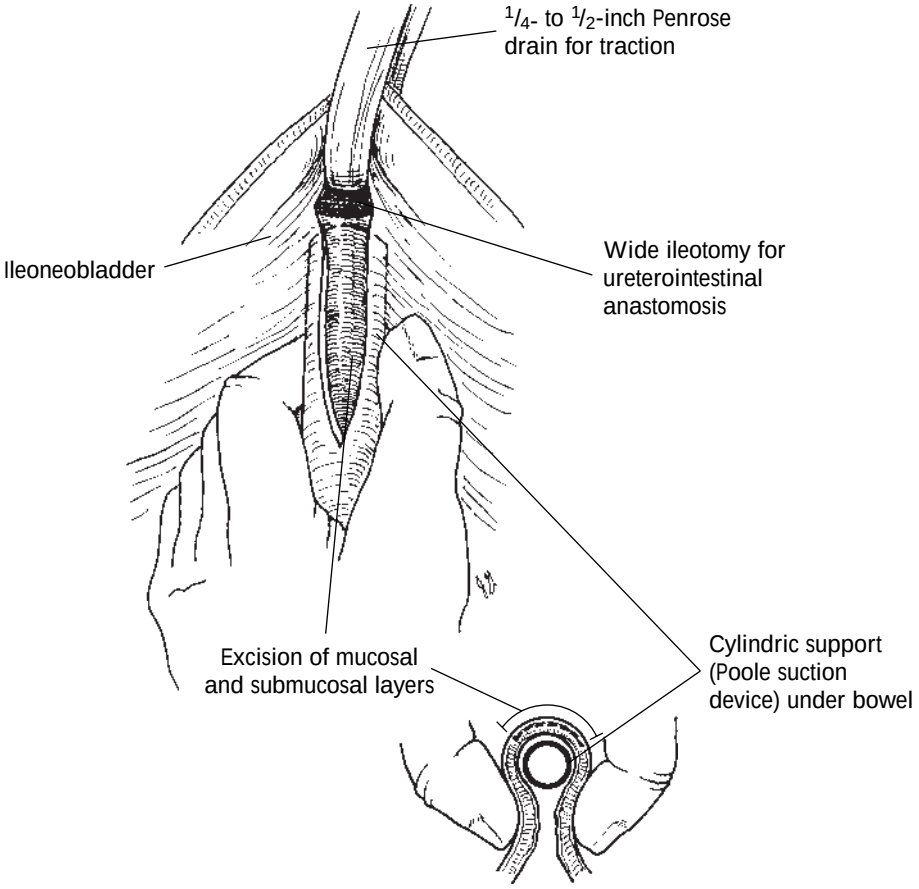

13-4 **Cross-sectional View**

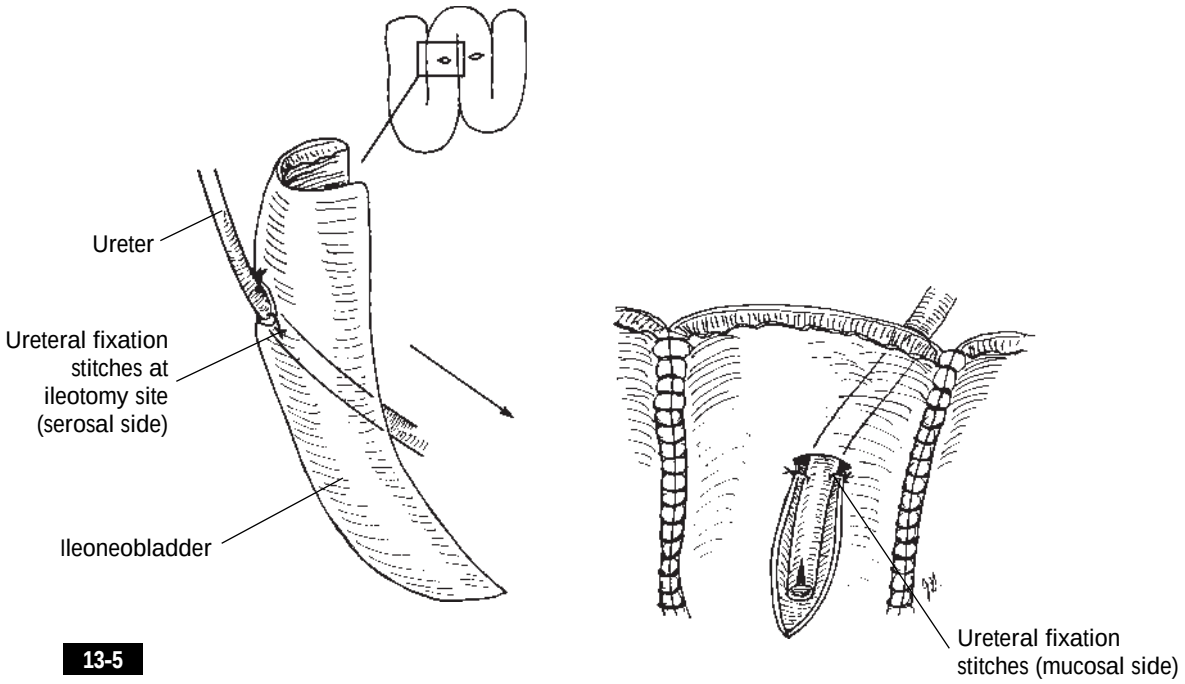

Alternative Methods of Mucosoureteral Approximation (Cross-sectional Views)

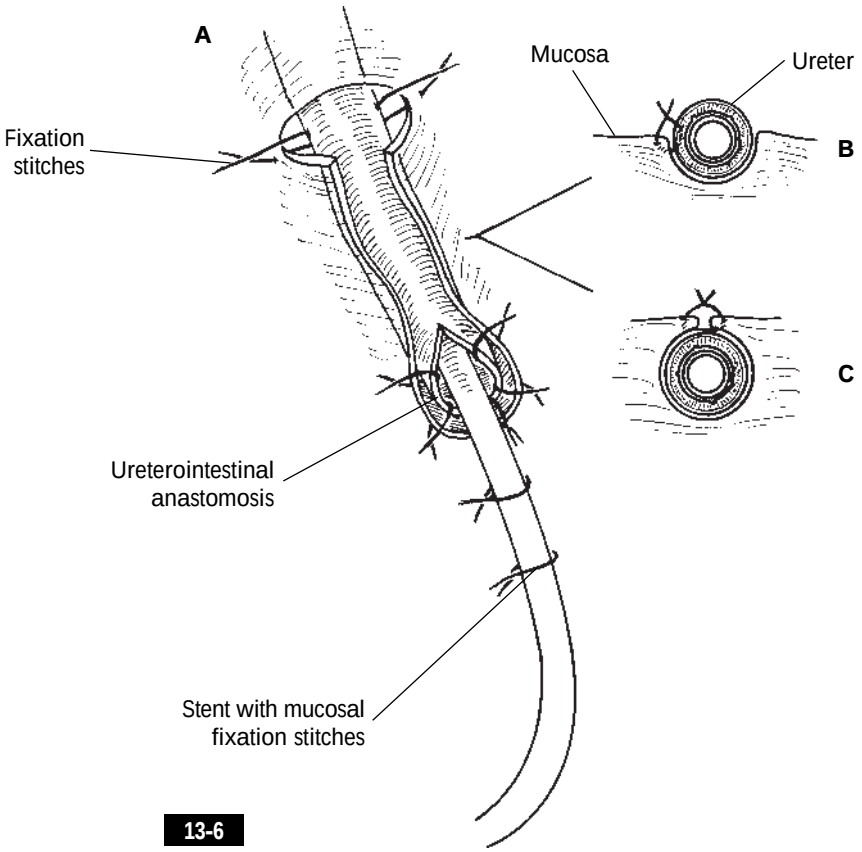

FIG. 13-5. The ureter is brought through the intestinal puncture site and fixed on both the serosal and the mucosal sides to prevent retraction. The surgeon must avoid strangulation of the ureteral vasculature by these fixation stitches.

FIG. 13-6. The spatulated ureteral meatus is fixed to the intestinal trough with deep stitches (4-0 Vicryl) and a Bard diversionary stent (8 Fr) is passed up to the kidney **(A).** The stents are fixed to the ileoneobladder with stitches (4-0 chromic).

According to Le Duc,[4,5] there are two options for mucosoureteral antirefluxing fixation. The intestinal mucosa can be approximated against the two sides of the ureter **(B)** or, if there is redundant intestinal mucosa, the two edges of the mucosal layer can be approximated over the ureteral segment **(C).**

NEOBLADDER NECK AND DISTAL URETHRAL STUMP APPROXIMATION

FIG. 13-7. Before the neobladder is placed into the pelvis for the neobladder neck–urethral anastomosis, the distal half of the neobladder should be reapproximated with a running stitch (2-0 Vicryl) because it will be impossible to close once it is in the deep pelvis **(A).**[1,6]

A Malecot catheter (24 or 26 Fr) is inserted at the top of the neobladder, and stents are brought through separate stab wounds or through the incision line. The upper half of the neobladder is left open until the neobladder neck–urethral anastomosis is completed **(B).**

NEOBLADDER NECK–URETHRAL ANASTOMOSIS

A Foley catheter (18 Fr with 5 ml balloon) is passed from the urethral meatus through the neobladder neck.

Four to six anastomotic stitches (2-0 Vicryl) are placed circumferentially but are not tied.

The Foley catheter balloon is inflated to 10 to 15 ml, providing sufficient but not excessive traction to tie the anastomotic sutures down.

After inspection of all anastomoses, the upper half of the neobladder is closed. With the Foley catheter clamped shut, saline solution is infused through the Malecot catheter to fill the neobladder so that leakage at the suture lines can be checked.

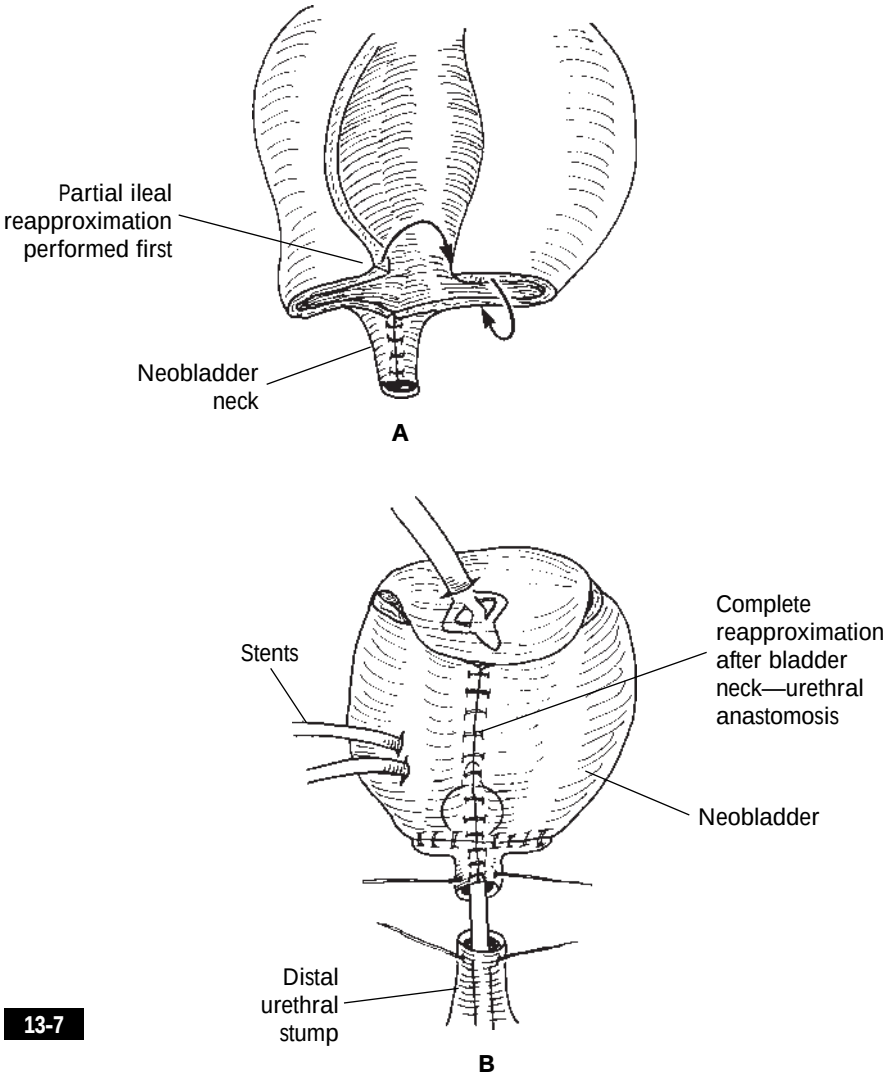

13-7

KEY POINTS

- A small bowel segment 60 to 70 cm in length is used to create the pouch.
- The bowel is reanastomosed posterior to the neobladder.
- A W formation of the small bowel is constructed with an exaggerated droop of the right arm to serve as the bladder neck.
- In detubularization, a flap or lip is constructed at the most dependent position of the W formation (right) for the neobladder neck–urethral anastomosis.
- The left ureter must be free all the way to the lower pole of the kidney and tunneled behind the posterior parietal peritoneum.
- The location of the ureterointestinal anastomoses must be estimated.
- The distal half of the ileoneobladder should be closed before the distal neobladder neck–urethral anastomosis is performed. A Malecot catheter is placed proximally, and the stents are inserted.
- A Foley catheter (18 Fr with a 5 ml balloon) is passed through the neobladder neck, and the anastomotic stitches are placed.
- The remaining open portion of the proximal neobladder is closed.

POTENTIAL PROBLEMS

- *Diseased small bowel:* Use an Indiana pouch or ileal loop conduit diversion
- *Neobladder does not reach urethral stump:* Check for asymmetric W formation with lower right arm → create a bladder neck by anastomosis of the intestinal flap, if necessary
- *Left ureter is under tension:* Free ureter up to the kidney → ensure that posterior peritoneal dissection has no sharp angles
- *Inferior mesenteric artery syndrome* (see p. 65): Consider bringing the ureter to the anastomotic site via an anterior position rather than through a retroperitoneal tunnel

REFERENCES

1 Fair WR: Personal observations and communications, May 1995.

2 Hautmann RE et al: The ileal neobladder: 6-years' experience with more than 200 patients, *J Urol* 150:40, 1993.

3 Miller K et al: The ileal neobladder: operative technique and results, *Urol Clin North Am* 18(4):623, 1991.

4 Le Duc A, Camey M, Teillac P: Original antireflux uretero-ileal implantation technique: long-term follow-up, *J Urol* 137:1156, 1987.

5 Le Duc A: Mucosal groove antireflux uretero-ileal implantation. In Hohenfellner R, Wammack R, editors: *Société internationale d'urologie reports: continent urinary diversion*, London, 1992, Churchill Livingstone.

6 Fair WR: The ileal neobladder, *Urol Clin North Am* 18(3):555, 1991.

SUGGESTED READING

Hautmann RE et al: The ileal neobladder, *J Urol* 139:39, 1988.

14

General Points and Concepts in Surgical Procedures for Stress Incontinence

GENERAL CONSIDERATIONS

Objective

The objective of any suspension procedure is to *bring the bladder neck back to the intraabdominal position*. It is not necessary to lift the bladder neck to a maximally elevated position.

Optimal Position at Bladder Neck

Whether using a retropubic approach or a vaginal approach from below, *the proper estimation of the position of the bladder neck is crucial to the success of surgical repair for stress incontinence.*

If stitches are placed *too distally* to the bladder neck, postoperative urinary retention results. Although this problem is usually temporary, it can be prolonged. If stitches are placed *too proximally* to the bladder neck, stress incontinence may not be corrected. Proximal stitches can also potentially injure the bladder.

Compressive Effect on Urethra by Stitch Placement

If the stitches are placed *too close to the urethra,* there is a compressive effect, which leads to temporary urinary retention. Therefore the operations with the more laterally placed stitches at the bladder neck, such as the Raz needle suspension procedure and the modified Burch procedure, have the advantage of causing no urethral compression.

Optimal Correction by Suspension

If the surgeon is using a needle suspension procedure from a vaginal approach, the goal is to eliminate the *hypermobility* of the bladder neck area. Therefore lifting the sutures so the bladder neck rests parallel to the floor of the operating room generally corrects the stress incontinence. *It is not necessary to coapt the bladder neck* or to lift it to the maximum.

Intrinsic Incompetence of Bladder Neck

In the special case of an incompetent bladder neck in which the bladder neck and proximal urethral musculature is dysfunctional, *a compressive effect and correction of the position of the bladder neck are needed.* The sling operation as well as the American Medical System (AMS) 800 incontinence prosthesis have compressive effects. The sling operation may cause temporary urinary retention, and the AMS 800 operation requires a period of cuff deactivation.

The comparative efficacy of collagen injections has yet to be borne out.

Variations in Procedures for Stress Incontinence

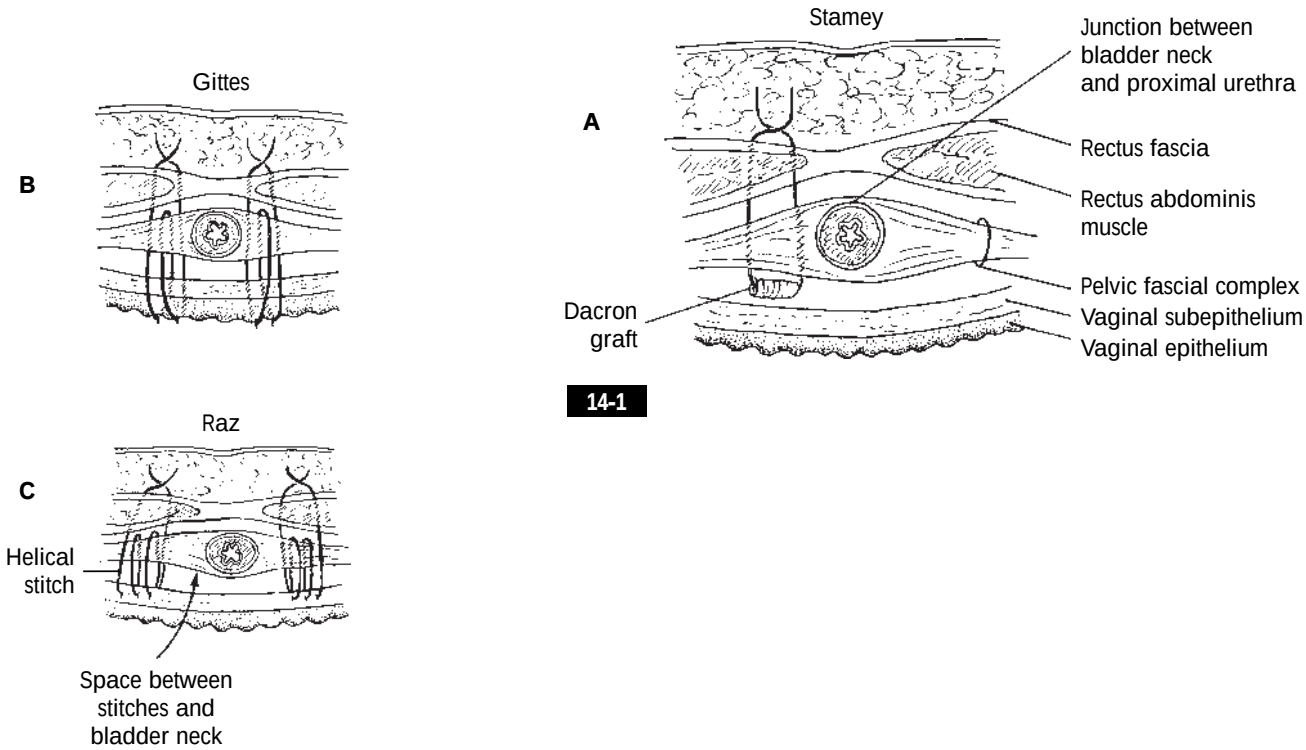

14-1

Stress Incontinence–Associated Cystocele

Along with stress incontinence, often there is an associated cystocele or enterocele. If the cystocele is of moderate caliber, it can be corrected by the modified Burch procedure or by a four-corner Raz procedure. However, if there is a large cystocele, a vaginal approach with a combination of a Raz suspension procedure and a correction of the cystocele and/or enterocele may be necessary.

DIFFERENCES BETWEEN SUSPENSION PROCEDURES FOR FEMALE STRESS INCONTINENCE

Stamey Procedure

FIG. 14-1, A. The suspension sutures penetrate the rectus fascia, rectus abdominis muscle, and pelvic fascial complex (pelvic urethral ligament and endopelvic fascia) and then loop back up to the rectus fascia for the anchoring stitch. The sutures are passed through a circular Dacron sleeve at the level between the pelvic fascial complex and the vaginal epithelium; thus the sutures never penetrate the vaginal epithelium. The sutures are placed close to the urethra at the bladder neck.

Gittes Procedure

FIG. 14-1, B. The supporting helical stitches penetrate the rectus fascia, rectus abdominis muscle, pelvic fascial complex, and vaginal epithelium. The vaginal epithelium will grow over the stitches. The stitches are placed close to the urethra at the bladder neck and are anchored on the rectus fascia.

Raz Procedure

FIG. 14-1, C. The sutures penetrate the endopelvic fascia, pelvic fascial complex, and vaginal subepithelium. The helical fascial stitches are placed more *laterally* than in the Stamey or Gittes procedures. The anchoring stitches are placed on the rectus fascia close to the midline.

Modified Burch Procedure

FIG. 14-1, D. The stitch penetrates the endopelvic fascia from the abdominal side, pelvic fascial complex, and vaginal subepithelium. The stitches are placed more laterally as in the Raz procedure. The sutures are anchored more *laterally* to the Cooper's ligament rather than to the pubic ostium as for the Marshall-Marchetti-Krantz repair. The vaginal fascial complex is suspended on *but does not touch the Cooper's ligament*. This procedure corrects stress incontinence and medium-sized cystoceles.[1]

Marshall-Marchetti-Krantz Operation

FIG. 14-1, E. The stitches penetrate the endopelvic fascia, pelvic fascial complex, and vaginal subepithelium as in the modified Burch procedure. The stitches are placed closer to the bladder neck and urethra and more distally than the modified Burch procedure. The anchoring stitches are placed at the pubic ostium.

Sling Procedure

FIG. 14-1, F. For the sling operation described by Blaivas,[2] a segment

TABLE 14-1
Suspension Procedures for Stress Incontinence

Operation	Suspension Stitches at Bladder Neck	Structure to Which Suspension Stitches Are Anchored	Features and Complications
Marshall-Marchetti-Krantz	Stitches close to urethra at bladder neck	Pubic ostium	Postoperative urinary retention Potential ostitis pubis
Modified Burch procedure	Stitches lateral to urethra at bladder neck	Cooper's ligament	Correction of associated medium-sized cystocele Abdominal incision Postoperative urinary retention rare
Stamey suspension	Prolene stitches and Dacron graft close to urethra at bladder neck	Rectus fascia	Postoperative urinary retention Dacron sleeve may migrate Not used for associated medium-sized cystocele
Gittes suspension	Stitches close to urethra and through vaginal epithelium	Rectus fascia	Relatively simple procedure Vaginal epithelium overgrows stitches
Raz suspension	Helical stitches lateral to urethra at bladder neck	Rectus fascia	Four-corner Raz procedure for associated medium-sized cystocele
Sling procedure	Sling placed lateral to urethra at bladder neck	Rectus fascia	For type III stress incontinence Compressive effect on urethra Dissection similar to Raz procedure
AMS 800 incontinence prosthesis	Cuff around urethra at bladder neck	—	For type III stress incontinence Difficult dissection to get around bladder neck Prevention of infection with antibiotics Compressive effect on urethra Period of deactivation necessary

of rectus fascia is tunneled through the endopelvic fascia and the pelvic fascial complex, around the urethra at the bladder neck, and back up to the rectus abdominis muscle on the contralateral side. This procedure is similar to the Raz procedure except that the fascial segment has a compressive effect on the urethra.

• • •

In the Marshall-Marchetti-Krantz, Stamey, and Gittes procedures, the bladder neck stitches are placed close to the urethra. In the Raz and modified Burch procedures, the bladder neck stitches are placed more *laterally*. The first three operations are prone to cause urinary retention in the immediate postoperative period. Refer to Table 14-1 for a comparative chart of the procedures for stress incontinence discussed in this chapter.

REFERENCES

1 Tanagho EA: Colpocystourethropexy: the way we do it, *J Urol* 116:751, 1976.

2 Blaivas JG: Commentary—pubovaginal sling procedure. In Whitehead ED, editor: *Current operative urology*, Philadelphia, 1990, JB Lippincott, pp 93-99.

SUGGESTED READING

Reynolds CL, Miller HC: Subpubic urethropexy: a new remedy for stress incontinence, *J Urol* 111:361, 1974.

RAZ, SLING, AND ARTIFICIAL SPHINCTER PROCEDURES

15

RAZ PROCEDURE

Position of Bladder Neck

FIG. 15-1. There are two methods that can be used to determine the position of the bladder neck. The first involves inserting a Foley balloon catheter through the urethra just into the bladder, filling the catheter with 10 ml of water, and then palpating to locate the bladder neck. The size of the catheter used is crucial to the effectiveness of this technique. A 5 ml Foley balloon catheter has a different configuration than a 30 ml balloon catheter. When filled with 10 ml of water, the 30 ml balloon catheter will have a fusiform balloon form and will not fit snugly against the bladder neck. In contrast, when a 5 ml balloon catheter filled with 10 ml is used, the surgeon is able to palpate a clear delineation between the proximal urethra and the bladder neck.

FIG. 15-2. Another way to estimate the location of the bladder neck is to measure its distance from the urethral meatus. After inflating the balloon in the bladder, the surgeon places a hemostat at the level of the meatus. Then by deflating the balloon and removing the catheter, the surgeon can measure the distance between the hemostat and the balloon and estimate the position of the bladder neck.

If a suprapubic tube is desired, it can be placed initially or at the termination of the procedure. We prefer to simply place a Foley catheter via the urethra at the completion of the operation.

FIG. 15-3. An easy method for Foley catheter placement is first to fill the empty bladder with 300 ml of saline solution. With the patient in the Trendelenburg position, the surgeon then inserts the Lowsley retractor via the urethra and points the tip toward the suprapubic region. A cut is made over the protuberant skin, and the retractor is delivered to the skin. The Lowsley retractor is then used to grasp the tip of the Foley catheter (18 or 20 Fr) and position it in the bladder.[1] The surgeon must remember to place the suprapubic tube above the region of the abdominal incision.

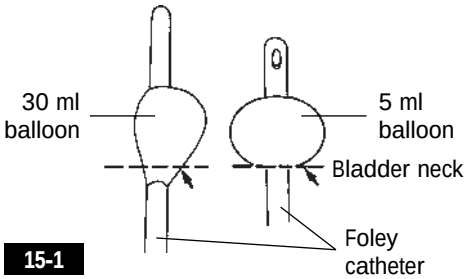

15-1

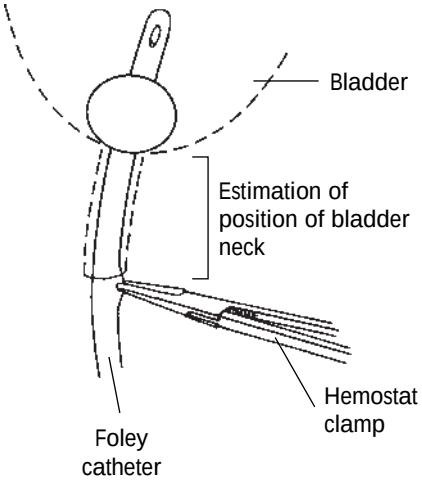

15-2

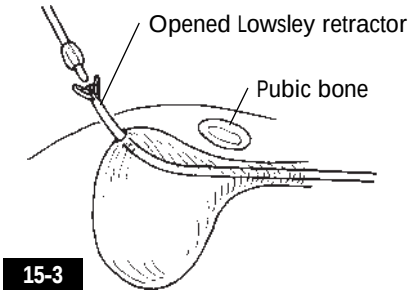

15-3

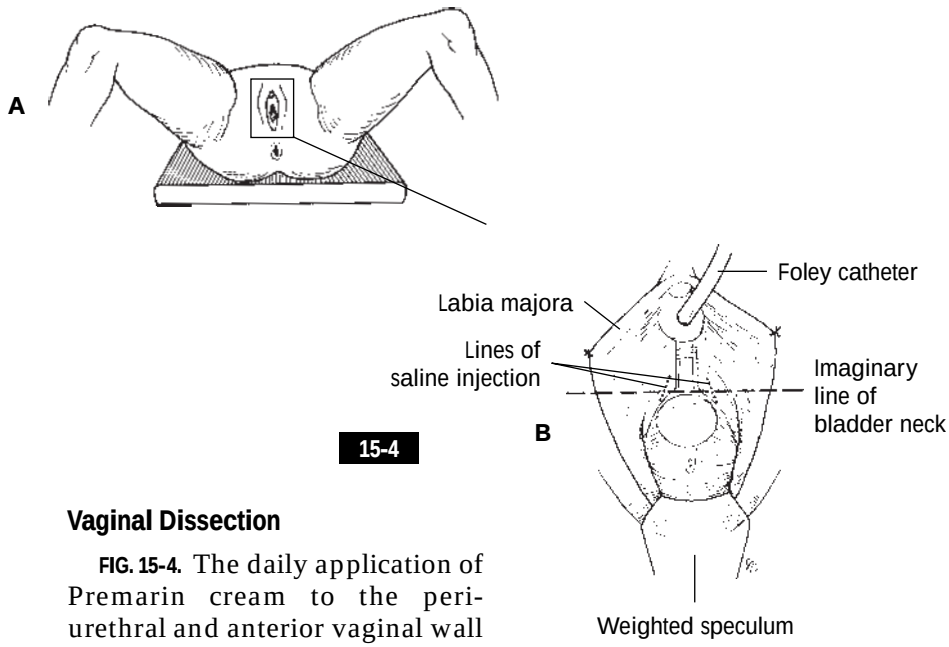

15-4

Vaginal Dissection

FIG. 15-4. The daily application of Premarin cream to the periurethral and anterior vaginal wall for 1 month before the operation will facilitate the epithelial dissection. After labial traction sutures are placed and a weighted speculum is inserted into the vagina, the surgeon can inject saline solution along the designated incisions to separate the vaginal epithelium from the bladder above.

FIG. 15-5. The two incisions traverse above and below an imaginary horizontal line defining the bladder neck. Traction from an Allis clamp placed above the incision will facilitate the creation of these incisions, especially if there is redundant vaginal epithelium.

FIG. 15-6. The surgeon aims the scissors toward the ipsilateral shoulder of the patient. By using the scissors in a spreading motion rather than cutting, the surgeon establishes a plane and then a space between the vaginal epithelium and the perivesical tissues. This dissection continues until it extends just past the medial aspect of the pubic ramus bone.

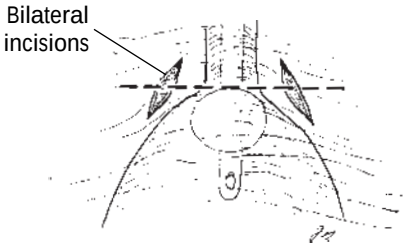

15-5

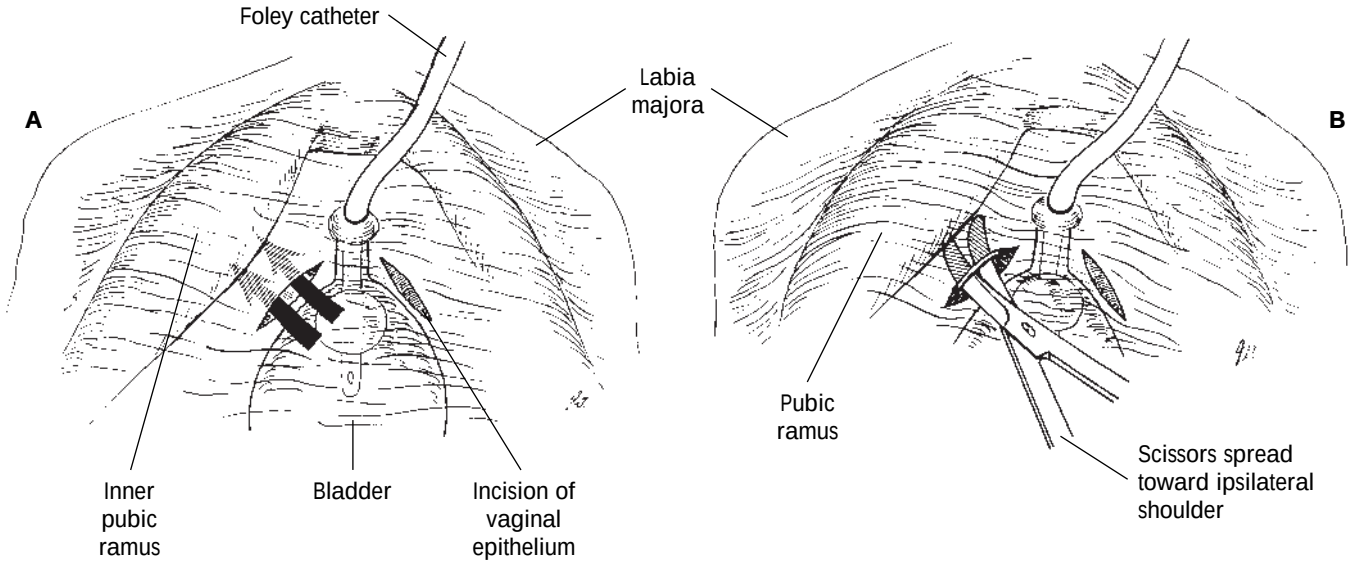

15-6

Dissection of Pelvic Fascial Complex

FIGS. 15-7 AND 15-8. With the index fingers, the surgeon can now palpate the dense pelvic fascial complex lateral to the bladder neck and proximal urethra. This dense fascia is composed of the urethral pelvic ligament and pubocervical fascia plus the endopelvic fascia, which all condense to the tendinous arch of pelvic fascia laterally.

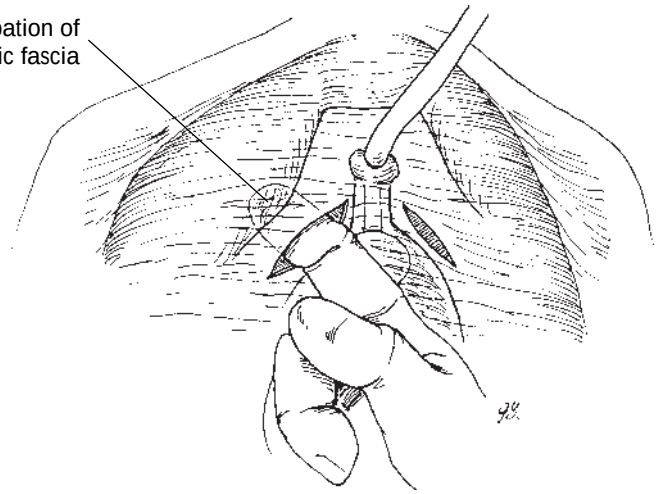

15-7

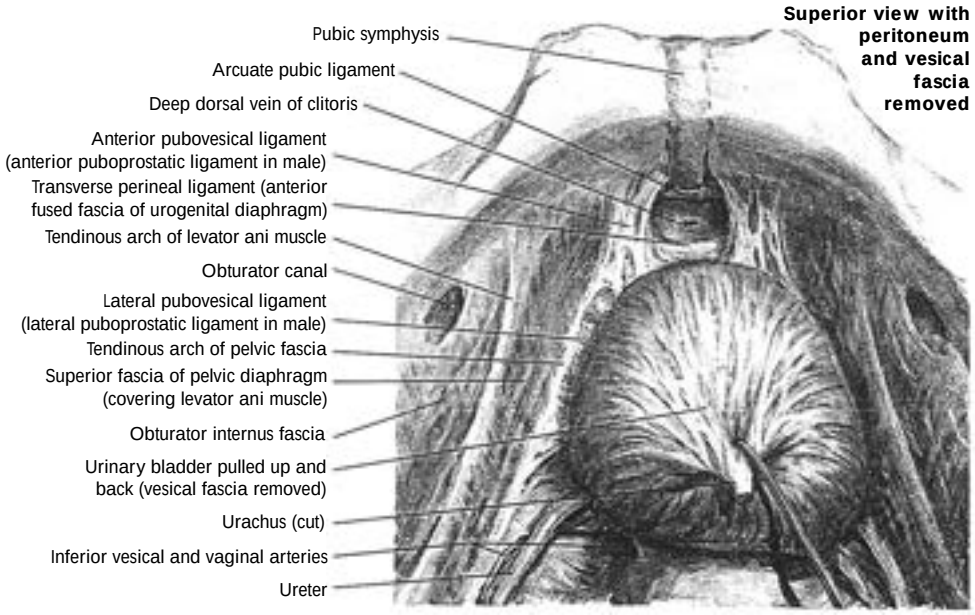

15-8

Mayo Scissors Perforation of Fascial Complex (Urethropelvic Ligament) (Spreading Maneuver Without Cutting)

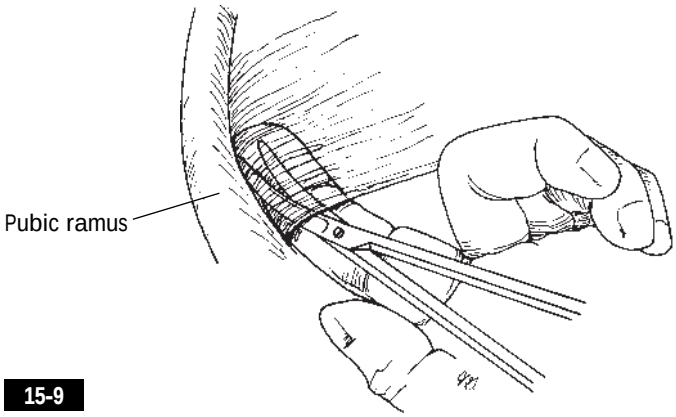

15-9

FIGS. 15-9 AND 15-10. The most important maneuver in this operation is the perforation of the dense fascia to enter the retropubic space.

By pressing against the medial aspect of the pubic ramus, the surgeon points the tips of the Mayo scissors up into this dense fascial complex.

With a spreading (not cutting) motion of the scissors, the surgeon perforates the fascial complex. The closer this dissection is to the urethra, the greater the chance of venous bleeding. At times, even careful lateral dissection will not preclude this problem.

FIGS. 15-11, 15-12, AND 15-13. The surgeon can enlarge this opening by placing the index finger into this perforation and moving the finger laterally along the bone and rotating the finger while pushing up. The surgeon should be able to palpate the midline prominence of the pubic symphysis with the index finger.

This same maneuver of fascial perforation can be applied to the sling operation as well as to the placement for the American Medical System (AMS) 800 continence prosthesis.

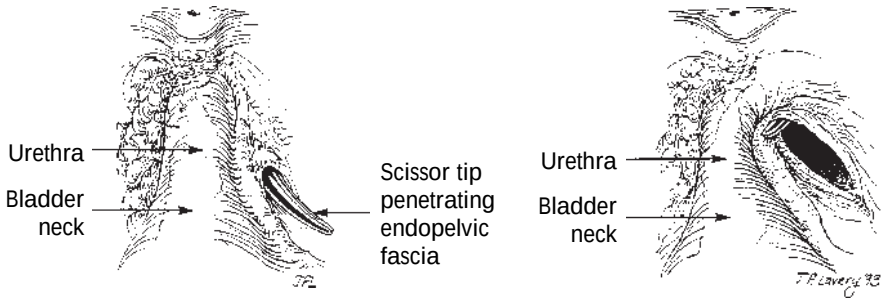

From Leach GE: *Urol Clin North Am* 2(1):1, 1994.

15-10

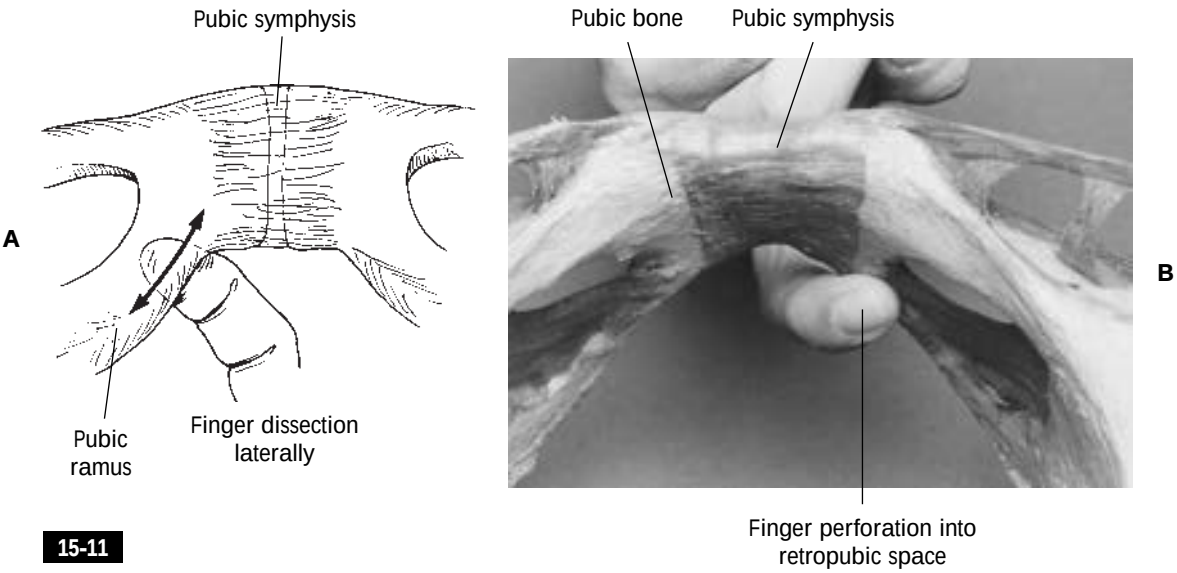

15-11

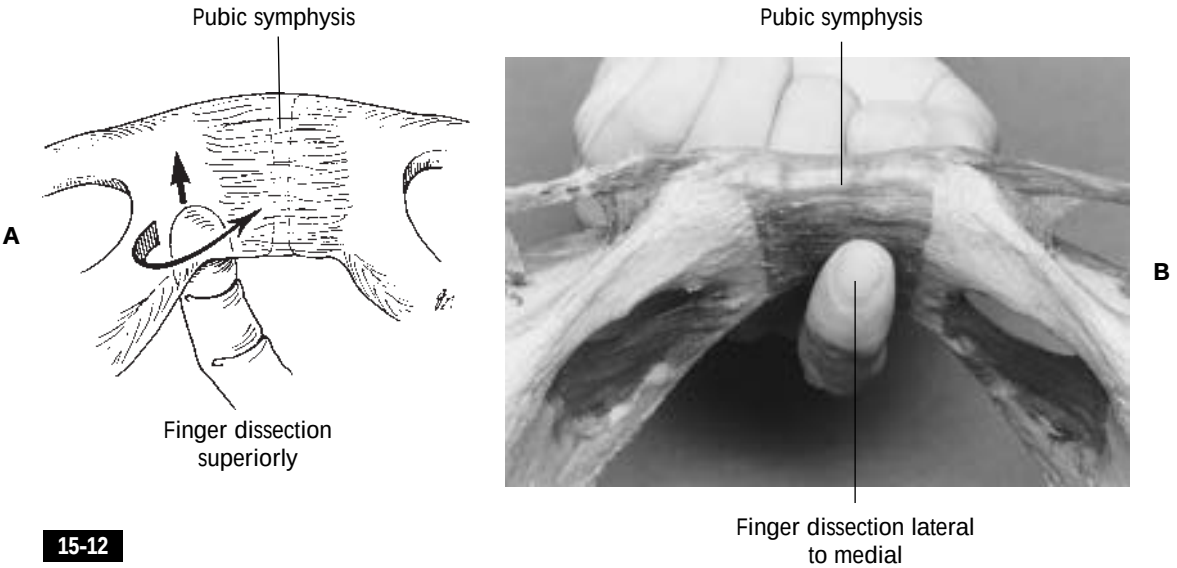

15-12

Retropubic View

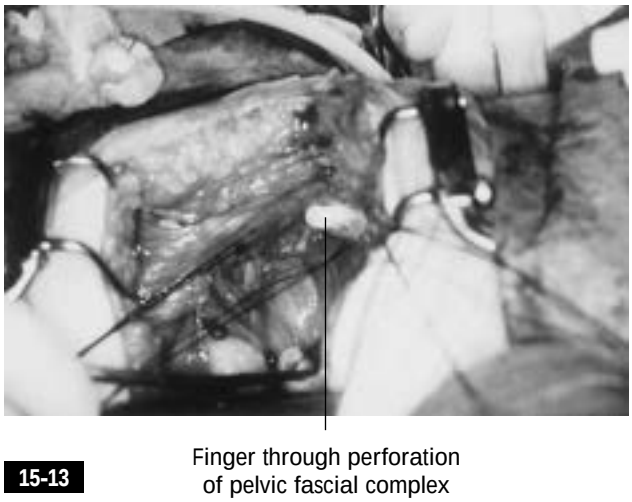

15-13

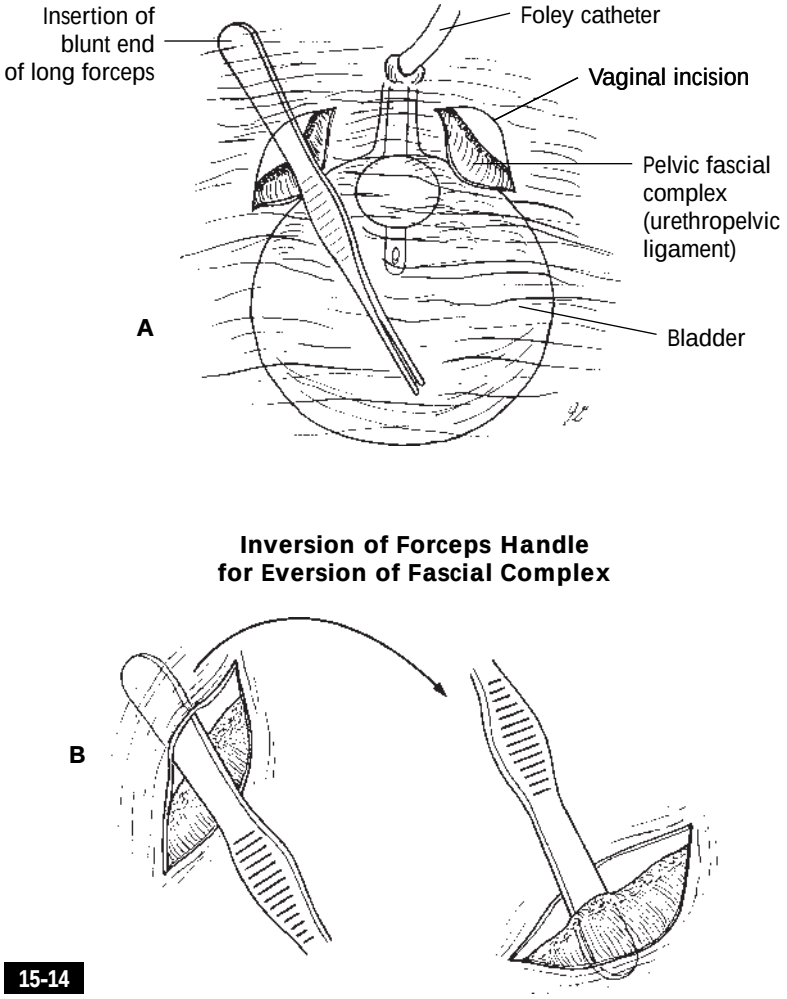

15-14

Placement of Helical Stitches

FIG. 15-14. By inserting the blunt end of long forceps up into the retropubic space **(A)** and then rotating it back down **(B),** the surgeon can secure a thick margin of fascial tissue lateral to the bladder neck.

Alternatively, Allis clamps can be used to grasp this fascial complex.

FIG. 15-15. The helical stitches are performed using 1-0 Prolene (D-6731) 36-inch monofilament suture on a half-circle taper MO-6 needle. We prefer to include both the pelvic fascial complex (the urethropelvic ligament and the pubocervical fascia) and vaginal subepithelium in the helical stitches.[1,2]

The surgeon should check on the position of the bladder neck by palpating the lateral aspect of the Foley catheter balloon before placing these stitches. If the stitches are placed too distally, the patient may have difficulty voiding during the immediate postoperative period. If the stitches are placed too proximally, the repair may not be as effective.

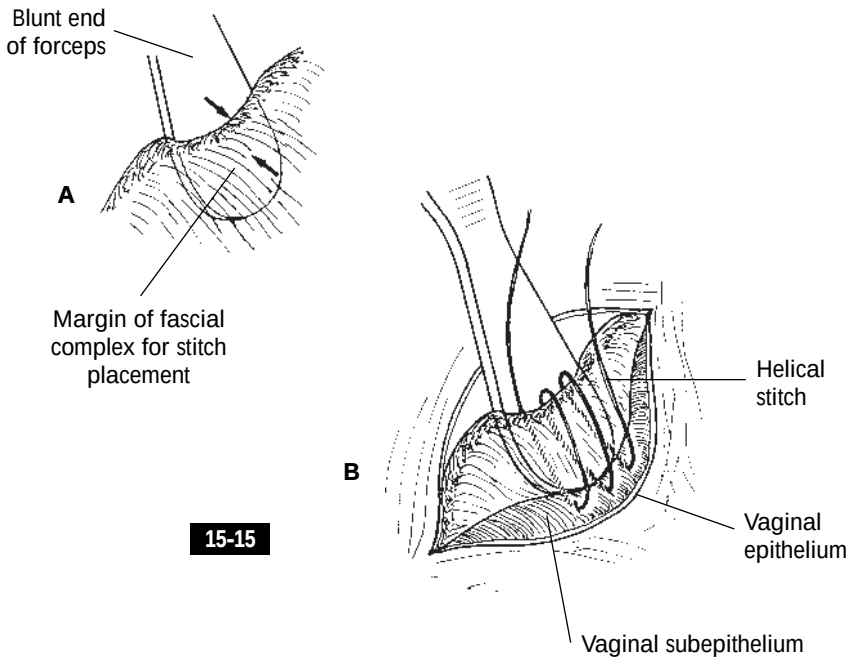

15-15

Rectus Fascia Suture Placement

FIG. 15-16. We prefer to use a 15-degree Stamey needle because it provides the greatest mobility and control.

FIG. 15-17. A small 5 cm suprapubic incision is made away from the site of the suprapubic tube and carried down to the rectus fascia. The surgeon inserts the Stamey needle as close to the midline as possible down alongside the pubic bone **(A)** and uses the left finger to guide this needle lateral to the urethra and bladder neck **(B).**

Placement of these stitches too laterally on the rectus fascia can entrap the medial branches of the ileoinguinal nerve with subsequent postoperative complication.[2]

FIG. 15-18. The free end of the helical stitches is threaded through the Stamey needle hole on each pass and brought up to the anterior rectus fascia. The surgeon uses four needle passes to bring the paired ends of the sutures to the anterior abdomen.

The paired sutures are sewn through two Teflon felt pledgets to prevent the Prolene stitches from tearing into the rectus fascia.

An alternative stitch fixation can be made on the pubic bone.[2]

Cystoscopy is performed to check for intravesical injury.

The vaginal incisions are closed before fixation of the helical stitches.

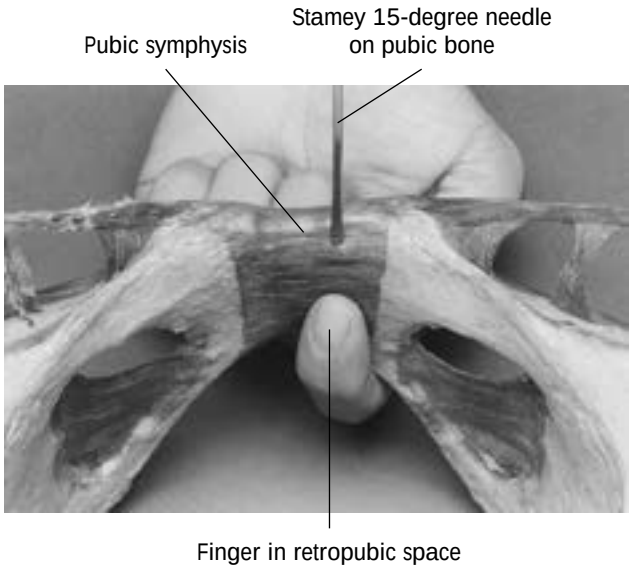

A

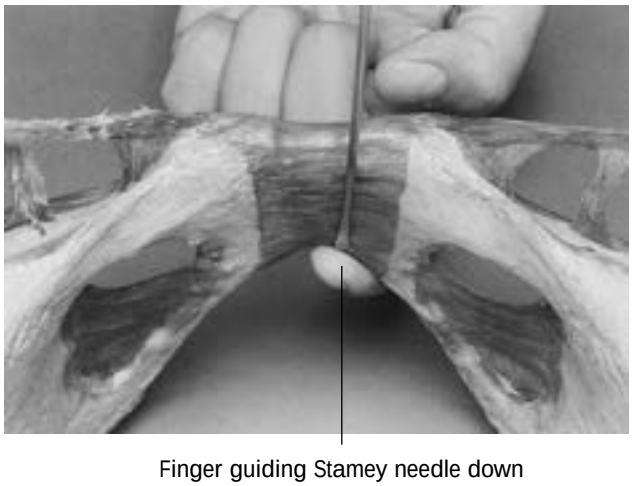

B

15-17

Stamey Needle with 15-degree Bend

15-16

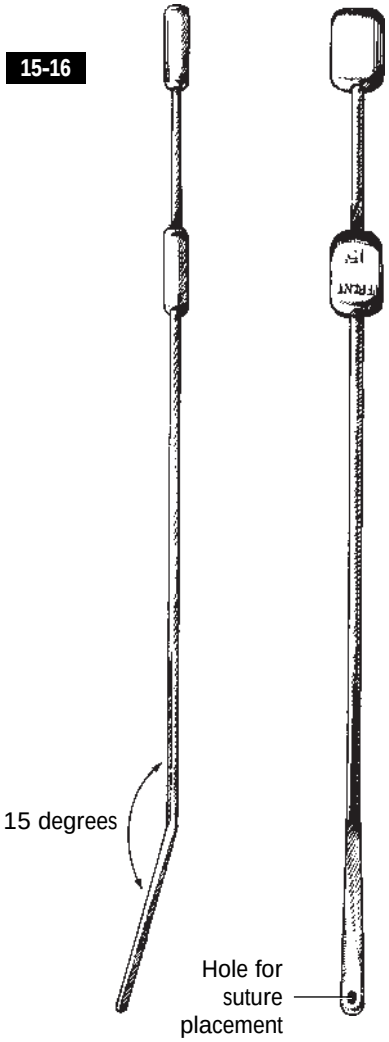

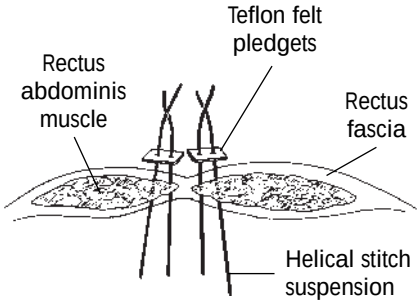

15-18

Optimal Lift of Suspension Stitches

FIG. 15-19. From a retropubic view, the surgeon can see that the helical stitches are in line with the bladder neck and proximal urethra.

FIG. 15-20. The goal of stress incontinence corrective surgery is to lift the bladder neck back into the abdominal space and prevent *hypermobility* at the bladder neck. In practice, it is easier to overcorrect than undercorrect.

FIG. 15-21. The surgeon must estimate the optimal lift of the stitches by placing one throw of a knot over the rectus fascia (using Teflon felt pledgets) for each pair of Prolene sutures and then clamping hemostats just above the knots to maintain this configuration.

A straight probe (or cystoscope sheath) is placed via the urethra into the bladder. If the *entire* probe (not just the tip) cannot be pushed downward to reproduce bladder neck hypermobility **(A),** then this degree of lift is optimal, and the surgeon should replace the hemostat below the knot and throw four additional square knots. The hemostat prevents knot slippage.

If the probe tilts forward anteriorly toward the pubis, then suspension is overcorrected **(B).**

FIG. 15-22. The suspension should be such that the bladder neck repair is parallel to the operating room floor **(A).**

Overcorrection by lifting the sutures so that the bladder neck coapts is unnecessary and can lead to temporary postoperative urinary retention and pronounced symptoms of an unstable bladder **(B).**

Redundant vaginal epithelium may disguise the actual bladder neck repair beneath **(C).**

Retropubic View

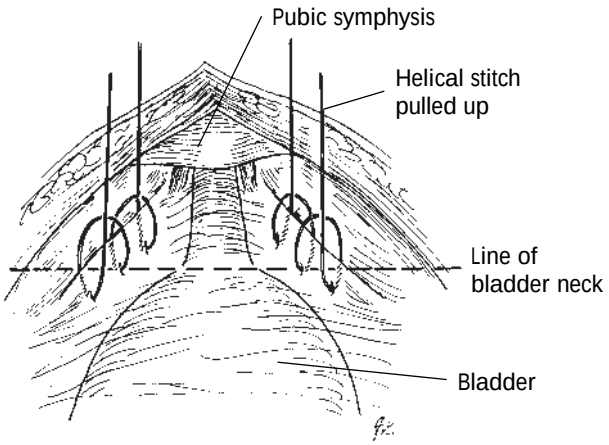

15-19

Lateral View

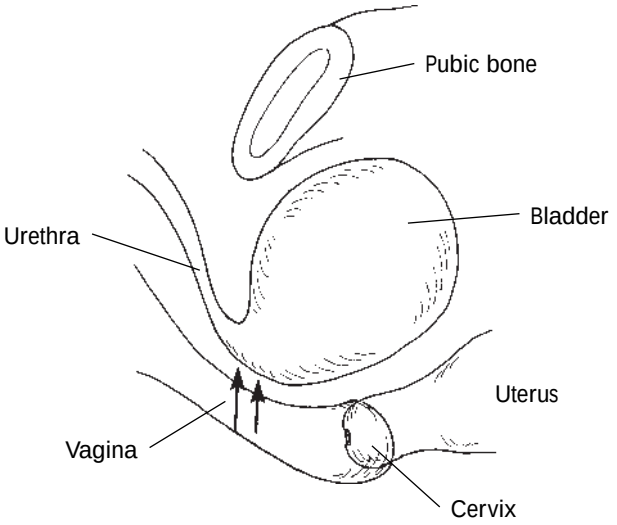

15-20

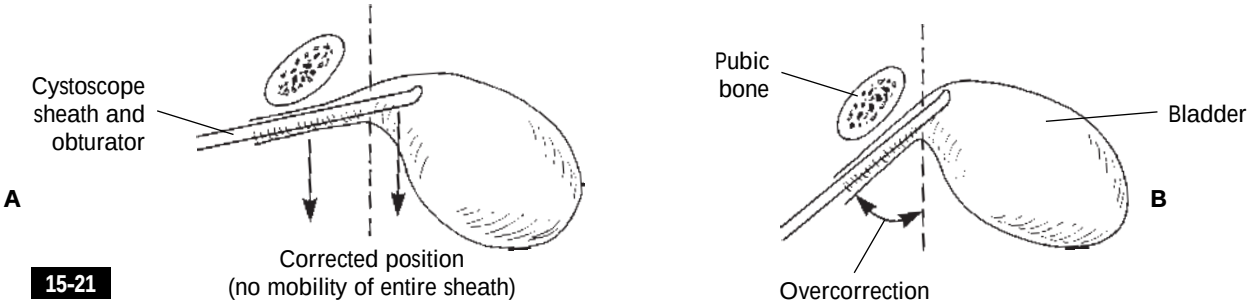

15-21

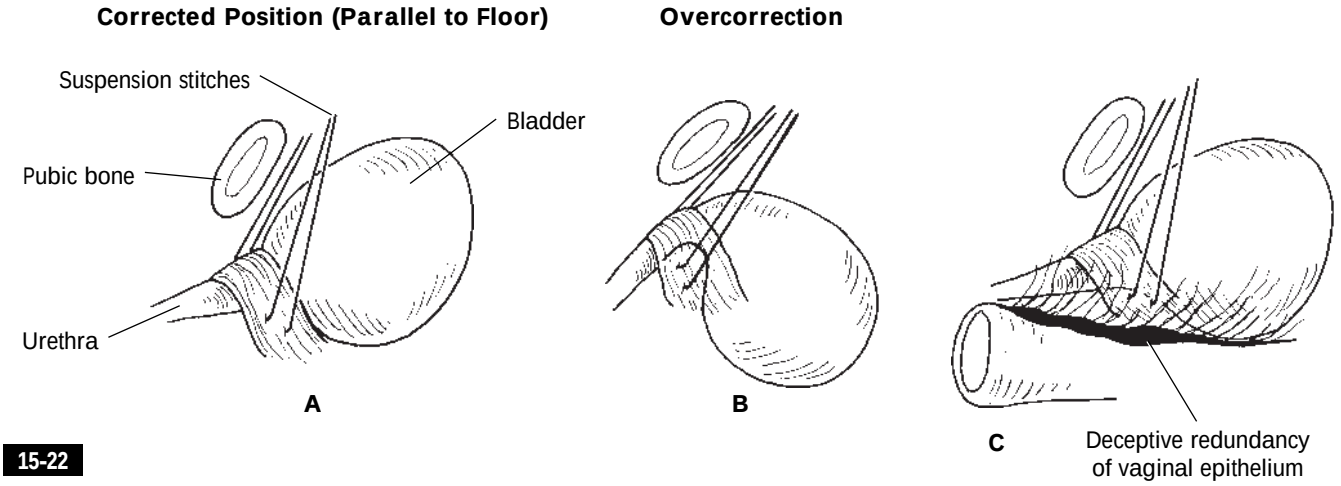

15-22

KEY POINTS

- Premarin cream is applied vaginally daily for 1 month preoperatively to facilitate vaginal dissection.
- The position of the bladder neck is estimated.
- A 5 ml Foley catheter is inflated to 10 ml within the bladder to define the bladder neck.
- Saline solution is injected at the incision sites to separate the vaginal epithelium from the bladder.
- Because there are venous channels medially within the fascial layers, the pelvic fascial complex is perforated as laterally as possible using the Mayo scissors and the retropubic space is thus entered.
- The blunt end of the forceps is used to expose the fascial complex.
- Helical suspension stitches are placed at the level of the bladder neck.
- After two pairs of sutures have been placed in a suprapubic position using 15-degree Stamey needles, cystoscopy is performed to check for bladder injury.
- The vaginal epithelium is closed before the suspension sutures are secured.
- The suspension should place the bladder neck back into the abdominal cavity to correct hypermobility.
- Excessive correction should be avoided. A probe test is used to check for hypermobility of the bladder neck and urethra.

POTENTIAL PROBLEMS

- *Excessive bleeding from perforation of pelvic fascial complex:* Apply tamponade and sponges → place helical stitches, which will stop the bleeding when lifted
- *Bladder is punctured during finger or scissors dissection:* Perform cystoscopy → perform vesical repair for a large laceration; otherwise place a Foley catheter → postpone the operation
- *Overcorrection:* Take down and loosen the suspension

STRESS INCONTINENCE TYPE III WITH INTRINSIC SPHINCTER DYSFUNCTION

Stress incontinence associated with an intrinsic sphincteric dysfunction is defined by an open frozen bladder neck on cystoscopy and video fluoroscopy and an abnormally low leak-point pressure by urodynamics studies.[2] The surgeon's objective is not only to correct the stress incontinence but also to add a *compressive component* around the bladder neck region.

The sling operation and the artificial sphincteric device (AMS 800) are the two most successful treatment options available. The effectiveness of collagen injection is unclear at present.

Sling Operation

The injection of saline solution into the vaginal epithelium is an easy way to separate the tissue planes between the vaginal epithelium and the bladder.

A 5 ml Foley balloon catheter inserted into the bladder and inflated to 10 ml defines the bladder neck for the surgeon.

A midline vertical incision or inverted-U incision over the proximal urethra and the bladder neck is made.

The surgeon inserts Mayo scissors through the incision, aims the scissors tip at the patient's ipsilateral shoulder, and uses a spreading motion to perforate the pelvic fascial complex.

As in the Raz procedure, the pelvic fascial complex (urethropelvic ligament) is identified and perforated, and the retropubic space is entered (see pp. 141-143). The fascial layers should be perforated at the region of the bladder neck and the proximal urethra.

After the pelvic fascial complex (urethropelvic ligament) is perforated with the Mayo scissors, the surgeon inserts the index finger through the perforation to create a defect slightly *wider* than the width of the index finger (⩾2 cm).

FIG. 15-23. Once this perforation is established, the surgeon can use a strip of rectus fascia, fascia lata,[3,4] or inorganic material such as Gore-Tex for the sling repair.[5]

We prefer organic fascial slings because of the reduced incidence of postoperative infection as compared to that with inorganic grafts. For the organic graft, there are two ways to construct the fascial sling. The usual method is to extract a strip of rectus fascia measuring 2 × 15 cm or even 2 × 17 cm. We prefer to harvest the longest strip possible because these fascial strips are often shorter than ideal. If the strip is too short, the surgeon tends to pull the fascia tighter and thus compress the proximal urethra and bladder neck more than desired.

A landmark is made with a marking pen or indigo carmine to define the midpoint of the fascial strip; the landmark should be positioned over the bladder neck and urethra.

FIG. 15-24. The distal edge of the fascial strip is anchored on each side to the tissue adjacent to the bladder neck to prevent slippage and "rolling up."[3]

Using tonsil clamps, the surgeon bluntly perforates the posterior rectus fascia and rectus abdominis muscle from above, as is done with the Stamey needle in the Raz procedure, down into the retropubic space to receive the fascial strip. The fascia is anchored to the rectus fascia or the periosteum of the pubis.

FIG. 15-25. An alternative method is to use a shorter fascial strip (2 × 10 cm) with 1-0 Prolene stitches (D-6731) secured on either end. Some surgeons have reported using a 2 × 5 cm strip; however, we prefer a longer strip (2 × 10 cm) to allow for the possibility of fascial slippage or displacement.

The stitches are brought to the abdominal surface with the Stamey needle or a tonsil clamp as in the Raz procedure. We prefer to use the tonsil clamp because it creates

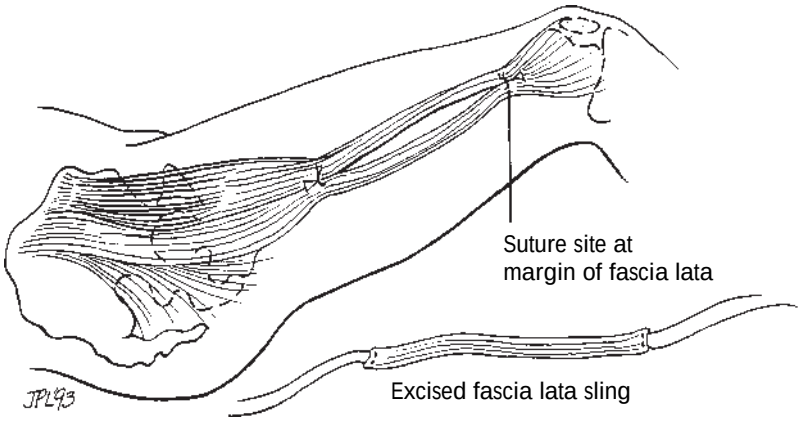

From Leach GE, Sirls L: *Urol Clin North Am* 2(1):61, 1994.

15-23

a larger defect for the fascial strip, allowing it to slide into an optimal position.

The advantage of using a short (5 to 10 cm) strip of inorganic material, such as Gore-Tex or Mersilene, is that there is no need for additional surgery to harvest a fascial strip.[5] The disadvantage of synthetic grafts is that they have a higher risk of infection. We prefer to use the organic fascial strip.

Just as with the short strip of rectus fascia, the inorganic strip must be anchored to the bladder neck/proximal urethral region. The Prolene stitches on either side are brought up to the abdominal wall.

If the fascial strip is too loosely placed around the urethra, then the surgical connection may not be effective for the long term. If it is too tight around the urethra, the patient may have a prolonged period of urinary retention with severe symptoms of an unstable bladder. Some surgeons prefer to coapt the anterior and posterior urethra in the sling procedure (with confirmation on cystoscopic examination).[6] Others prefer only to "create a slight indentation on the floor of the proximal urethra."[2] The surgeon's experience and judgment will guide the choice of an optimal position between the two extremes.

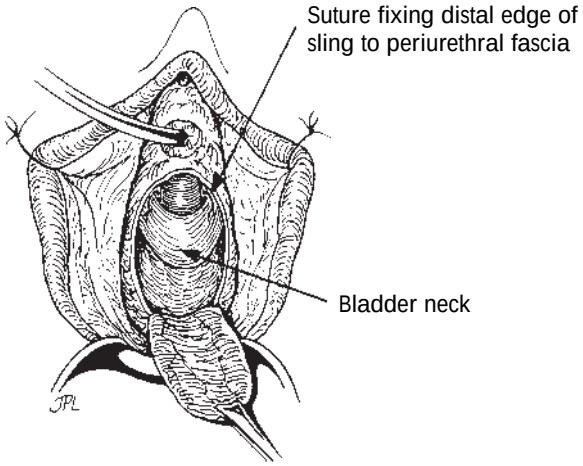

From Leach GE, Sirls L: *Urol Clin North Am* 2(1):61, 1994.

15-24

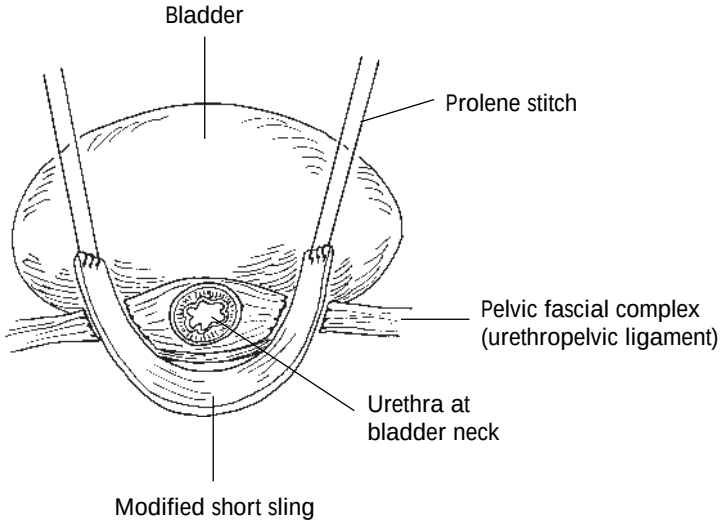

15-25

Although we have not coapted the urethral walls, we have brought the anterior and posterior parts of the urethra close to each other as the optimal position for fascial sling compression.

All patients are informed of the use of intermittent catheterization before the operation.

AMS 800 Sphincteric Device (Narrow-Backed Model)

In contrast to the placement of the AMS 800 device around the bulbous urethra in men, the placement of the sphincteric device around the bladder neck in women is more difficult; therefore this device is used less frequently in women.

The prosthesis is well designed and, if properly placed, can produce a satisfying outcome.

FIG. 15-26. One device that has been developed to facilitate the difficult dissection around the bladder neck is a "cutter clamp."[7] This instrument pinches and secures the tissue between the urethra and vagina so the dissection plane can be identified **(A** and **B).** Cystoscopy is performed while the instrument is in place to ensure that the urethra is clear **(C).** When the surgeon is certain that the clamp is properly positioned, the cutting blade within the clamp is advanced **(D).** One arm of the clamp is removed, and suture material is threaded through the eye in the cutting blade **(E).** As the blade is withdrawn **(F),** the suture serves to guide the placement of a right-angle clamp, which is used to dilate the opening enough for a 2 cm cuff **(G).**

FIG. 15-27. Some surgeons advocate the vaginal packing method during placement of the AMS device.

We have found a combined vaginal and retropubic dissection to be the safest method of avoiding any injury to the urinary tract, even though there are special instruments such as the cutter clamp to facilitate bladder neck dissection[7] and special maneuvers[8-10] such as vagina packing as described by Petrou and Barrett.[11]

Commonly these patients have undergone previous cystourethropexy procedures and thus have multiple scars and adhesions within the abdominal and vaginal cavities.

By first approaching from the vaginal side as in the Raz procedure, the surgeon perforates the pelvic fascial complex on the vaginal side and enters the retropubic space through the endopelvic fascia. If severe adhesions and scars preclude this maneuver, the surgeon should wait until the abdominal side has been exposed before puncturing the fascial layers.

Via a midline incision, as in the Burch procedure, the surgeon dissects down into the retropubic space. Scars and adhesions should be cautiously taken down especially around the proximal urethra and bladder neck (see p. 155).

By inserting the finger from the vaginal side up into the retropubic abdominal side, the surgeon passes a Penrose drain (¾ inch) around the proximal urethra and bladder neck (see Fig. 15-13).

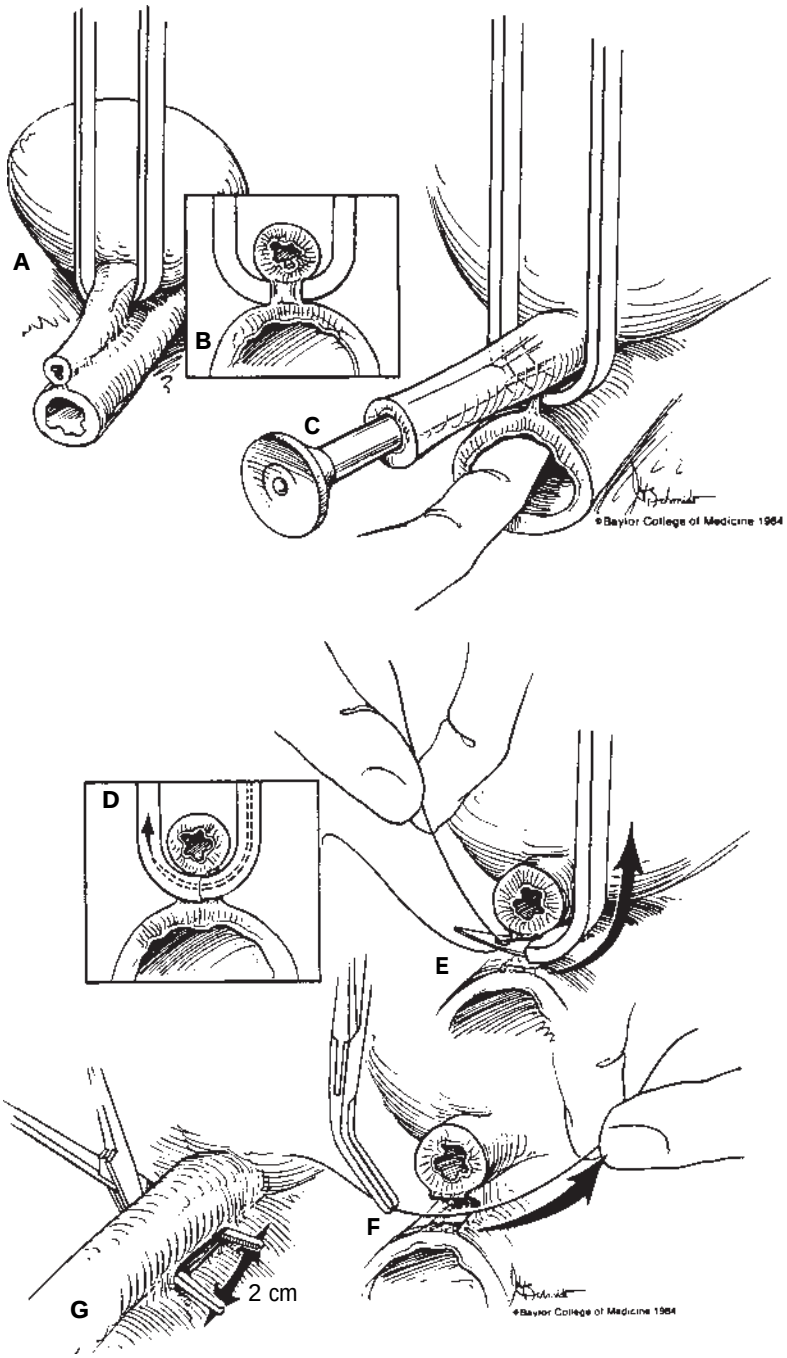

From Scott FB: *Urol Clin North Am* 12:305, 1985.

15-26

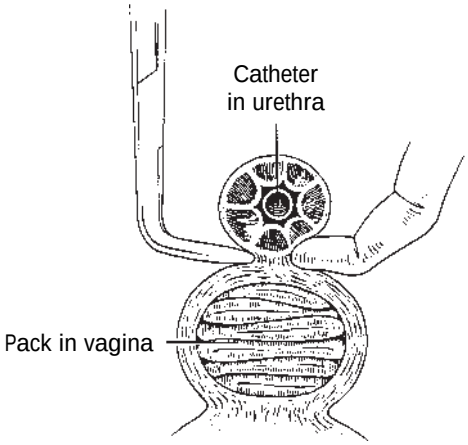

From Petrou SP, Barrett DM: The use of artificial genitourinary sphincter (AGUS) in female urinary incontinence. In Webster G et al, editors: *Reconstructive urology,* London, 1993, Blackwell.

15-27

FIG. 15-28. The measuring tape is passed from the vaginal side and around the urethra for the cuff measurement.

FIG. 15-29. The cuff is passed from the vaginal side into the retropubic space and snapped in place so that the tubing for the reservoir lies on the abdominal side rather than the vaginal side.

A reservoir can also be placed in the retropubic space and the pump placed in the labia majora.

A drain is left in for 24 hours, and generous antibiotic solution irrigation should be performed before closure.

The surgeon can examine the urethra and bladder neck via a cystoscope after the procedure.

The cuff remains deactivated for 1 month.

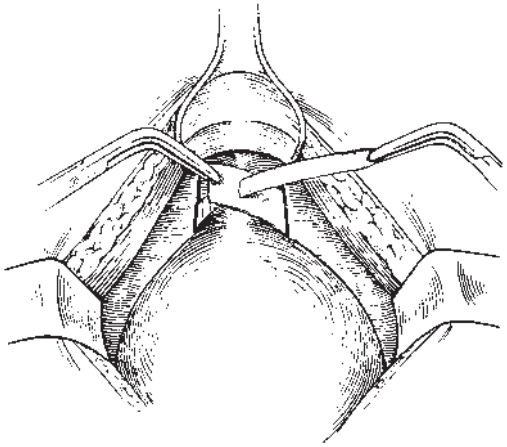

From Petrou SP, Barrett DM: The use of artificial genitourinary sphincter (AGUS) in female urinary incontinence. In Webster G et al, editors: *Reconstructive urology,* London, 1993, Blackwell.

15-28

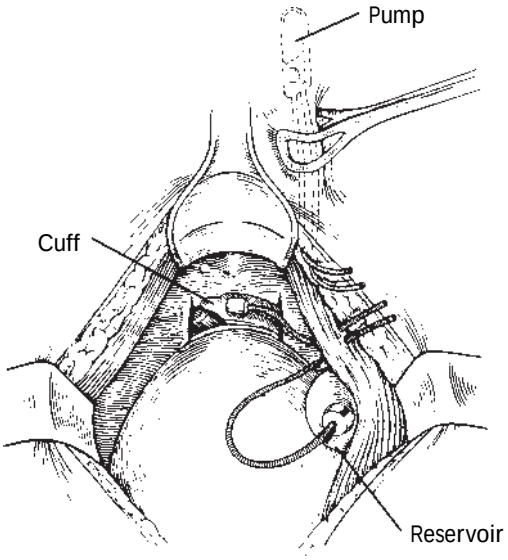

From Petrou SP, Barrett DM: The use of artificial genitourinary sphincter (AGUS) in female urinary incontinence. In Webster G et al, editors: *Reconstructive urology,* London, 1993, Blackwell.

15-29

KEY POINTS

SLING OPERATION

- A midline vertical incision or an inverted-U incision is made over the proximal urethra and bladder neck.
- As is performed in the Raz procedure, the pelvic fascial complex (urethropelvic ligament) is perforated.
- The type (organic or inorganic) and size (short [2 × 5 cm] or long [2 × 15 cm]) of sling are chosen.
- The sling is anchored at bladder neck and proximal urethra with sutures to prevent slippage and rolling up.
- The sling should coapt the bladder neck opening.

AMS 800 SPHINCTERIC DEVICE

- First vaginal dissection (as in the Raz procedure) and then abdominal dissection (as in the Burch procedure) are performed.
- All adhesions and scarring around the bladder neck are freed.
- Cuff measurement is obtained and the cuff is put in place, with the tubing on the abdominal side.
- The cuff remains deactivated for 1 month.

POTENTIAL PROBLEMS

SLING OPERATION

- *Difficulty dissecting from vaginal side:* Consider abdominal incision as a combined approach
- *Fascial strip not optimal:* Consider using fascia lata → consider using an inorganic strip

AMS 800 SPHINCTERIC DEVICE

- *Perforation into urinary tract:* Consider using fascial sling operation after urothelial repair → place suprapubic tube for urinary diversion

REFERENCES

1. Raz S: *Atlas of transvaginal surgery,* Philadelphia, 1992, WB Saunders.
2. Leach GE, Sirls L: Pubovaginal sling procedures, *Urol Clin North Am* 2(1):61, 1994.
3. Leach GE: Vaginal anatomy and preoperative preparation for vaginal surgery, *Urol Clin North Am* 2(1):1, 1994.
4. Blaivas JG: Commentary—pubovaginal sling procedure. In Whitehead ED, editor: *Current operative urology,* Philadelphia, 1990, JB Lippincott, pp 93-99.
5. Kerr LA, Staskin DR: The use of artificial material for sling surgery in the treatment of female stress urinary incontinence. In Raz S, editor: *Female urology,* ed 2, Philadelphia, WB Saunders (in press).
6. McGuire EJ et al: Experience with pubovaginal slings for urinary incontinence at the University of Michigan, *J Urol* 138:525, 1987.
7. Scott FB: The use of the artificial sphincter in the treatment of urinary incontinence in the female patient, *Urol Clin North Am* 12:305, 1985.
8. Leo ME, Barrett DM: Success of the narrow-backed design of the AMS 800 artificial urinary sphincter: analysis of 144 patients, *J Urol* 150:1412, 1993.
9. Barrett DM, Goldwasser B: The artificial urinary sphincter: current management philosophy, *AUA Update Series,* lesson 32, vol V, 1994.
10. Hadley HR: Transvaginal needle suspension of a fascial sling, *Prob Urol* 4(1):74, 1990.
11. Petrou SP, Barrett DM: The use of artificial genitourinary sphincter (AGUS) in female urinary incontinence. In Webster G et al, editors: *Reconstructive urology,* London, 1993, Blackwell.

SUGGESTED READINGS

Appell RA: Techniques and results in the implantation of the artificial urinary sphincter in women with type III stress urinary incontinence by a vaginal approach. In *Neurourol Urodynam* 7:613, 1988.

Blaivas JG, Salinas J: Type III stress urinary incontinence: the importance of proper diagnosis and treatment, *Surg Forum* 35:472, 1984.

Gittes RF, Foreman R: Transcutaneous incorporation of nonabsorbable monofilament sutures, *Gynecol Obstet* 166:545, 1988.

Gittes RF, Loughlin KR: No-incision pubovaginal suspension for stress incontinence, *J Urol* 138:568, 1987.

Hadley HR, Zimmern PE, Raz S: Vaginal surgery for the urologist, *AUA Update Serv* IV(10):1, 1985.

Kelly MJ, Zimmern PE, Leach GE: Complications of bladder neck suspension procedures, *Urol Clin North Am* 18(2):339, 1991.

Klutke CG: Correcting stress incontinence with the Raz technique, *Contemp Urol* 43, 1991.

Marshall V, Marchetti A, Krantz K: The correction of stress incontinence by simple vesicourethral suspension, *Surg Gynecol Obstet* 88:505, 1949.

Reynolds CL Jr, Miller HC Jr: Subpubic urethropexy: a new remedy for stress incontinence, *J Urol* 111:361, 1974.

Stamey TA: Endoscopic suspension of the vesical neck for surgically curable urinary incontinence in the female, *1981 Monogr Urol* 2(3):65, 1981.

Modified Burch Procedure (Tanagho)

16

The clear advantage of the modified Burch procedure is that while correcting the stress incontinence, the surgeon is simultaneously correcting a medium-sized cystocele. In addition, it is unusual to overcorrect the defect using the modified approach.[1] The time required for this procedure and the number of days of hospitalization are similar to those for the Raz procedure.

EXPOSURE

FIG. 16-1. A straight midline incision from the pubis toward the umbilicus provides the best exposure of the pubourethral ligaments, endopelvic fascia adjacent to the proximal urethra, and bladder neck.

FIG. 16-2. After a Balfour retractor is placed and the retropubic space is exposed, the periurethral fat around the pubourethral ligaments and endopelvic fascia should be removed. Defatting this area permits proper visualization for stitch placement and allows this area to fibrose in the correct configuration postoperatively.[1,2]

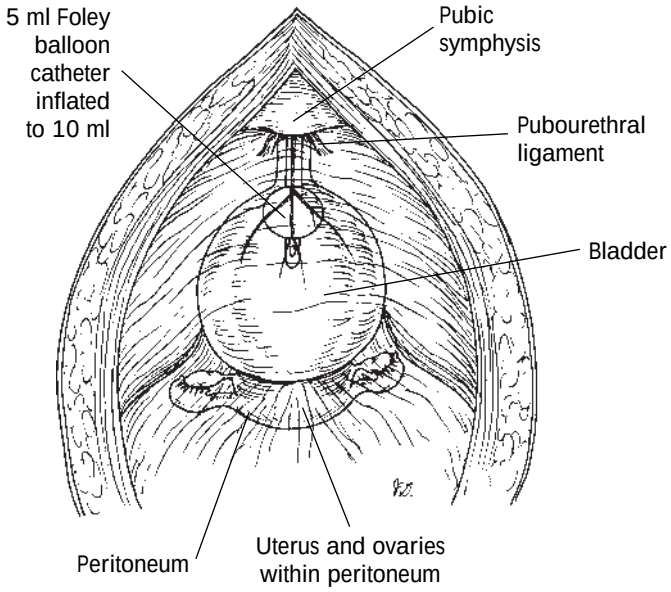

16-1

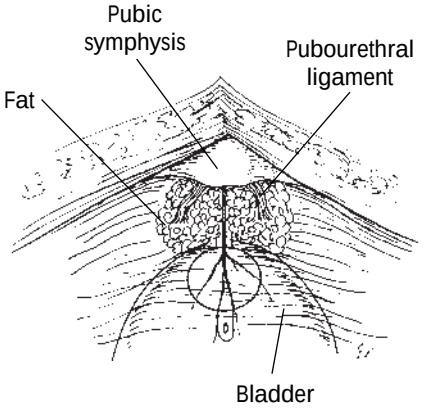

16-2

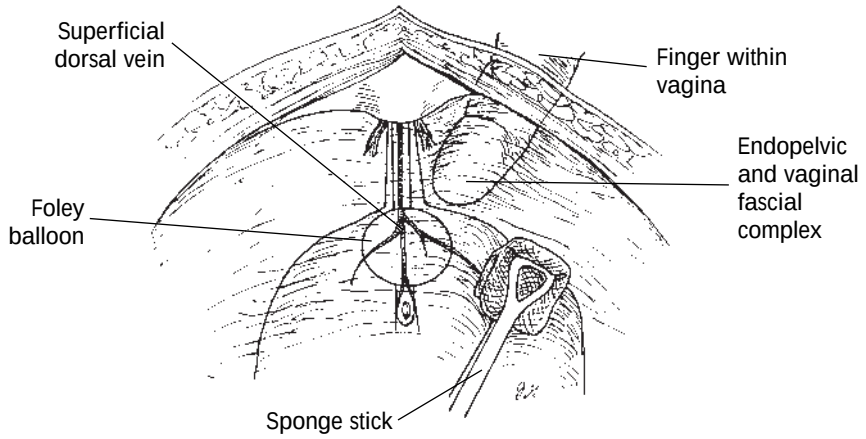

16-3

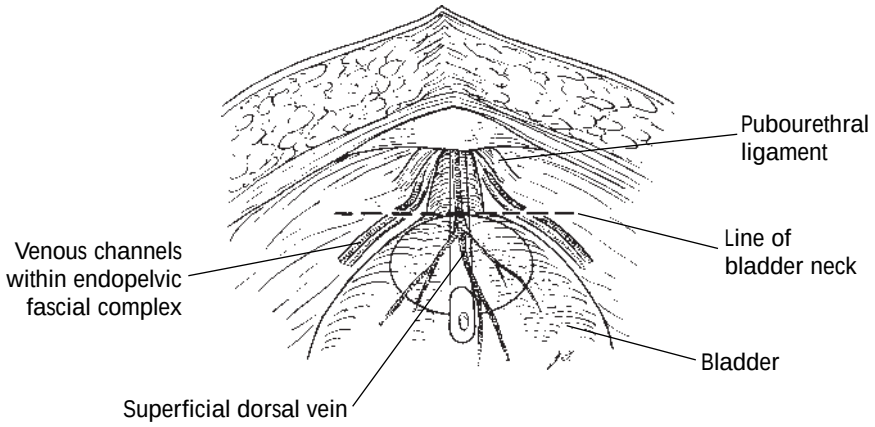

16-4

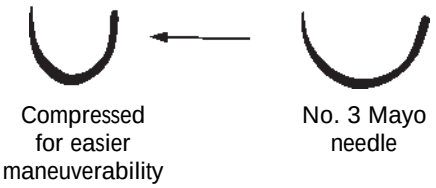

16-5

BLADDER NECK STITCH PLACEMENT

FIG. 16-3. A 5 ml Foley balloon catheter (instead of a 30 ml balloon catheter) is inflated to 10 ml. An assistant maintains gentle traction so that the catheter stays at the bladder neck and does not migrate cephalad in the bladder.

With the left index finger in the vagina, the surgeon can lift up and palpate the urethra medially and the Foley balloon superiorly, thus locating the bladder neck.

The assistant must apply proper traction with the sponge stick, depressing the bladder medially and cephalad, to obtain maximum exposure of the endopelvic and vaginal fascial complex for stitch placement.

FIG. 16-4. The venous channels adjacent to the urethra and the bladder neck are potential bleeding sites. Therefore the three stitches should be placed *lateral* to this area in the endopelvic and vaginal fascial complex. Each stitch is tied and left on hemostats to arrest any venous bleeding.

FIG. 16-5. We prefer to use a No. 3 Mayo needle that has been bent into a U shape and threaded with 1-0 Vicryl suture for placing these stitches. This modified needle offers better maneuverability in a small pelvic space and allows deep but not wide bites to be taken into the pelvic fascia.

FIGS. 16-6 AND 16-7. When driving the U-shaped Mayo needle into the pelvic fascia, the surgeon can determine the depth of each bite by the feel with the left index finger. The bites exclude the outer vaginal epithelial layer.

FIG. 16-8. The stitches are placed 1 to 1.5 cm lateral to the bladder neck. The first stitch is aimed at the imaginary horizontal line at the bladder neck.

The second stitch is placed 0.5 cm distal to the first stitch. The surgeon must use judgment with regard to how far distally to place the second stitch. If it is *too distal*, the patient may have an obstructive problem postoperatively.

The third stitch is placed 1.5 cm proximal to the second. This stitch, more than the other two, is responsible for cystocele correction.

FIG. 16-9. All three stitches are tied and clamped with hemostats.

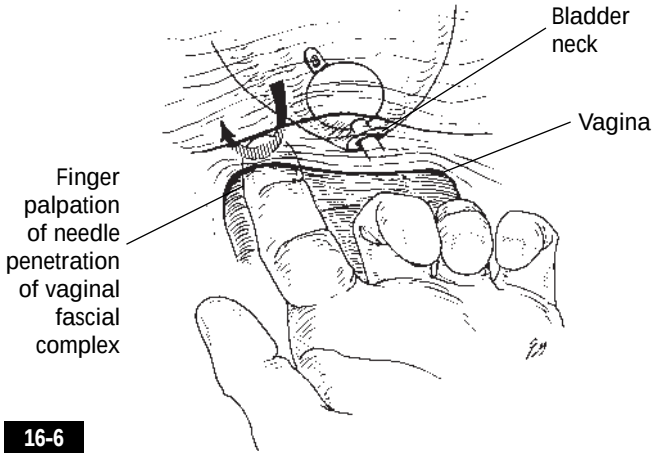

16-6

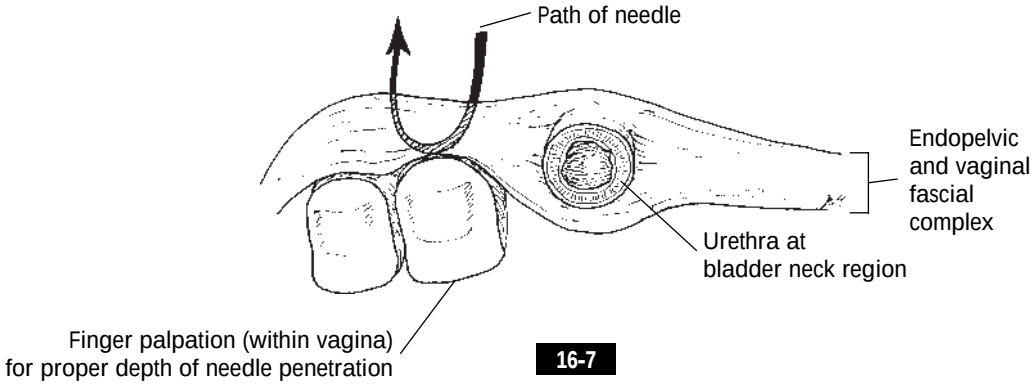

16-7

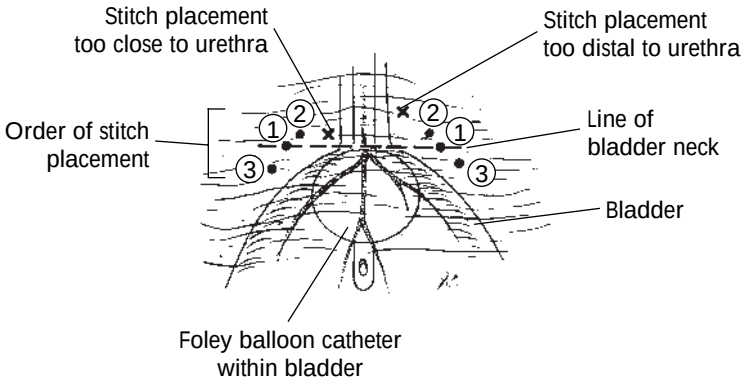

16-8

Completed Three Pairs of Stitches on Each Side

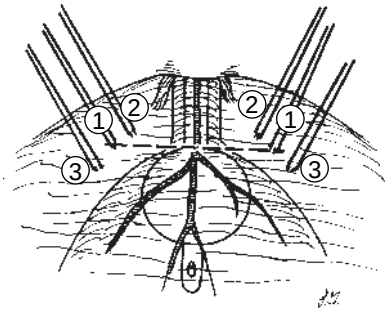

16-9

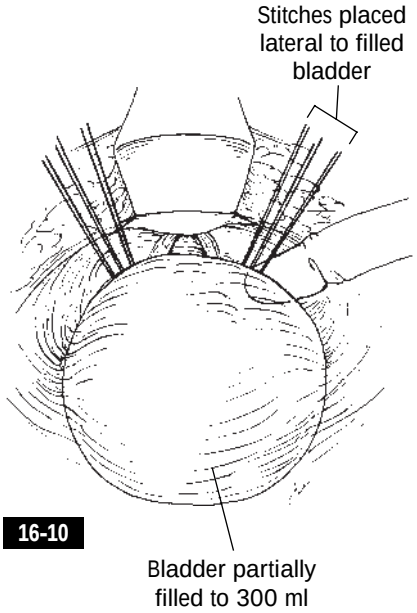

16-10

Modified Burch Procedure (Top View)

A

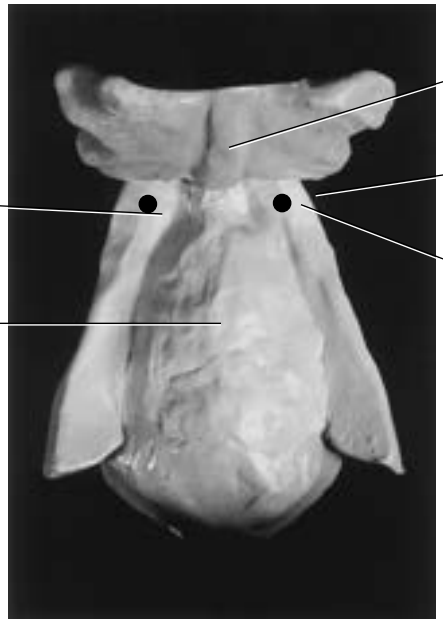

Raz Procedure (View from Vagina)

B

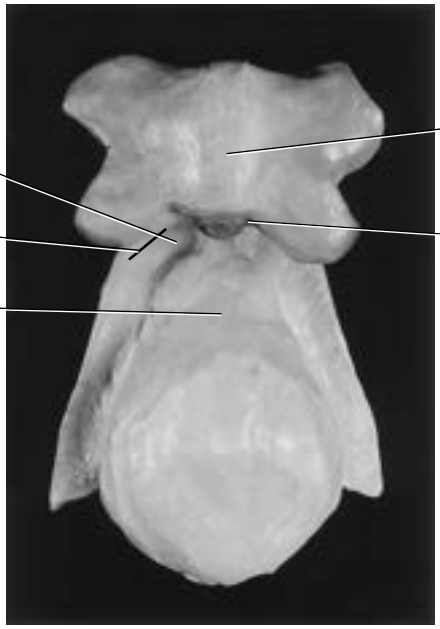

Lateral View

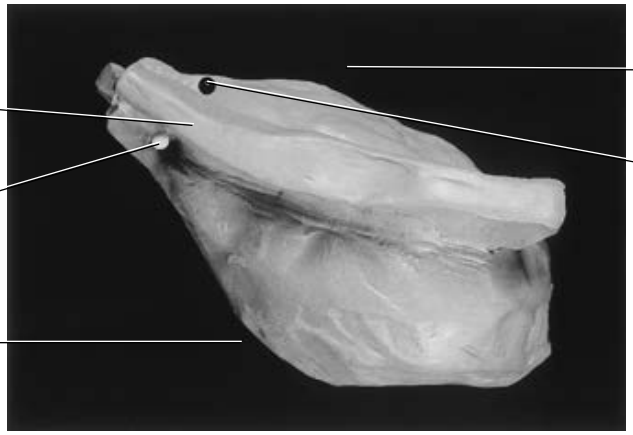

C

16-11

FIG. 16-10. After the bladder is filled with 300 ml of saline solution, the surgeon palpates the stitches to ensure that they are lateral to the bladder neck. If unsure, the surgeon should perform cystoscopy to rule out vesical injury.

FIG. 16-11. When the modified Burch procedure (from the retropubic space) and the Raz procedure (from the vaginal space) are compared, stitch position is similar. Because the stitches are anchored to the more lateral Cooper's ligaments in the Burch procedure, medium-sized cystoceles are corrected in the repair.

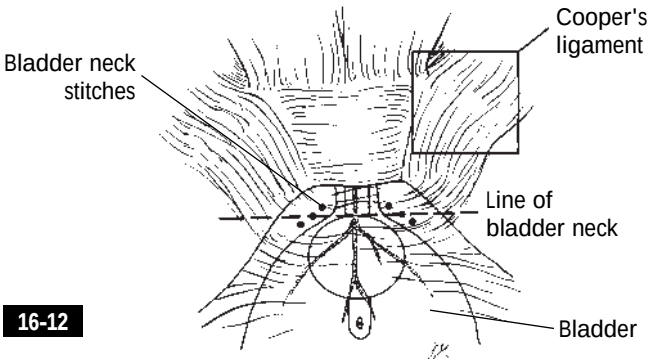

16-12

COOPER'S LIGAMENT SUTURE PLACEMENT

FIGS. 16-12, 16-13, AND 16-14. The Cooper's ligament is a dense ligament lateral to the pubic insertion of the rectus abdominis muscle. The surgeon can clear this area of fatty tissues and define a fascial segment about 4 to 5 cm wide.

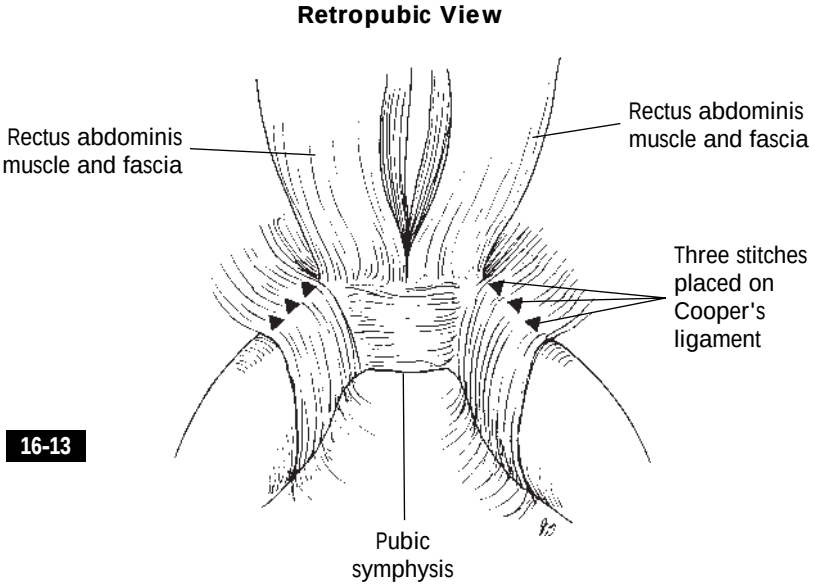

16-13

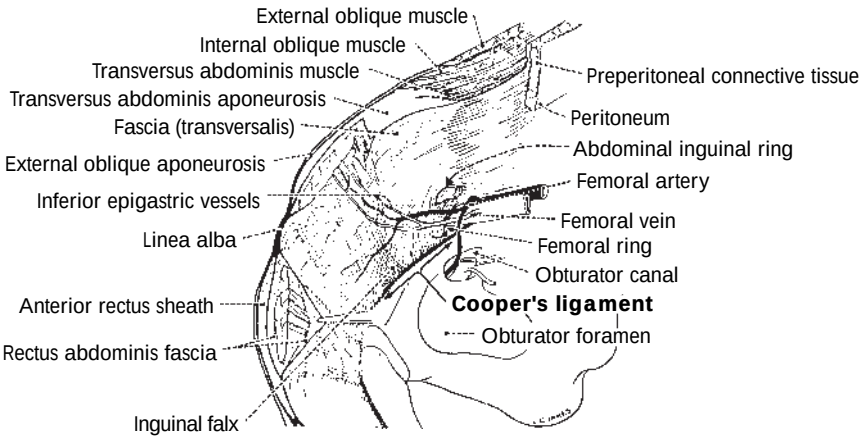

McVay CB: *Davis-Christopher textbook of surgery,* ed 9, Philadelphia, 1968, WB Saunders.

16-14

FIG. 16-15. The surgeon must be aware that the femoral vein is located on the other side of the fascia. The femoral vein is closest at the lateral, not medial, portion of the ligament.[1,3]

Small accessory venous structures lying on the Cooper's ligament can be pushed laterally for better exposure.

Three stitches are placed in this area about 1 cm apart, tied, and left on hemostats uncut. These three stitches should be aligned with the corresponding ipsilateral bladder neck stitches.

APPROXIMATION OF CORRESPONDING PAIRS OF STITCHES

FIG. 16-16. The three stitches at the bladder neck can be paired with and tied to the corresponding three on the ipsilateral Cooper's ligament.

The assistant places the fingers in the vagina and lifts the vaginal wall while the surgeon ties the three pairs of stitches on each side. When tying from the vaginal fascia to the Cooper's ligament, the surgeon ties the paired stitches tightly but *without* attempting to pull the two fascial layers together. With this modification, postoperative urinary retention is rare.[1]

We tie the paired stitches together leaving a gap of about 3 to 5 cm between the elevated vaginal fascia and the Cooper's ligament.

Scarring of the region takes place before the Vicryl stitches degenerate.

The three stitches on each side of the bladder neck region are pulled further laterally by tying them to the Cooper's ligament. This lateral pull rarely causes urethral compression, and it easily corrects medium-sized cystoceles.

FIG. 16-17. The modified Burch procedure described by Tanagho[1] uses one stitch on each side. Note the placement of the stitches without approximation of the endopelvic and vaginal fascial complex to the Cooper's ligament.

FIGS. 16-18 AND 16-19. With the original Burch procedure, the endopelvic and vaginal fascial complex is approximated to the Cooper's ligament.[4] However, it is not necessary to go to such extremes to achieve continence. In addition, it is nearly impossible to approximate the two fascial layers together, no matter how large the cystocele.

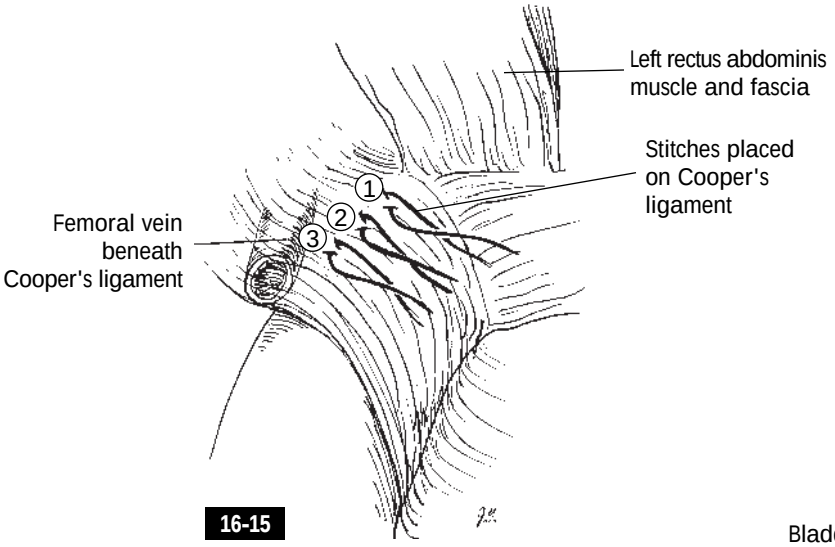

16-15

Three Pairs of Stitches Tied on Each Side with Gap Remaining

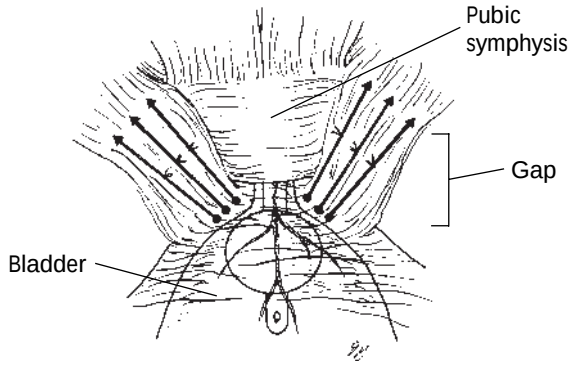

16-16

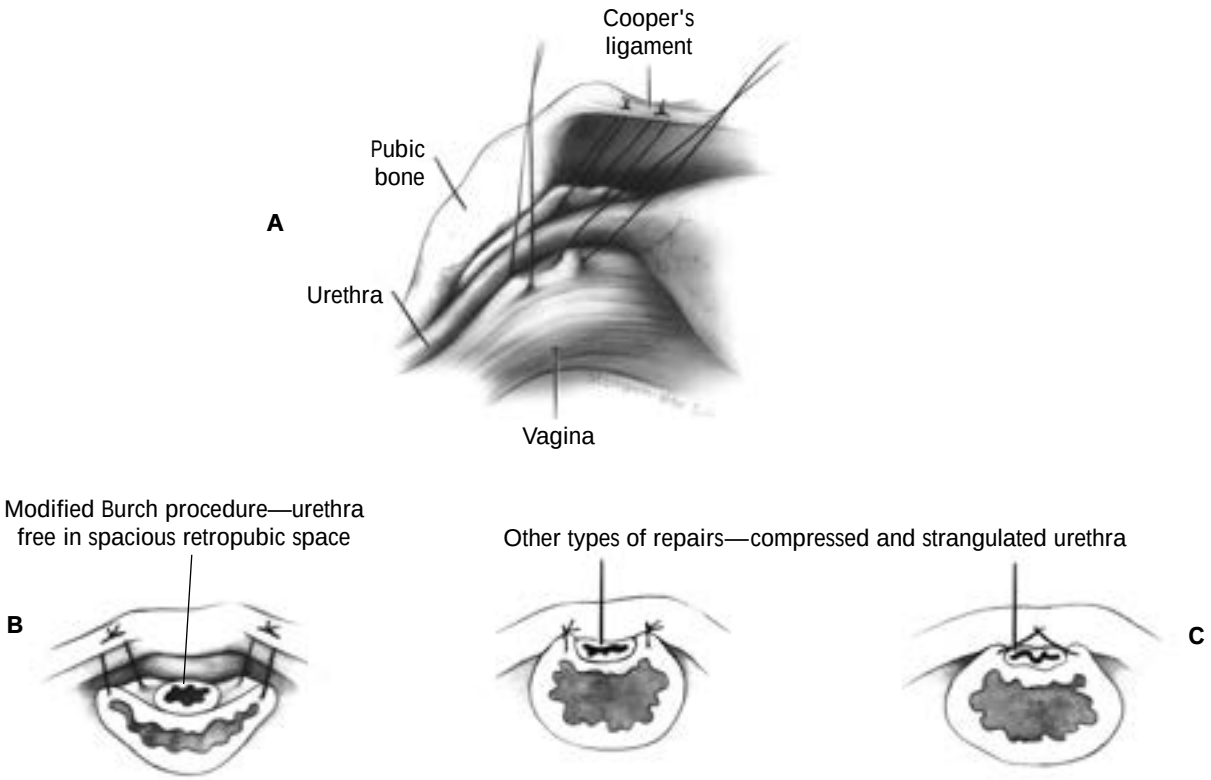

From Tanagho EA: Colpocystourethropexy, *AUA Update Series,* lesson 27, vol XII, Houston, 1993, American Urological Association, Inc.

16-17

Classic Burch Procedure

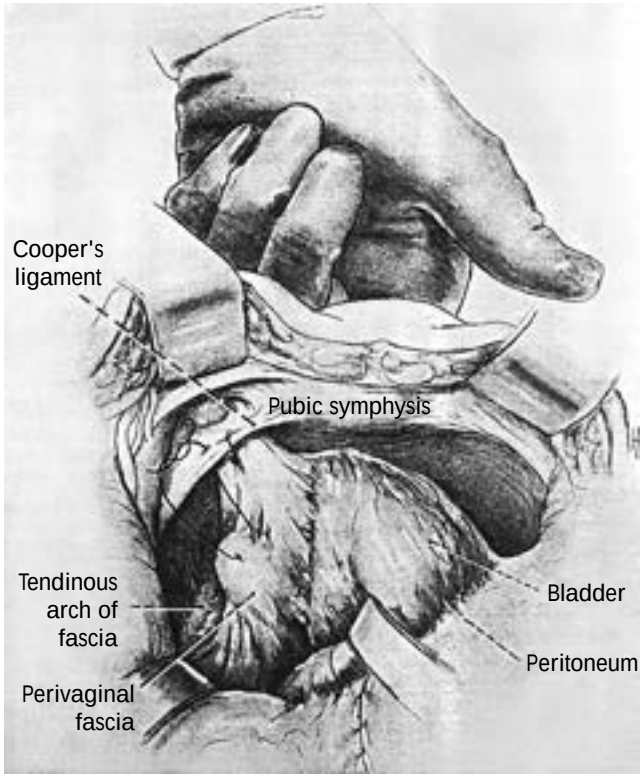

From Burch JC: *Am J Obstet Gynecol* 100:764, 1968.

16-18

Classic Burch Procedure

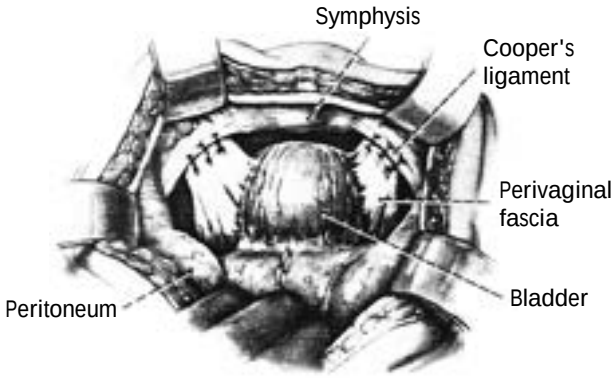

From Burch JC: *Am J Obstet Gynecol* 100:764, 1968.

16-19

KEY POINTS

- A 5 ml Foley balloon catheter is inserted and inflated to 10 ml.
- With an index finger, the surgeon palpates the urethra and the Foley balloon catheter and thus locates the bladder neck.
- Three stitches are placed in the endopelvic and vaginal fascial complex 1 to 1.5 cm lateral to the imaginary horizontal line at the bladder neck.
- Proper exposure of the Cooper's ligament is obtained and precautions are followed to avoid injuring the femoral vein.
- When the Cooper's ligament and the endopelvic and vaginal fascia complex are approximated, the six pairs of stitches are tied without any attempt to pull the vaginal fascia next to the Cooper's ligament. The three pairs of stitches are tied on each side, leaving a 3 to 5 cm suture gap after all pairs are tied.

POTENTIAL PROBLEMS

- *Bleeding at site of endopelvic and vaginal fascial stitches:* Tie the sutures → later, suspension will arrest the bleeding
- *Stitch is too distal to bladder neck region:* Remove and place another stitch
- *Accidental placement of stitches through vaginal epithelium:* Stitches will pull in, and the vaginal epithelium will overgrow the sutures
- *Frozen endopelvic and vaginal fasciae from previous surgery:* Consider a sling procedure
- *Femoral vein puncture:* Manually compress the Cooper's ligament → start over at a different, more medial area of the Cooper's ligament
- *Cooper's ligament is scarred, weak, or destroyed from previous surgery:* Consider use of anterior rectus fascia for the anchoring stitch

REFERENCES

1 Tanagho EA: Colpocystourethropexy: the way we do it, *J Urol* 116:751, 1976.

2 Bergman A, Koonings PP, Ballard CA: Primary stress urinary incontinence and pelvic relaxation: prospective randomized comparison of three different operations. *Am J Obstet Gynecol* 161(1):97, 1989.

3 Edwards EA, Malone PD, MacArthur JD: *Operative anatomy of abdomen and pelvis,* Philadelphia, 1975, Lea & Febiger, pp 37-44.

4 Burch JC: Cooper's ligament urethrovesical suspension for stress incontinence, *Am J Obstet Gynecol* 100:764, 1968.

SUGGESTED READINGS

Marshall VF, Marchetti A, Krantz K: Correction of stress incontinence by simple vesicourethral suspension, *Surg Gynecol Obstet* 88:508, 1949.

Mostwin JL: Current concepts of female pelvic anatomy and physiology, *Urol Clin North Am* 18(2):175, 1991.

Rutledge RH: Cooper's ligament repair: A 25-year experience with a single technique for all groin hernias in adults. *Surgery* 103(1):1, 1988.

Rutledge RH: Cooper's ligament repair for adult groin hernias, *Surgery* 87(6):601, 1980.

Wheeless CR: *Atlas of pelvis surgery,* ed 2, Philadelphia, 1988, Lea & Febiger.

REPAIR OF LARGE CYSTOCELE WITH RAZ SUSPENSION

17

VAGINAL INCISION AND DISSECTION

Premarin cream application to the anterior vagina daily for 1 month before cystocele repair enriches the vasculature and thickens the vaginal epithelium, improving conditions for a favorable surgical outcome.

FIGS. 17-1 AND 17-2. After traction sutures have been placed on the labia majora, a weighted speculum is inserted for proper exposure of this area.

FIG. 17-3. With an Allis clamp applied just below the urethral meatus for traction, the surgeon injects saline solution from a point 2 cm below the meatus down the entire cystocele *(dashed line).* The saline solution injections facilitate the dissection of the plane between the vaginal epithelium and the vesical tissues.

Allis clamps are applied at 2 cm intervals along the midline for traction *(triangles).*

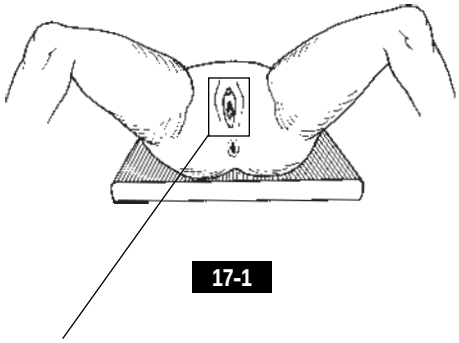

17-1

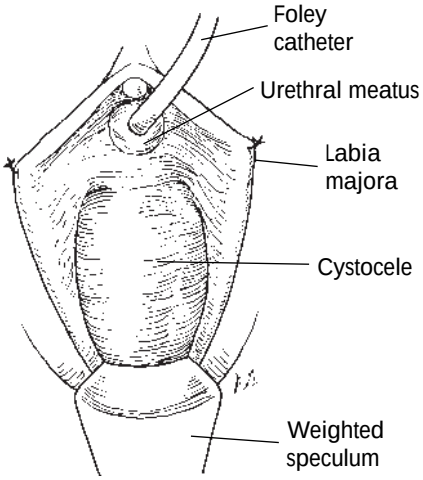

17-2

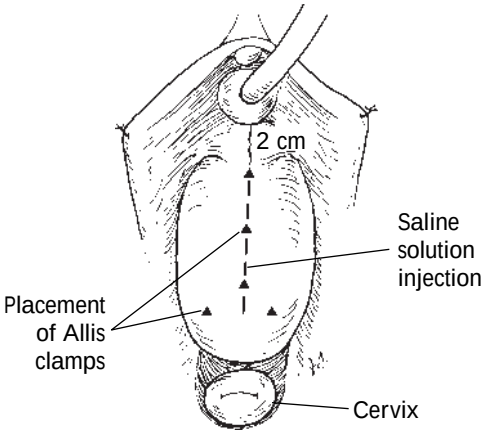

17-3

FIGS. 17-4, 17-5, AND 17-6. The dissection should begin in the middle of the cystocele and work toward the urethral meatus first, especially if a hysterectomy was previously performed. Often in this situation an enterocele lies posterior to the cystocele.

FIG. 17-7. After the initial incision and dissection with scissors, the surgeon can make a few gentle vertical strokes with the knife on the vaginal side to find the proper plane for the subsequent blunt dissection.

FIGS. 17-8 AND 17-9. Using an index finger with one layer of gauze over it, the surgeon can push against the vaginal wall and further separate the plane between the vaginal epithelial layers and the bladder.

FIG. 17-10. With cephalad blunt dissection, the surgeon can free the entire cystocele from the vaginal epithelium.

Cephalad and Lateral Traction to Ease Sharp Dissection

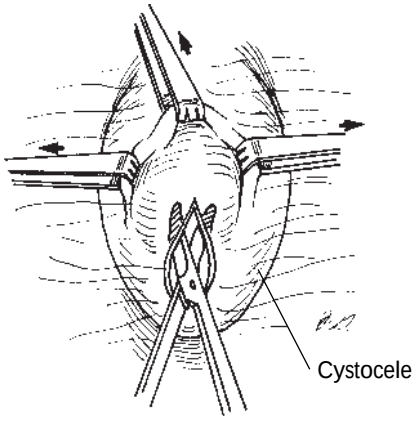

17-4

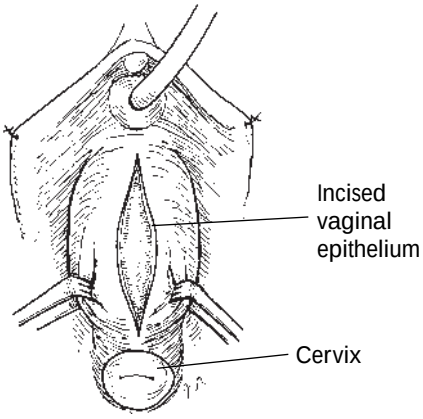

17-5

Common Posthysterectomy Configuration

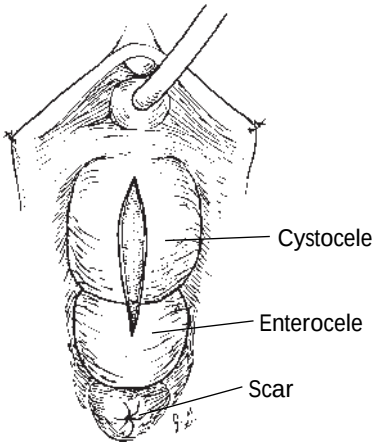

17-6

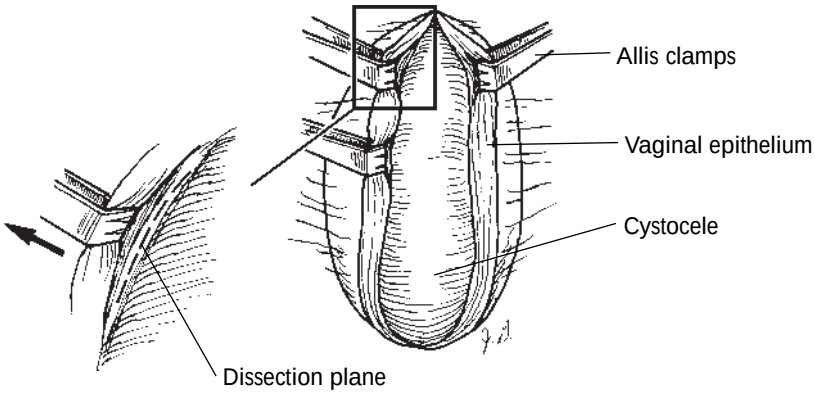

17-7

Finger/Sponge Maneuver for Blunt Dissection

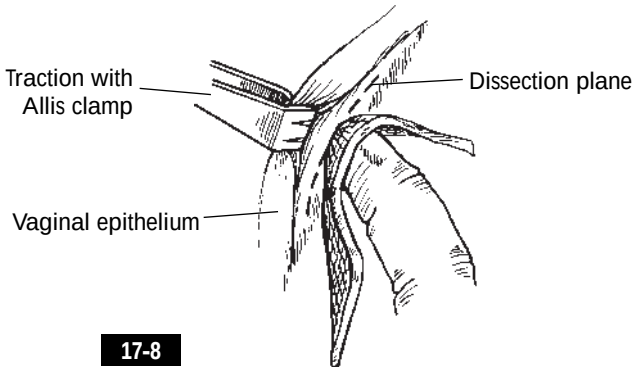

17-8

Completed Blunt Dissection

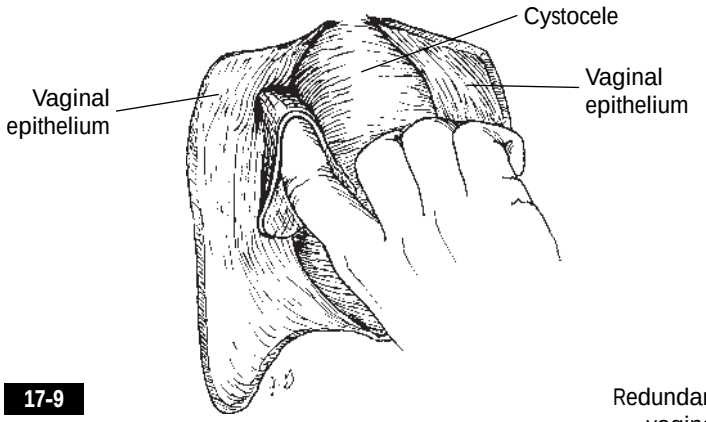

17-9

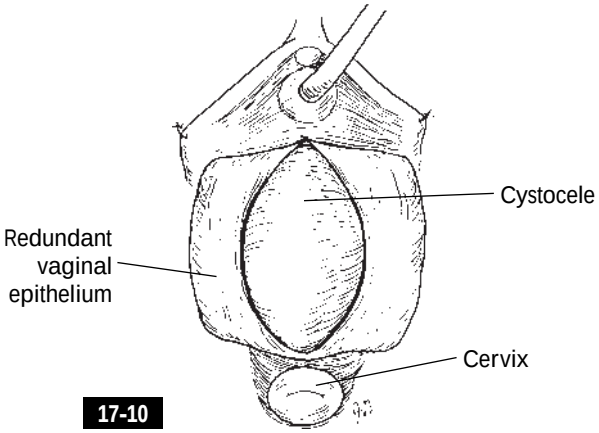

17-10

ASSOCIATED ENTEROCELE REPAIR

FIG. 17-11. Patients with a large cystocele and who have undergone hysterectomy often have an enterocele posteriorly.

As the dissection proceeds posteriorly, the surgeon will notice the enterocele, which is characterized by a more delicate prolapse of the peritoneal membrane.

It is often difficult to dissect the enterocele completely without penetrating the thin peritoneal membrane. However, reduction with a pursestring stitch (2-0 chromic) corrects the problem.

Common Posthysterectomy Configuration

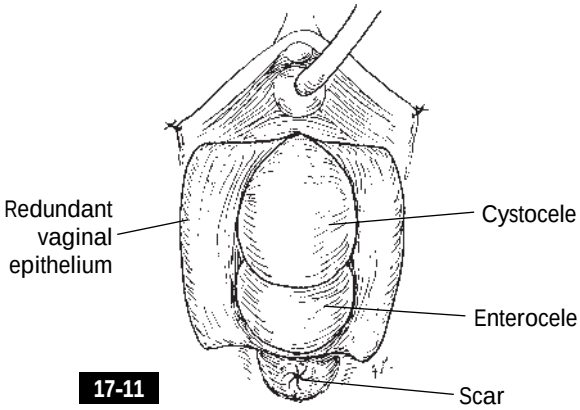

17-11

ASSOCIATED STRESS INCONTINENCE REPAIR

FIG. 17-12. If the cystocele is associated with stress incontinence or if the patient is at risk for developing stress incontinence after cystocele repair, the surgeon should perform the Raz procedure at this point (see p. 139).

Using an index finger, the surgeon perforates the pelvic fascial complex. Helical stitches (1-0 Prolene) are then placed on both sides of the bladder neck, brought above, and anchored to the anterior rectus fascia.

REDUCTION OF CYSTOCELE

FIG. 17-13. With adequate cephalad dissection on both sides of the cystocele, the surgeon should be able to separate the cystocele from all layers of the vaginal epithelium. Ideally this cephalad dissection will reveal the pubocervical fascia[1] or the levator ani muscle[2] on both sides of the cystocele.

FIG. 17-14. The pubocervical fascia is reapproximated.

FIGS. 17-15, 17-16, AND 17-17. At times, even with aggressive cephalad dissection, the pubocervical fascia cannot be identified or is too thin and friable for reapproximation. In these situations we have simply reapproximated all layers of the vaginal epithelium using mattress stitches (0 Vicryl) with excision of the redundant tissues. Our experiences show that full-thickness vaginal epithelium approximation alone is just as effective as reapproximating an extra layer of the pubocervical fascia.

Index Finger Maneuver After Perforation of Pelvic Fascial Complex (Urethropelvic Fascia)

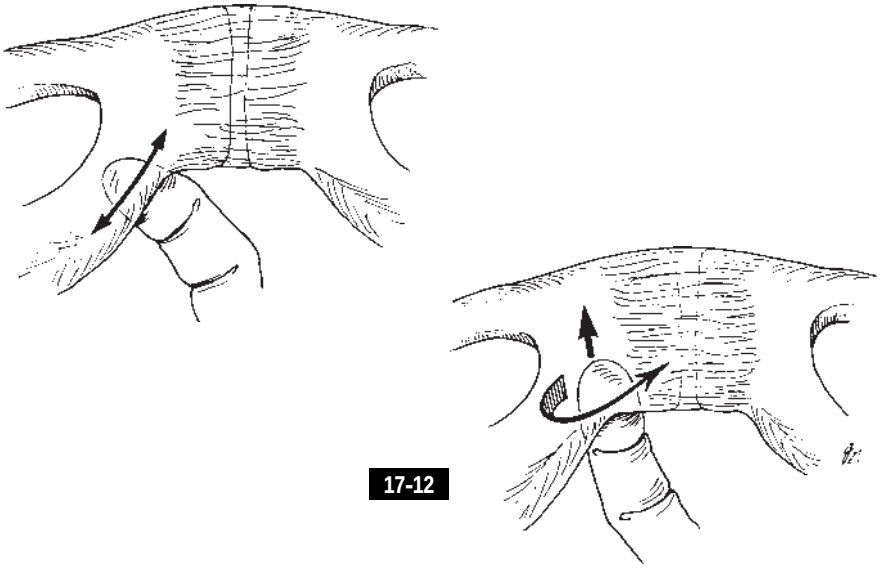

17-12

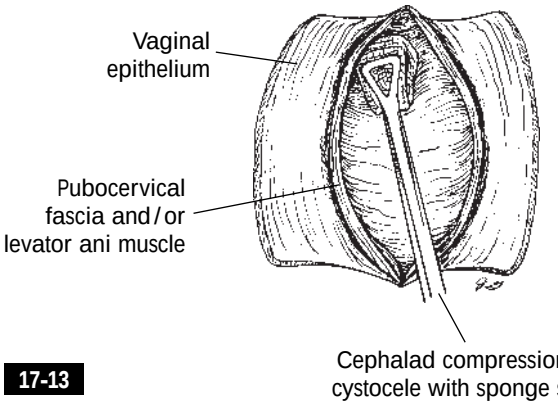

17-13

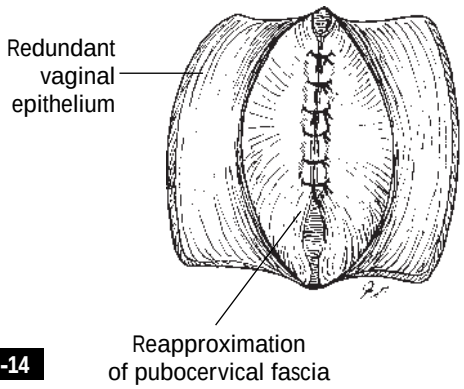

17-14

Cross-sectional View

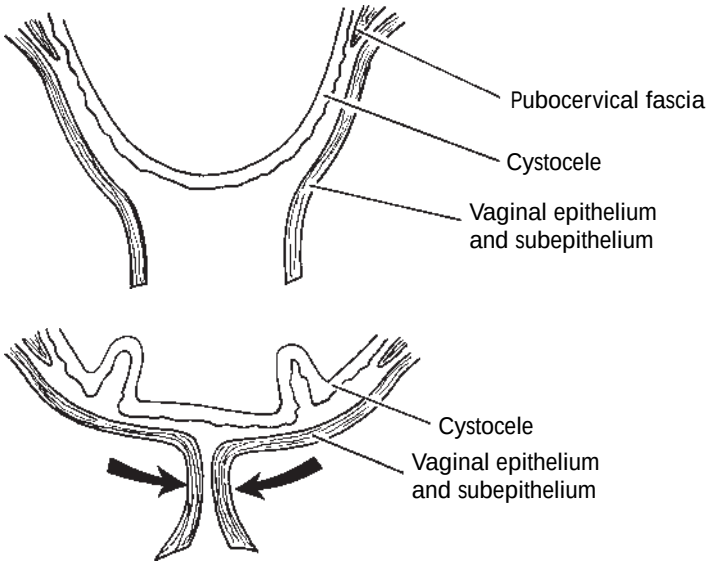

17-15

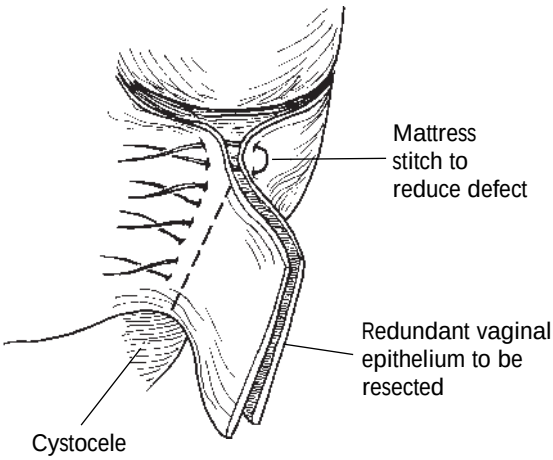

17-16

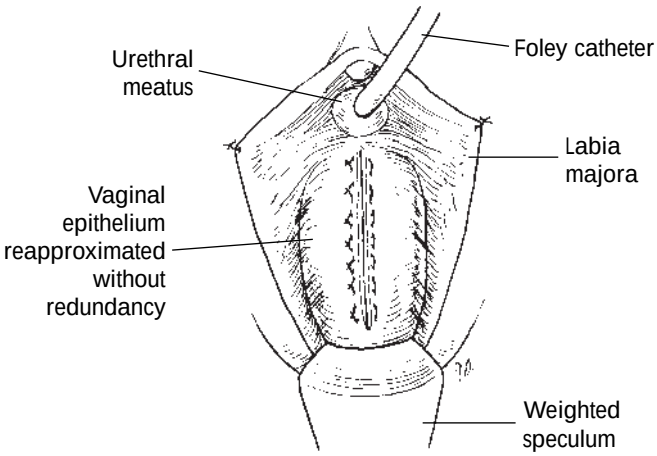

17-17

KEY POINTS

- Premarin cream is applied to the vaginal wall for 1 month before surgery.
- Saline solution is injected along the midline of the cystocele to separate the vaginal epithelium from the vesical tissues.
- A vertical incision is made starting in the middle of the cystocele and working anteriorly toward the urethral meatus rather than posteriorly. In patients who have had a hysterectomy, enteroceles often lie posteriorly.
- With a plain sponge over the index finger, the surgeon separates the entire cystocele from the vaginal epithelium.
- The Raz procedure is performed for correction of stress incontinence.
- The pubocervical fascia (levator ani muscle) is exposed bilaterally to the cystocele and is reapproximated.
- The vaginal epithelium and subepithelium are reapproximated and the redundant tissue is resected.

POTENTIAL PROBLEMS

- *Injury to bladder:* Close the bladder → place ureteral stent if needed
- *Difficulty locating pubocervical fascia:* Approximate the vaginal epithelium with mattress stitches and resect redundant tissues

REFERENCES

1 Raz S: *Atlas of transvaginal surgery*, Philadelphia, 1992, WB Saunders.

2 Leach GE: Vaginal anatomy and preoperative preparation for vaginal surgery, *Urol Clin North Am* 2(1):1, 1994.

RADICAL RETROPUBIC PROSTATECTOMY

18

PATIENT POSITIONING

FIGS. 18-1, 18-2, AND 18-3. Flexion of the body with the break of the operating table in line with the anterior superior iliac spine of the pelvis will consistently provide maximal exposure of the pelvis.

FIG. 18-4. In addition, abduction of the legs with flexion at the knees will facilitate the pelvic lymphadenectomy procedure.

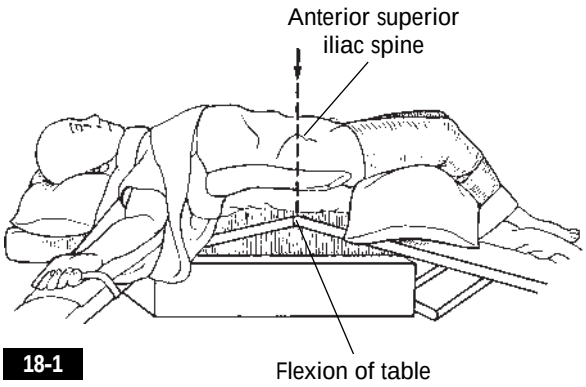

18-1

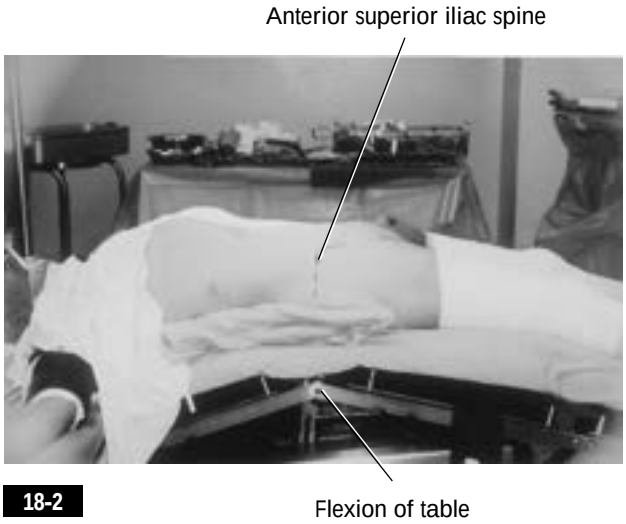

18-2

A

B

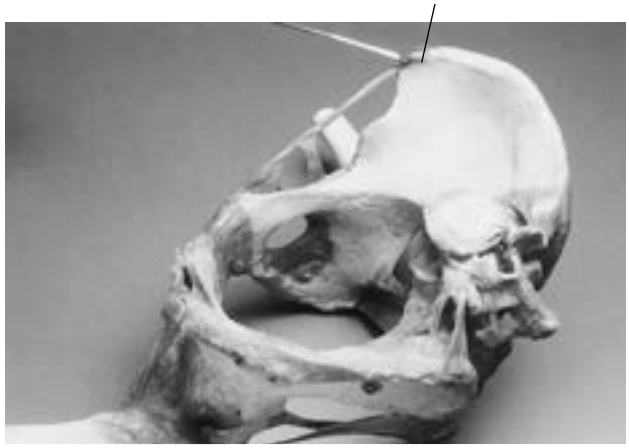

18-3

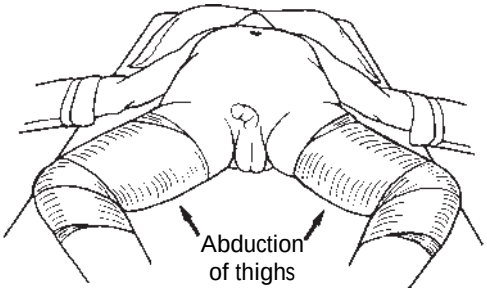

18-4

EXPOSURE OF RETROPUBIC AND RETROPERITONEAL SPACES

FIG. 18-5. Once the space of Retzius (retropubic space) is established, the surgeon can create the retroperitoneal pockets.

FIG. 18-6. With the hand palm side up and the index finger hugging the lateral wall of the pelvis slightly below the level of the iliac vein, the surgeon uses the index and middle fingers to gently tunnel behind the peritoneum and into the retroperitoneal space.

FIG. 18-7. This maneuver exposes the bifurcation of the iliac vessels, the lymph nodes most commonly involved in prostate cancer metastasis, the ureter medially, and the vas deferens coursing above and across the peritoneal shelf.

FIG. 18-8. Once the Balfour or Bookwalter retractor is in place, a narrow malleable blade can be positioned within these retroperitoneal pockets and fixed cephalad to the retractor.

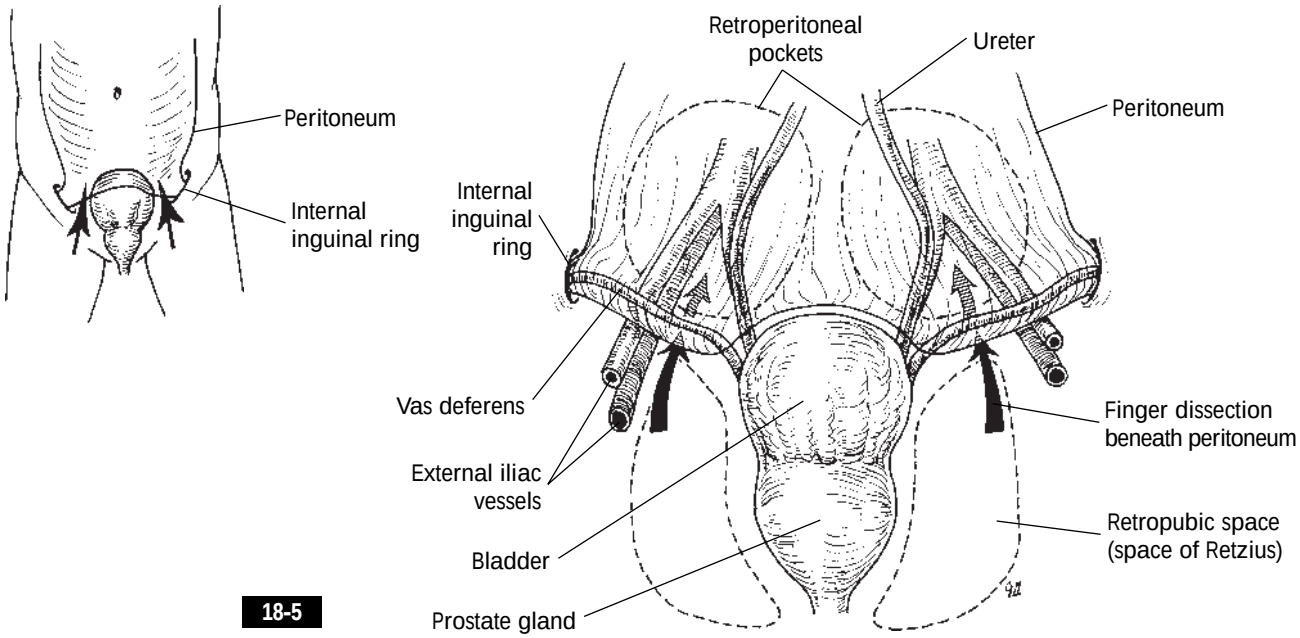

18-5

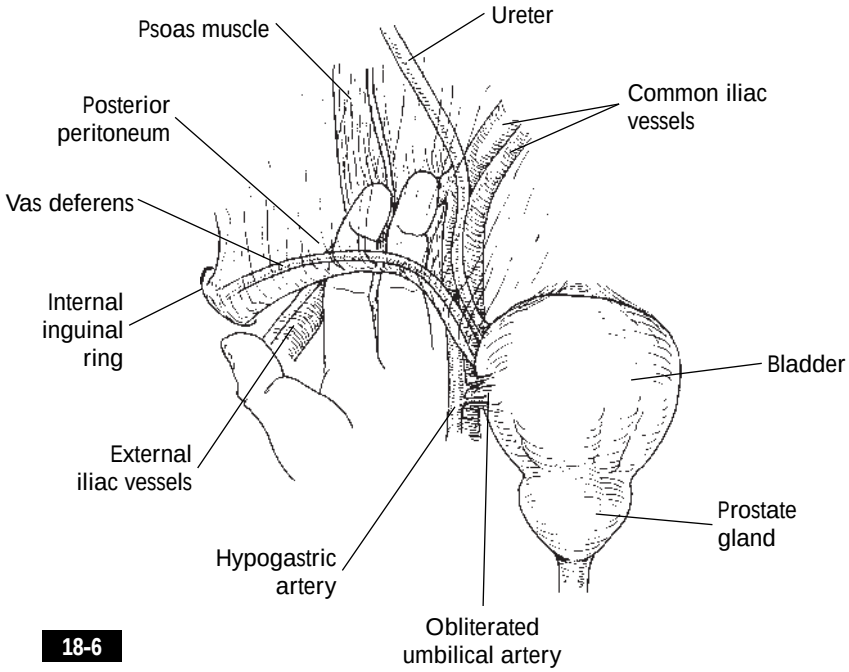

18-6

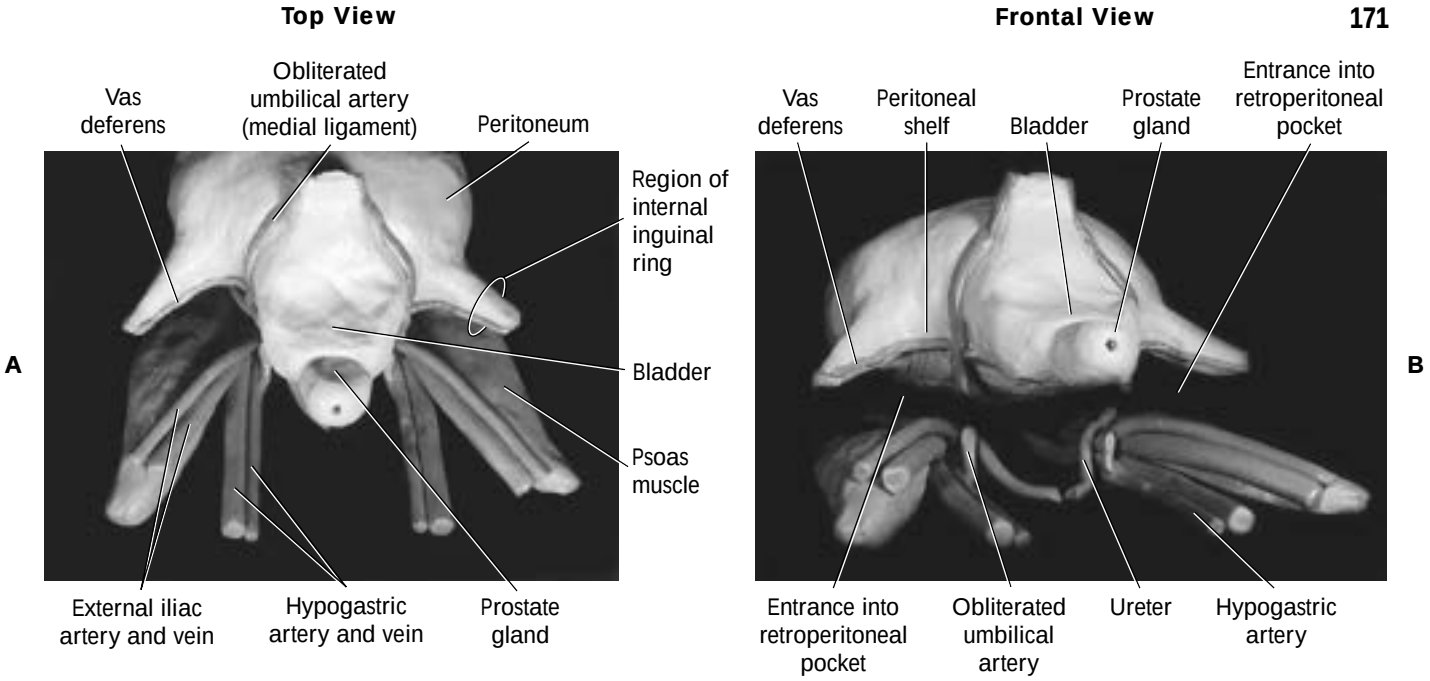

18-7

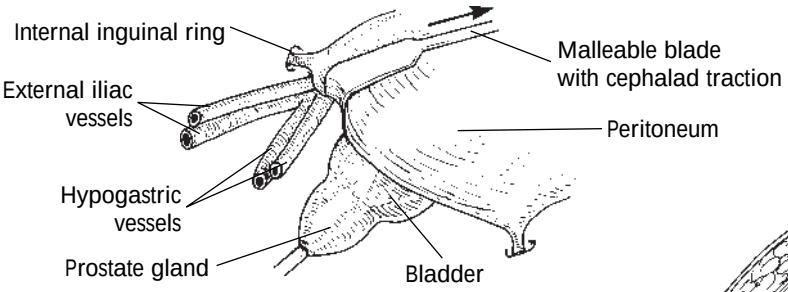

18-8

PELVIC LYMPH NODE DISSECTION

FIG. 18-9. By opening the space between the lowermost aspect of the iliac vein and the fatty tissues below, the surgeon uses Kitners (tonsil clamp with ball of gauze clamped at its tip) to push the iliac vein away from the fatty and lymphatic tissues until the pelvic wall is identified.

FIG. 18-10. With the middle and index fingers, the surgeon palpates for the pelvic wall and moves the index finger horizontally in a back-and-forth motion to free the obturator nodes packet. The surgeon can simultaneously palpate for the obturator nerve below and use gentle blunt dissection with the index finger and thumb to isolate it.

We have found these maneuvers to be time-saving for a rapid dissection.

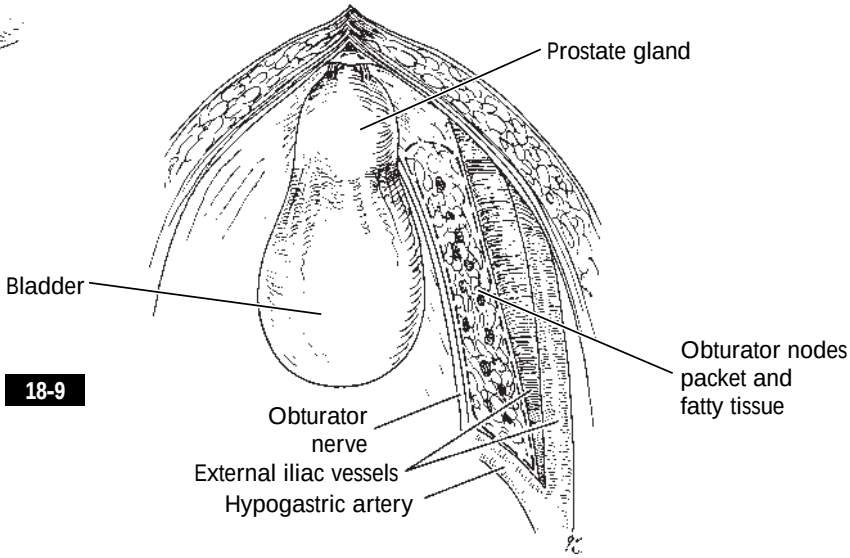

18-9

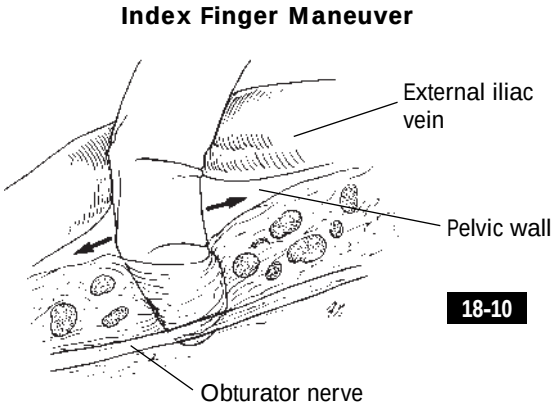

18-10

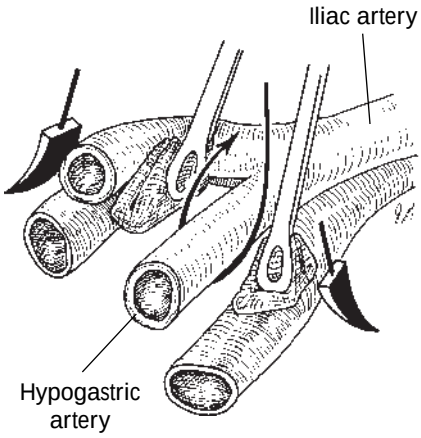

18-11

TEMPORARY LIGATION OF HYPOGASTRIC ARTERY

FIG. 18-11. If there is a good pulse in the hypogastric artery, it should be ligated temporarily as a safety precaution. Hypogastric artery ligation does not prevent bleeding during the later dissection of the dorsal venous complex but will slow down the hemorrhage sufficiently for the surgeon to maneuver and control bleeding points.[1] After maximal cephalad retraction with the malleable blade in the retroperitoneal pocket, the surgeon can identify the iliac vessel bifurcation. By applying sponge sticks on either side of the hypogastric artery, the surgeon can safely place vessel loops twice around and ligate it. We do not use the bulldog clamps in these delicate, small spaces.

LIGATION AND DIVISION OF DORSAL VENOUS COMPLEX

FIG. 18-12. The placement of a ¾-inch Penrose drain tightly clamped around the base of the penis will decrease the potential bleeding during division of the dorsal venous complex.[2]

FIGS. 18-13 AND 18-14. The Yu-Holtgrewe grooved blade (Greishaber Co., Chicago, Ill.) is placed over the bladder, and then the Foley balloon catheter (inflated to 30 ml) is retracted cephalad slowly and fixed to the Balfour or Bookwalter retractor.[3]

FIG. 18-15. The key maneuver of cephalad traction with the grooved blade and downward traction with a sponge stick exposes the puboprostatic ligaments.

With the removal of the fat around the puboprostatic ligaments and endopelvic fascia, the surgeon can clearly see the ligaments and lateral fascia.

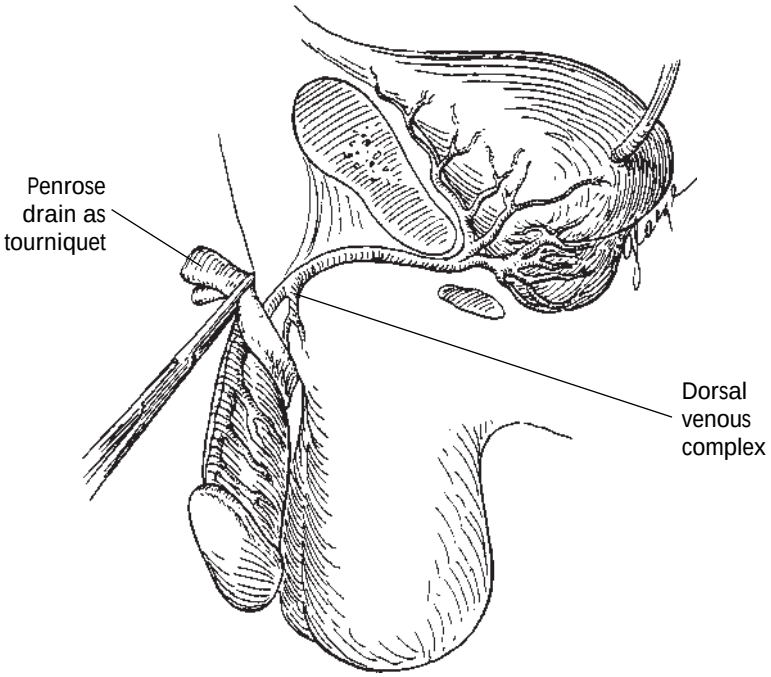

From Kaufman JJ, Katske FA: *Urology* 20:309, 1982.

18-12

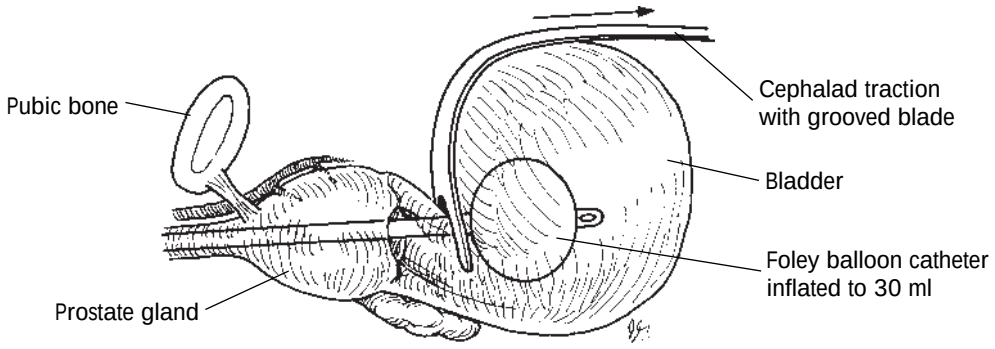

18-13



18-14

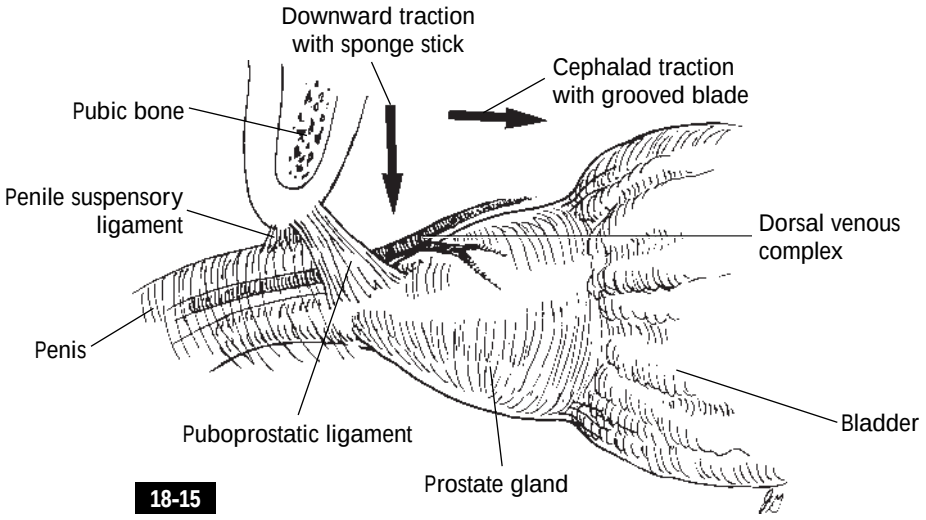

18-15

FIGS. 18-16 AND 18-17. The puboprostatic ligaments are not just fibrous, bandlike structures viewed from the space of Retzius but are thickened, pyramid-shaped structures that can vary in configuration (length and width) and in position to each other.[4] If the ligaments are wide apart and long, small "nibbles" of the superficial bands with scissors and a subsequent "finger-fracturing" or "pinching" can be performed to loosen the prostatic apex. This maneuver should be performed after the endopelvic fascia is opened bilaterally.

FIG. 18-18. The traditional approach is to divide the puboprostatic ligament separately from the dorsal venous complex *(1)*. However, if the puboprostatic ligaments are close together, then these ligaments and the dorsal venous complex can be tied together as one unit and divided proximal to the ties away from the ligament insertions to the pubic bone[5,6] *(2* and *3)*. A 2 to 3 cm margin must be developed between the urethra and dorsal venous complex *(4)*.

Variations in Configuration of Puboprostatic Ligaments

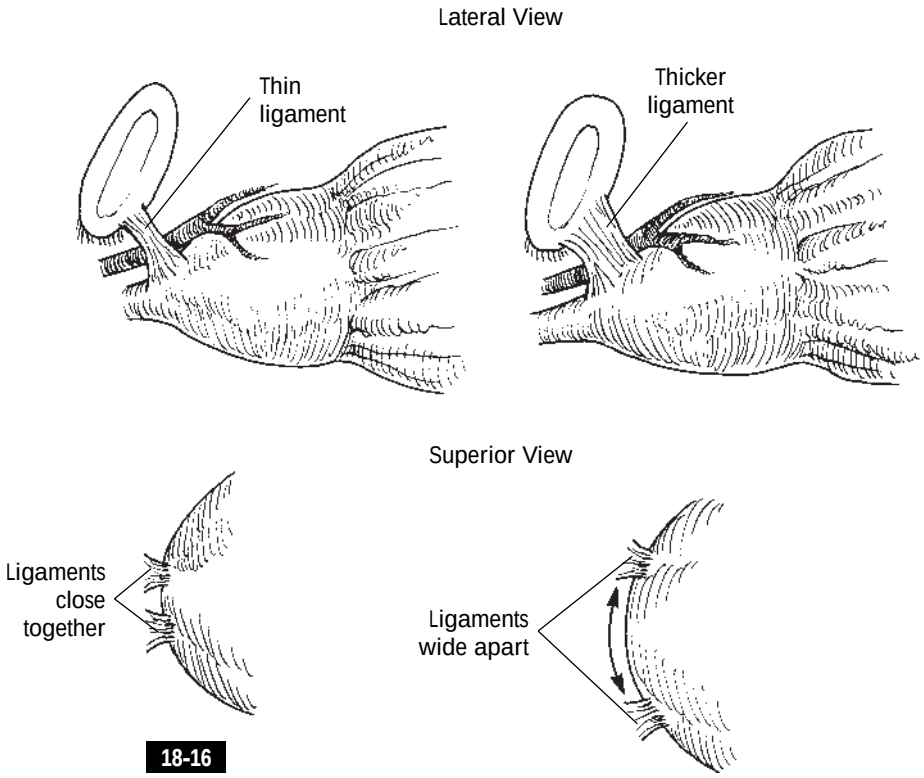

18-16

Retropubic View

A

Retropubic View (Oblique Angle)

B

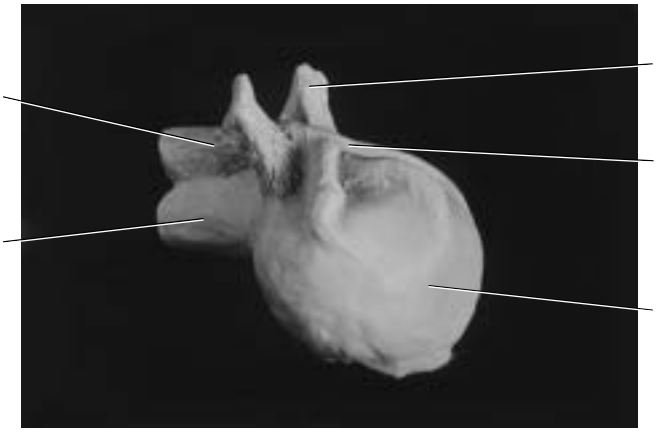

18-17

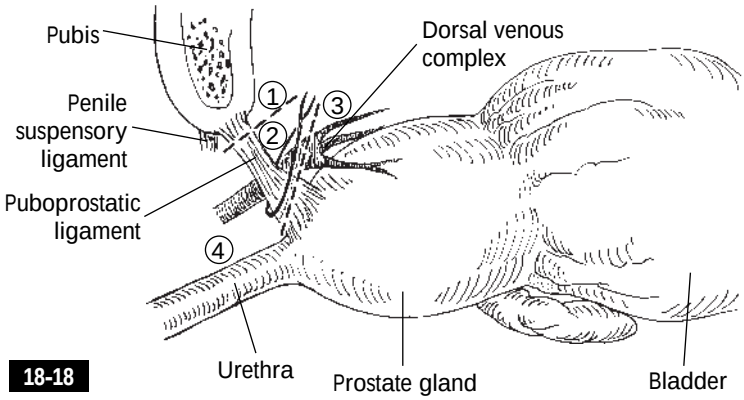

18-18

FIGS. 18-19, 18-20, AND 18-21. The surgeon can tunnel the index finger and thumb within the endopelvic fascia and "finger-pinch" a plane between the dorsal venous complex and the urethra (Figs. 18-19, **A,** and 18-20). The dorsal venous complex, a combination of fatty, fibrous tissues and venous channels, is about 2 cm in diameter.

At the patient's left side, a simple maneuver is for the surgeon to insert the left hand, rotated 180 degrees clockwise at the wrist with the palm up (Fig. 18-19, **B**), and then, using the left thumb and index finger, feel the dorsal venous complex and the urethra with the Foley catheter within.[5,6]

FIG. 18-22. Since the diameter of the dorsal venous complex varies, the surgeon may opt to use right-angle clamps, which are available with different lengths of the angled nose.

Top View

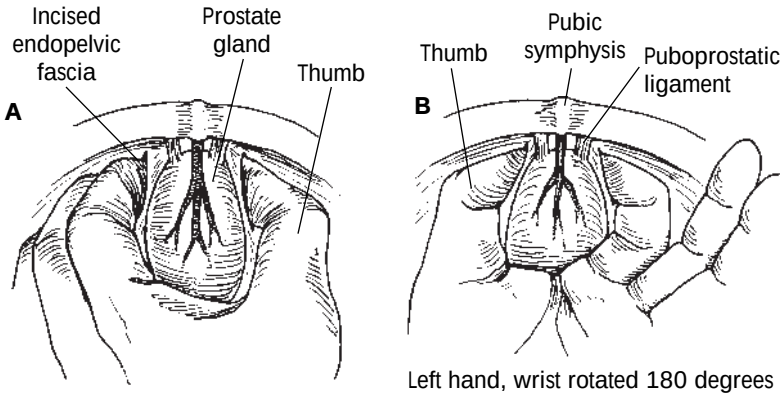

Right hand and finger dissection

Left hand, wrist rotated 180 degrees clockwise, palmar side up (surgeon on patient's left side)

18-19

Cross-sectional View

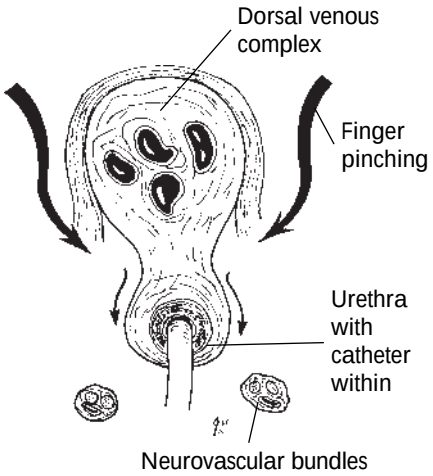

18-20

View from Anterior Side (Penile Base) Without Pubic Bone

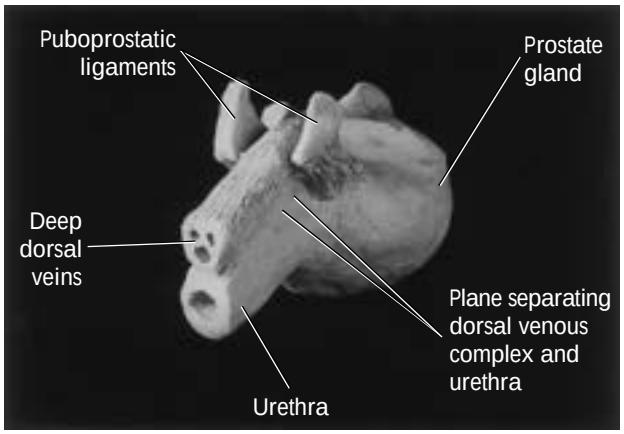

18-21

FIGS. 18-23 AND 18-24. The surgeon guides the right-angle clamp down and adjacent to the index finger for the blind placement of the clamp in the plane between the dorsal venous complex and urethra. The surgeon then uses the index finger or middle finger to feel the clamp from the other side to determine the correct site for the actual puncture.

FIG. 18-25. Because venous bleeding often obliterates the tip of the right-angle clamp, a suction tip placed against the right-angle clamp tip will clear the operative field and facilitate placement of the ties.

Variations in Right-Angle Clamps

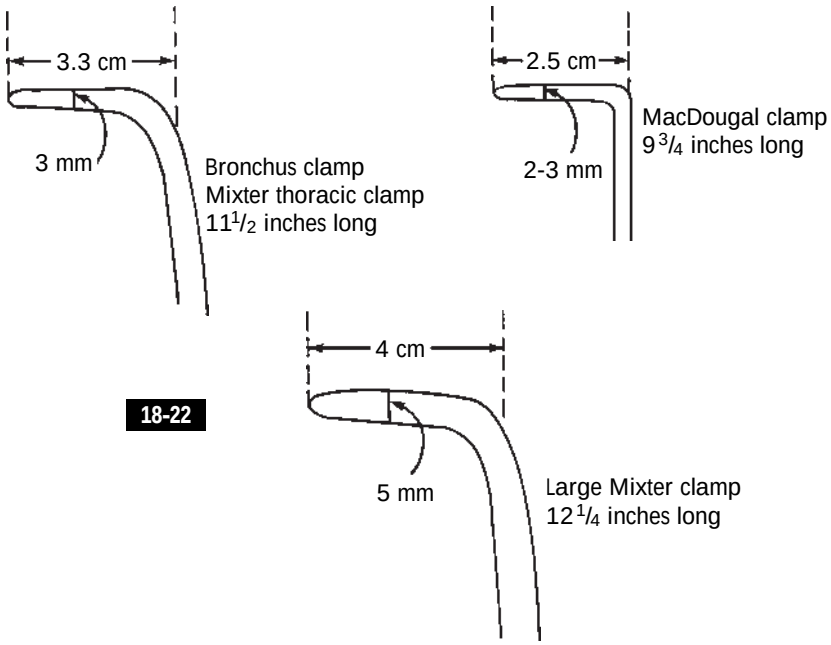

18-22

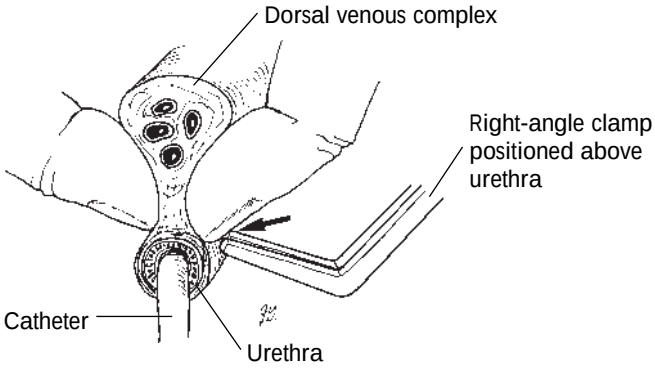

18-23

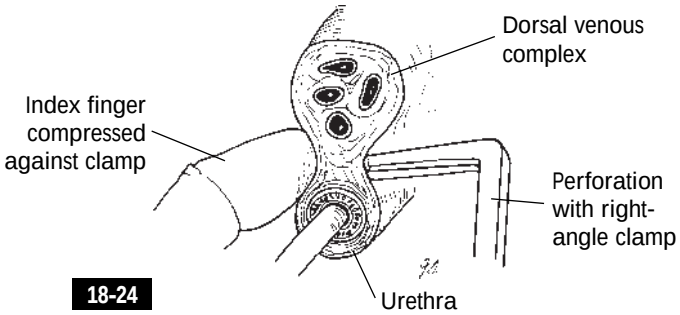

18-24

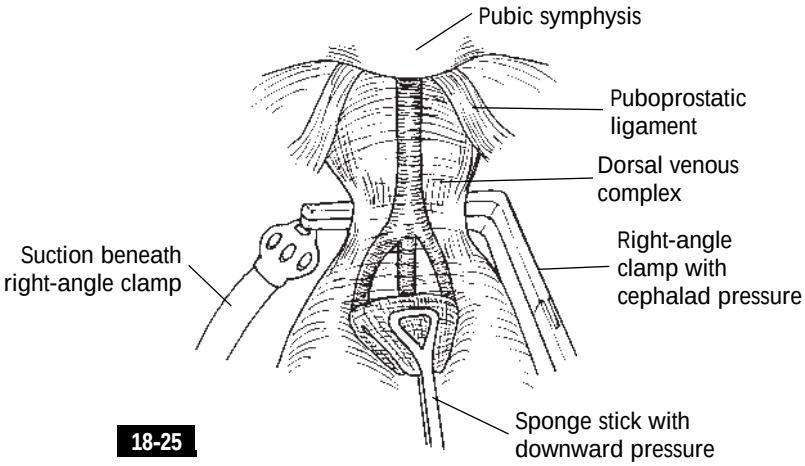

18-25

Dorsal Vein Ligation and Stitch
Exclusive of Puboprostatic Ligaments

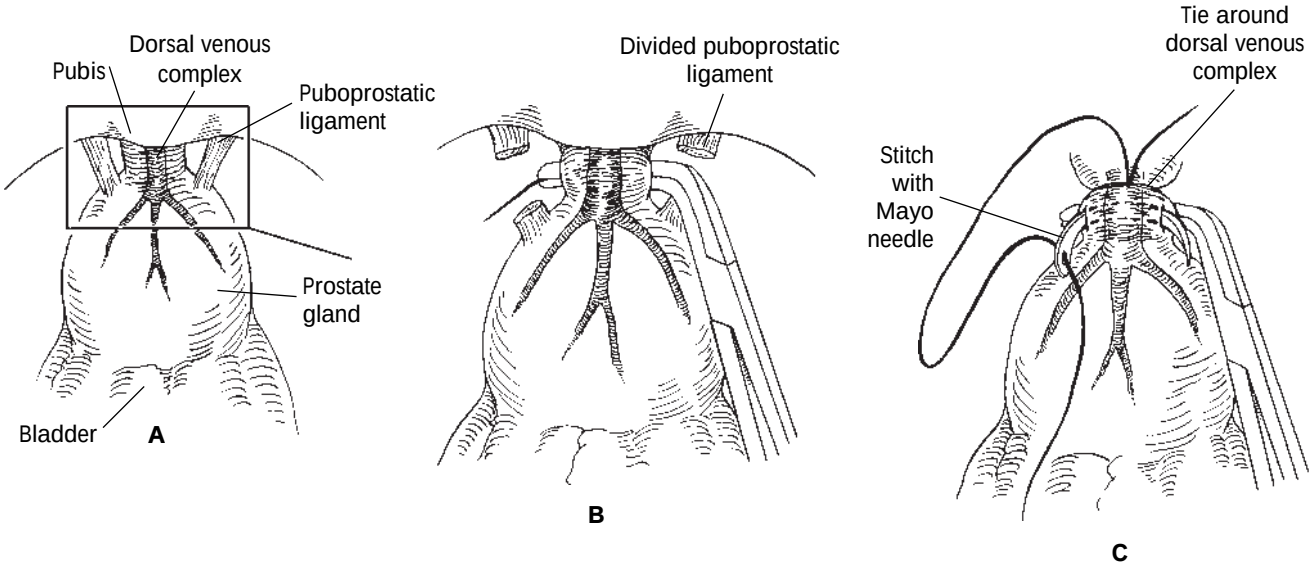

Dorsal Vein Ligation
Inclusive of Puboprostatic Ligaments

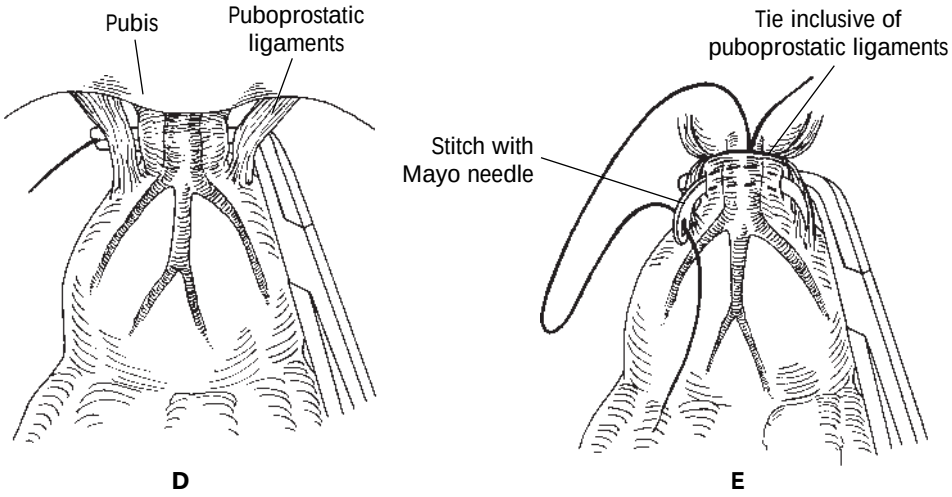

18-26

FIG. 18-26. A free margin 2 to 3 cm long between the dorsal venous complex and the urethra is established (**A** and **B**). A long tie (1-0 Vicryl) is passed around the dorsal venous complex and tied. With a right-angle clamp placed below the ligated dorsal venous complex (exclusive of the divided puboprostatic ligaments **[B]** or inclusive of the intact puboprostatic ligaments **[D]**), the surgeon can thread one free end of the Vicryl tie through a No. 3 Mayo needle and place a back-handed figure-of-eight stitch through the dorsal venous complex **(C** and **E).** This maneuver will prevent tie slippage and can be repeated as many times as needed before the dorsal venous complex is divided proximal to the ties.

After tying the dorsal venous complex but before dividing it, the surgeon uses an index finger and thumb to gently feel the urethra and establish a plane around it. With the index finger and thumb encircling the urethra from the 12-o'clock position to the 6-o'clock position, the surgeon avoids the neurovascular bundles, which are inferior to the urethra on both sides.

FIG. 18-27. Although the surgeon's goal is to isolate the urethra, we believe any urethral mobilization and isolation with a right-angle clamp or finger-pinching will incorporate some but not all of the striated urethral sphincter (rectourethralis muscle).[7]

An umbilical tape is passed around the urethra and placed on traction.

FIGS. 18-28 AND 18-29. The superficial fascia covering the anterior region of the prostate gland can be divided before or after the division of the dorsal venous complex and urethra. We prefer to divide it bilaterally immediately after the ligation of the dorsal vein when the anterior prostate anatomy is not yet distorted or bloody. This thin fascia can be divided from the bladder to the apical region of the prostate gland or in reverse, depending on the surgeon's preference. This maneuver allows the surgeon to tease the neurovascular bundles from both sides of the prostate gland if a nerve-sparing procedure is desired.

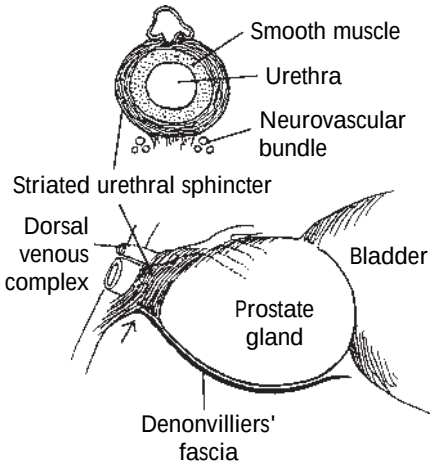

From Myers RP, Goellner JR, Cahill DR: *J Urol* 138:543, 1987.

18-27

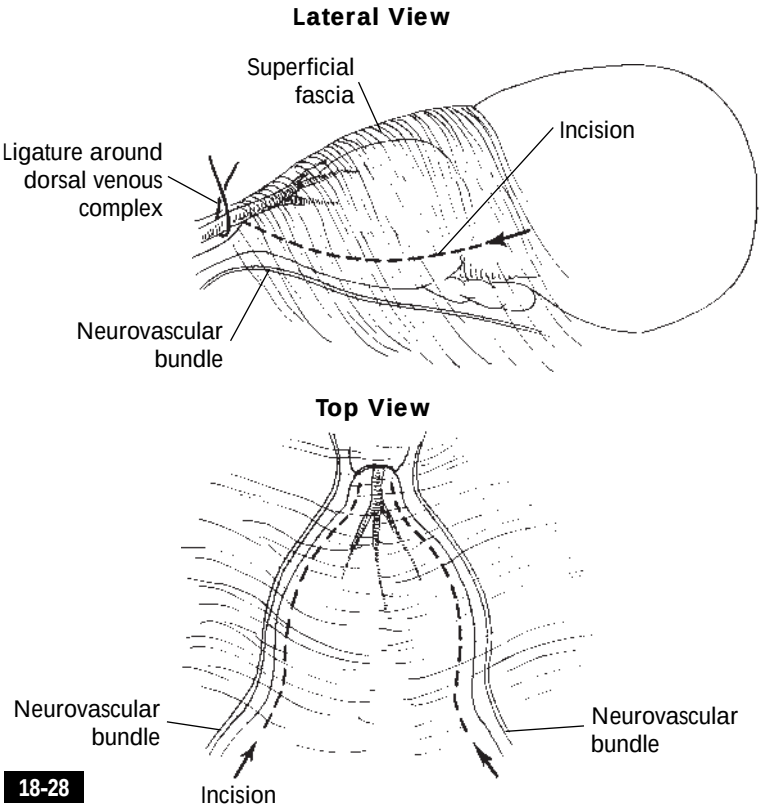

18-28

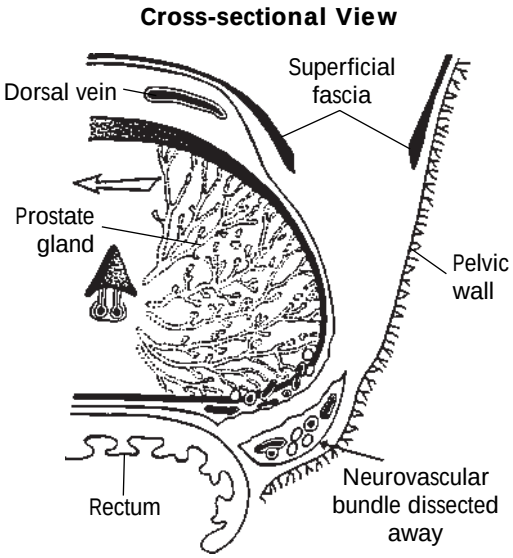

Courtesy Dr. T. Stamey.

18-29

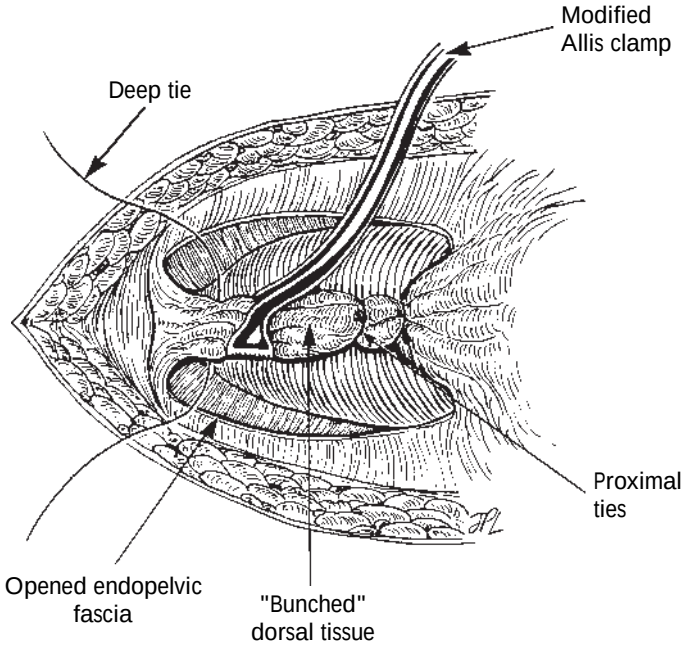

From Myers RP: *J Urol* 142:1282, 1989.

18-30

FIG. 18-30. If there are prominent venous channels more proximally (plexus of Santorini), the "bunching" stitch[8] can prevent backbleeding when the dorsal venous complex is divided. These bunching stitches will incorporate the superficial fascia with the ligated venous structures, thus exposing the lateral region of the prostate gland on each side.

The division of the dorsal venous complex should be angled to parallel the prostatic apex to avoid cutting into the apical region of the prostate gland[9] (see Fig. 18-18).

URETHRAL DIVISION

FIG. 18-31. While the assistant lifts the urethra with the right-angle clamp and applies downward pressure with the sponge stick on the prostatic apex, the surgeon divides the urethra accurately while applying suction. The catheter is pulled up and divided, and its proximal end is clamped.

The grooved blade holding the Foley balloon catheter and bladder cephalad is removed, the balloon is held snug against the prostate gland, and the catheter is retracted cephalad.

The patient, who was in a reverse Trendelenburg position for the dorsal vein division, is then placed in the Trendelenburg position for the best exposure for proximal dissection.

FIGS. 18-32 AND 18-33. With the left index and middle fingertips slightly behind and compressing either side of the residual striated urethral sphincteric muscle (rectourethralis muscle) over the prostatic apex, the surgeon uses scissors first to spread parallel to the muscle fibers and fibrous tissues and then to cut these separated fibers close to the prostate side. The left fingertips are used as a guide to determine the depth of these cuts and to protect the rectum.

Once the striated urethral sphincteric muscle (rectourethralis muscle) is divided, it is easy to establish a plane between the prostate gland and the rectum.

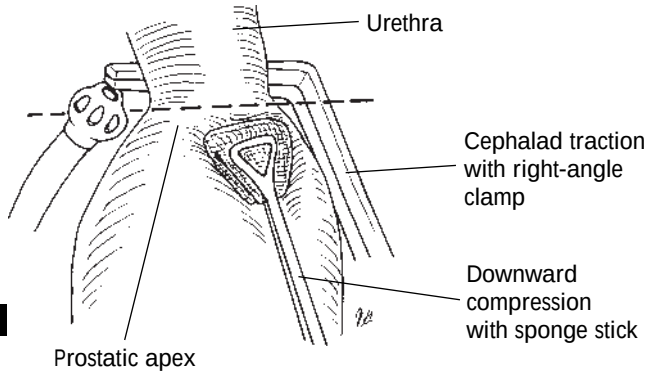

18-31

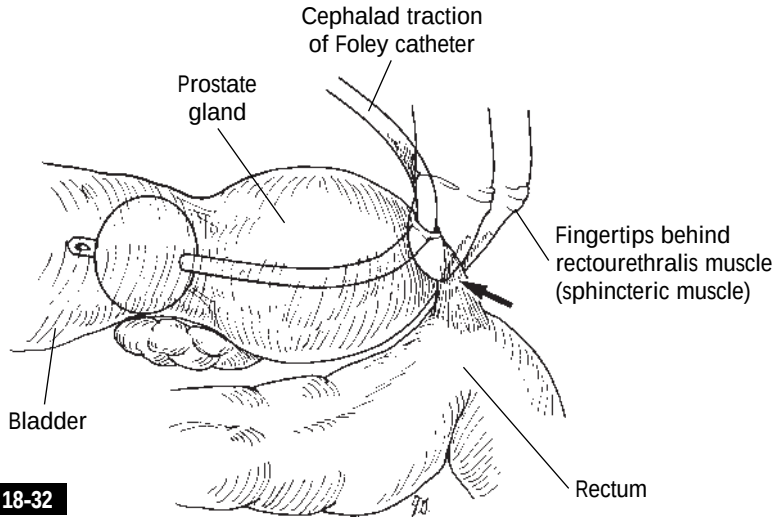

18-32

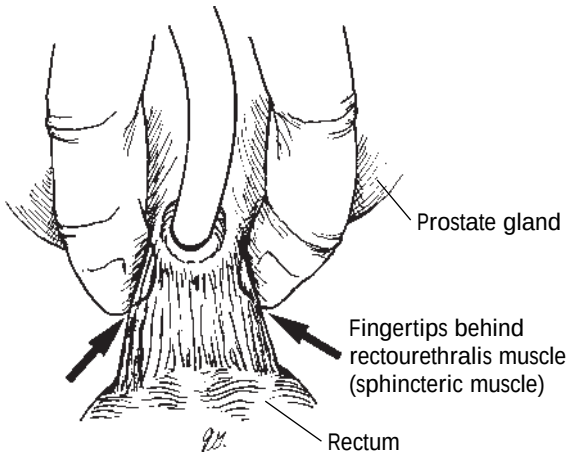

18-33

PROXIMAL PROSTATE AND SEMINAL VESICLE DISSECTION

A key maneuver in this dissection is to use a sponge stick to push down on the rectum while pulling the prostate gland cephalad. Care should be exercised to avoid excessive cephalad retraction of the prostate gland to protect the neurovascular bundles on both sides.

FIG. 18-34. The surgeon incises the Denonvilliers' fascia to expose the seminal vesicles and vasa deferentia proximal to the prostate gland.

The seminal vesicles and the vasa deferentia are exposed; we prefer to divide both vasa deferentia and seminal vesicles at this point without further dissection, thereby not taking the tips of the seminal vesicles with the prostate specimen.[10] If the surgeon chooses to dissect the seminal vesicles and vasa deferentia entirely, blunt and sharp dissection can still be used at this point to separate a plane between the Denonvilliers' fascia and the vasa deferentia and seminal vesicles. This maneuver facilitates the later dissection of the vasa deferentia and seminal vesicles after the bladder neck is divided.

The surgeon can use a right-angle clamp to tunnel inside the open Denonvilliers' fascia and lateral to the seminal vesicles for prostatic pedicle ligation.

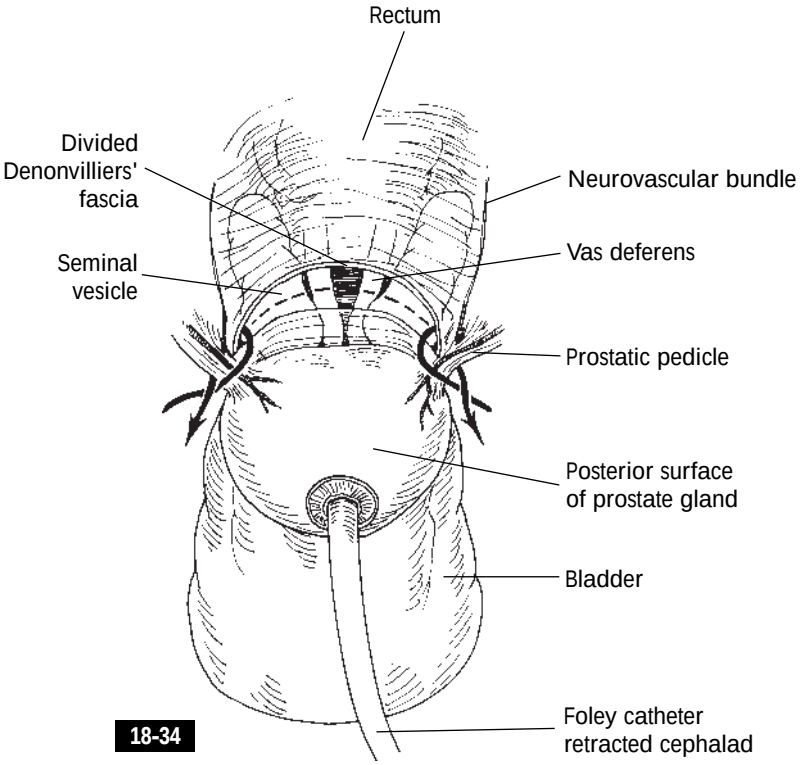

BLADDER NECK RECONSTRUCTION

The usual approach for bladder neck dissection is first to establish a plane between the anterior prostate gland and the bladder.

Once the urethra is opened, the catheter is removed from the bladder and retracted on the prostate side as the bladder is dissected free from the seminal vesicles.

FIG. 18-35. After the prostate gland, vasa deferentia, and seminal vesicles are removed, the surgeon can evert the bladder's epithelial surface and perform a "tennis racquet" reconstruction. The tennis racquet configuration moves the bladder neck cephalad away from the ureters, protecting them from accidental stitch injury.

BLADDER NECK AND PARTIAL PROSTATIC URETHRAL PRESERVATION

For low-stage cancer disease involving peripheral lesions, we prefer to perform bladder neck and partial prostatic urethral preservation because this approach offers earlier postoperative continence recovery and is associated with a lower frequency of severe stricture formation.[5, 11-14]

It is well known that prostatic glands can drain directly into the bladder neck and even as far as the trigone region.[15] However, isolated adenocarcinoma of the prostate gland involving these glandular tissues is rare.

The frequency of isolated adenocarcinoma in the transition zone of the prostate gland at the bladder neck region is approximately 3% to 6%.[11,16] However, the frequency of cancer involvement of the prostatic apex region is much higher. More commonly, cancer involvement of the region near the prostatic urethra and bladder neck is secondary to extension of larger cancers with multifocal involvement.[12]

We believe that with careful selection of patients with low-stage peripheral disease, bladder neck and partial prostatic urethral preservation can be performed safely without the risk of leaving cancer behind.[17] Routine biopsy of the prostatic cuff and bladder neck has rarely shown adenocarcinoma. If it is positive for cancer, we have resected the bladder neck as described previously.

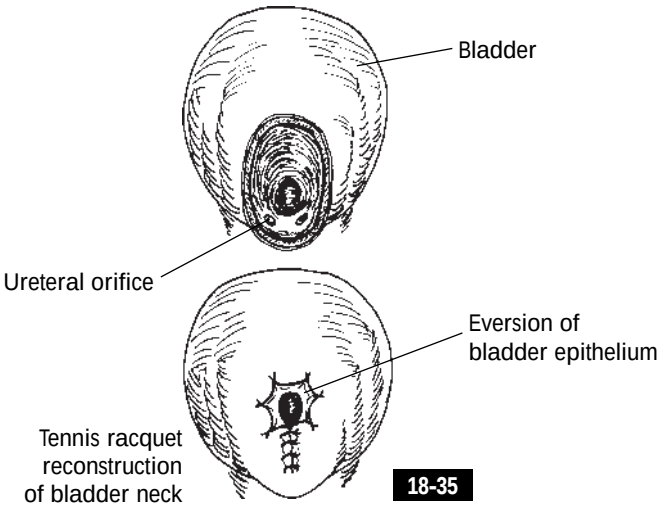

Bladder Neck and Partial Prostatic Urethral Preservation

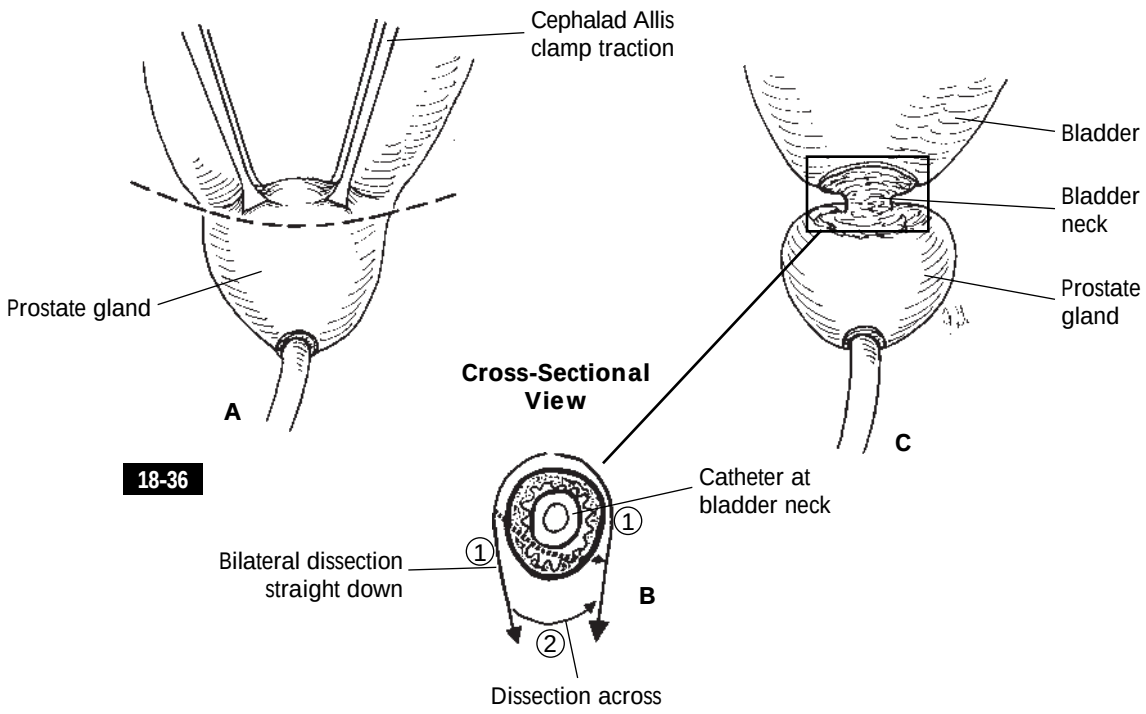

FIGS. 18-36 AND 18-37. Using Allis clamps to apply countertraction between the prostate gland and bladder, the surgeon isolates the anterior urethra (Fig. 18-36, **A,** and Fig. 18-37, **A**). If a bunching stitch has previously been placed to avoid venous backflow, it must first be removed.[8]

Using both blunt and sharp dissection, the surgeon now dissects straight down each side of the urethral margin instead of encircling the urethra immediately (*1* in Fig. 18-36, **B**). Invariably, the posterior bladder neck will be torn or lacerated if the surgeon attempts to dissect around the urethra prematurely (*dashed line* in Fig. 18-36, **B;** see Fig. 18-38, **C**).

Once certain that the bilateral dissection extends below the posterior bladder neck, the surgeon may use a right-angle clamp to gently encircle the urethra and work back upward (*2* in Fig. 18-36, **B**).

A groove is thus created between the bladder neck and the prostate gland (Fig. 18-36, **C,** and Fig. 18-37, **B** and **C**).

FIG. 18-38. Using umbilical tape around the bladder neck and removing the Allis clamp on the bladder side, the surgeon continues the distal urethral dissection by blunt dissection with the Kitners. A vein retractor is placed within the groove of the proximal prostate gland to help to retract it distally **(A).**

Finger palpation and "pinching" help to define a cuff of prostatic urethra free from the prostate gland. If a patient has a large median lobe, the surgeon will have difficulty in defining a plane between the posterior prostatic urethra and the median lobe.

The Foley catheter is removed and then the urethra is cut as distally as possible, leaving a 2 cm cuff attached to the bladder neck **(B).**

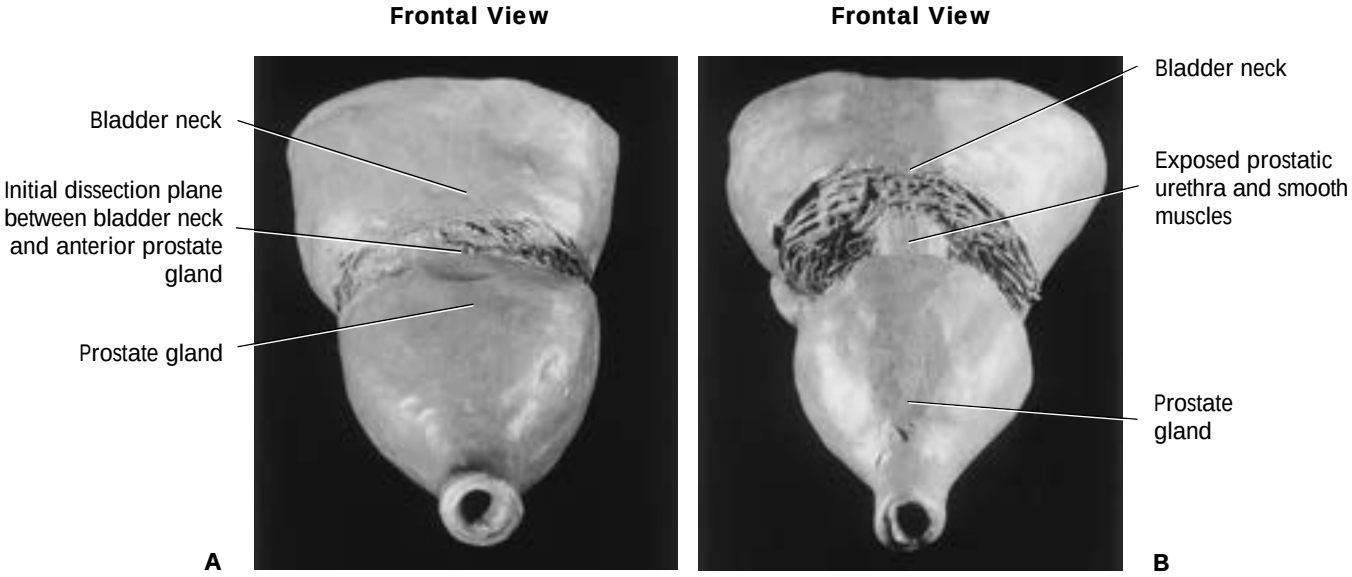

If the cuff were divided anteriorly with the catheter within and the catheter were retracted cephalad, there would be the potential for tearing this smooth muscle cuff **(C).**

For urethral reanastomosis, the epithelium is not everted but deep suture bites of the full-thickness bladder wall are taken to create the anastomosis **(D).** Anastomosing only the distal urethra to the cuff of the prostatic urethra is insufficient and the repair will tear out.

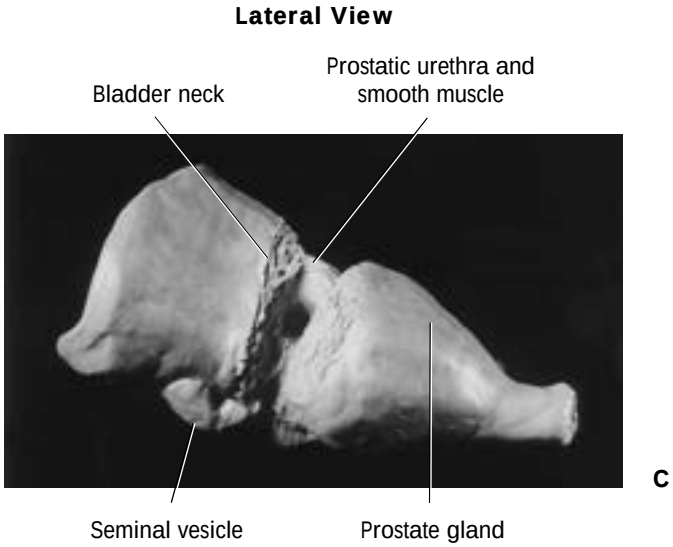

18-37

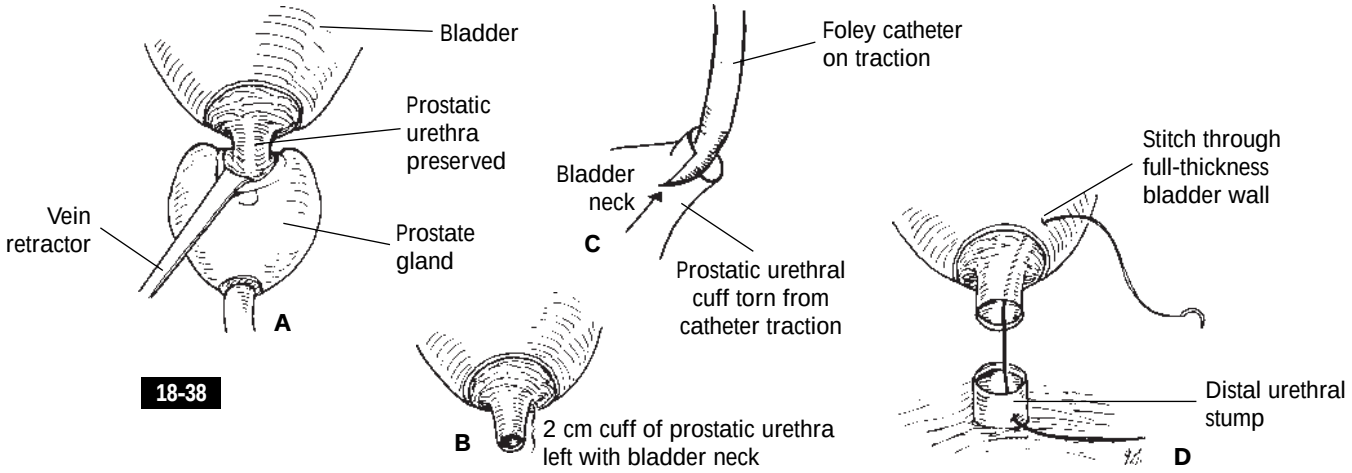

18-38

DISTAL URETHRAL–BLADDER NECK ANASTOMOSIS

FIG. 18-39. Whether using a Foley catheter (22 Fr with a 30 ml balloon filled with 5 ml) or a Greenwald sound to aid in urethral stitch placement, the surgeon places four to six stitches while the assistant uses a sponge stick to depress the rectum out of harm's way. Although the surgeon can take wide suture bites in the anterior urethra (sometimes including the levator ani muscle), more conservative suture bites should be placed in the posterior urethra to avoid the lateral neurovascular bundles.

We have found a No. 3 Mayo needle bent into a U configuration helpful in placing deep but not wide bites.

FIG. 18-40. With a threaded Mayo needle, the surgeon passes the four urethral sutures through the respective four positions in the bladder to complete the anastomosis.

FIG. 18-41. A Foley catheter attached to a stitch (0 Prolene) brought out through the bladder and the skin is a safety measure that prevents accidental catheter slippage.

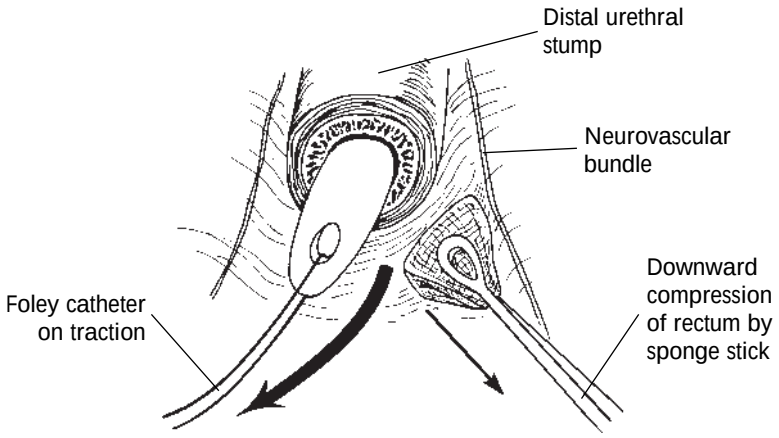

18-39

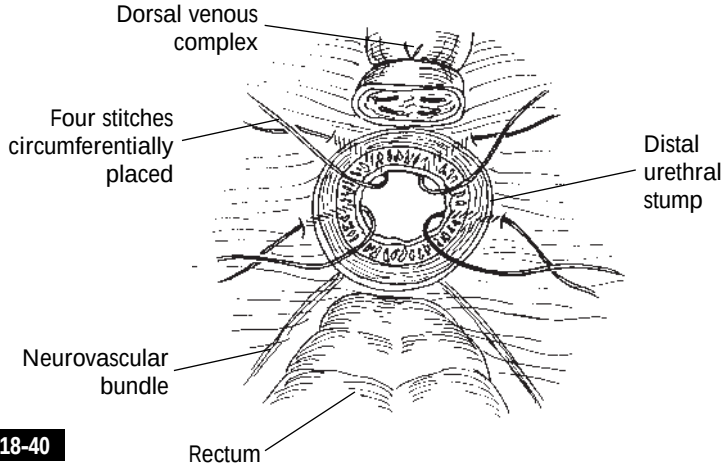

18-40

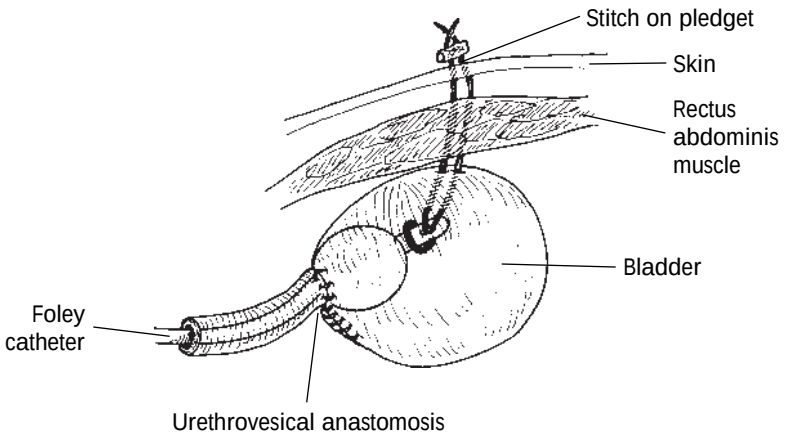

18-41

KEY POINTS

- A malleable blade retractor is positioned within the retroperitoneal pockets for pelvic lymphadenectomy, and the hypogastric artery is temporarily ligated with vessel loops.
- The bladder is retracted cephalad with a grooved blade retractor fixed to the Balfour or Bookwalter retractor, and downward compression is applied to the prostate gland with a sponge stick.
- The dorsal venous complex is ligated and divided.
- The urethra is isolated, avoiding the neurovascular bundles.
- The superficial fascia is divided with a nerve-sparing procedure or a wide excision is performed after urethral division.
- The rectourethralis muscle (striated urethral spincteric muscle) is divided.
- Denonvilliers' fascia is opened, freeing the seminal vesicles and vasa deferentia posteriorly.
- The prostatic pedicles are divided.
- Two alternatives exist for bladder neck dissection: a wide bladder neck dissection with a tennis racquet reconstruction or a bladder neck and partial prostatic urethral preservation.
- The prostate gland, seminal vesicles, and vasa deferentia are removed.
- Urethral–bladder neck anastomosis is performed.

POTENTIAL PROBLEMS

- *Rupture of hypogastric vein:* Perform suture ligation → ligate entire vessel
- *Excessive bleeding from dorsal venous complex:* Perform a figure-of-eight stitch on the dorsal venous complex → apply a Foley catheter tamponade (balloon filled with 40 ml of saline solution)
- *Rectal injury:* Perform two-layer primary repair of injury → perform colostomy for a severe laceration
- *Ureteral injury in bladder neck dissection:* Repair vesical tear and place stent in ureter if needed
- *Torn distal urethra from stitch placement:* Replace new stitch and include lateral levator ani muscle in the anterior two stitches

REFERENCES

1 Peters CA, Walsh PC: Blood transfusion and anesthetic practices in radical retropubic prostatectomy, *J Urol* 134:81, 1985.

2 Kaufman JJ, Katske FA: Simple technique to control venous bleeding during radical retropubic prostatectomy and cystectomy, *Urology* 20:309, 1982.

3 Holtgrewe HL, Yu GW, Jacobs GN: A modified surgical retractor blade for radical retropubic prostatectomy and retropubic surgery, *J Urol* 148:353, 1992.

4 Steiner MS: The puboprostatic ligament and the male urethral suspensory mechanism: an anatomic study, *Urology* 44:530, 1994.

5 Yu GW, Melograna FS, Miller HC: Surgical modifications for ligation of deep dorsal vein complex from the retropubic space, *Urology* 40:545, 1992.

6 Lynch DF, Schellhammer PF: Techniques for management of the dorsal venous complex in radical retropubic prostatectomy, *Urol Clin North Am* 2(2):81-94, 1994.

7 Walsh PC: Radical retropubic prostatectomy: an anatomical approach. In Walsh PC et al, editors: *Campbell's urology,* ed 6, Philadelphia, 1992, WB Saunders.

8 Myers RP: Improving the exposure of the prostate in radical retropubic prostatectomy: Longitudinal bunching of the deep venous plexus, *J Urol* 142:1282, 1989.

9 Stamey TA et al: Positive margins at radical prostatectomy: importance of the apical dissection, *J Urol* 143:1166, 1990.

10 Lippert M: Personal communication, June 1995.

11 Epstein JI, Pizov G, Walsh PC: Correlation of pathologic findings with progression following radical prostatectomy, *Cancer* 71:3582, 1993.

12 Gomez CA et al: Bladder neck preservation and its impact on positive surgical margins during radical prostatectomy, *Urology* 42:689, 1993.

13 Malizia AA et al: Modified radical retropubic prostatectomy: double continence technique [abstract]. Presented at the annual AUA meeting. Dallas: May 10, 1989.

14 Myers RP: Male urethral sphincteric anatomy and radical prostatectomy, *Urol Clin North Am* 18(2):211, 1991.

15 Sesterhenn I, Mostofi K (Armed Forces Institute of Pathology): Personal communication, December 1995.

16 Epstein J (Johns Hopkins Hospital, Department of Pathology): Personal communication, December 1995.

17 Yu GW et al: [to be submitted for publication].

SUGGESTED READINGS

Goldberg M et al: Effect of patient positioning on urethral mobility: implications for radical pelvic surgery, *J Urol* 146:1252, 1991.

Myers RP: Anatomical variation of the superficial preprostatic veins with respect to radical retropubic prostatectomy, *J Urol* 145:992, 1991.

RADICAL PERINEAL PROSTATECTOMY

19

One advantage of radical perineal prostatectomy is the associated minimal blood loss. Patients with medical problems who cannot tolerate sudden changes in hemodynamics, patients who are obese, and patients who have had previous surgery in the lower abdomen and pelvis (e.g., penile prosthesis placement) are excellent candidates for this operation. In addition, those patients with low probability of lymph node involvement by preoperative evaluation or negative laparoscopic lymph node dissections are good candidates for surgery in this untampered area of the perineum.

PREPARATION

If the surgeon believes the procedure may be difficult, a full bowel preparation the night before with a neomycin enema the morning of the surgery is a safe precautionary measure.

FIG. 19-1. The perineum must be parallel to the operating room floor. The patient is placed in an extreme lithotomy position with the buttocks extended 6 inches past the end of the table. A sandbag is placed under the sacrum, shoulder braces are positioned to prevent cephalad movements, and Allen stirrups are used to maintain this exaggerated position.

The ischial tuberosity should be draped into the operative field.

EXPOSURE

FIGS. 19-2 AND 19-3. Once the Lowsley retractor is in the bladder and its wings opened, the assistant must manipulate the retractor so that the prostate gland is pushed toward the perineal surface. This maneuver requires a downward and forward motion with the Lowsley retractor so that the prostate gland will protrude toward the wound.

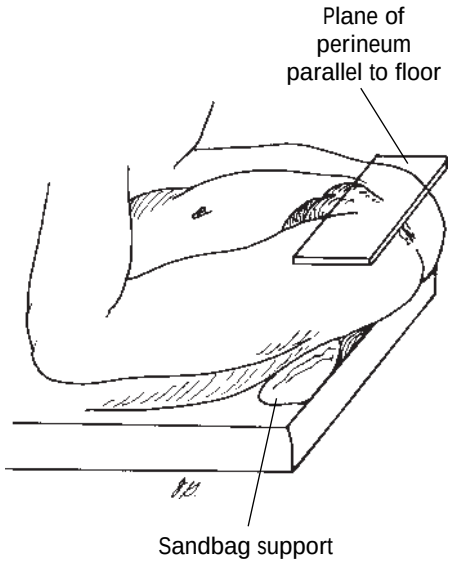

19-1

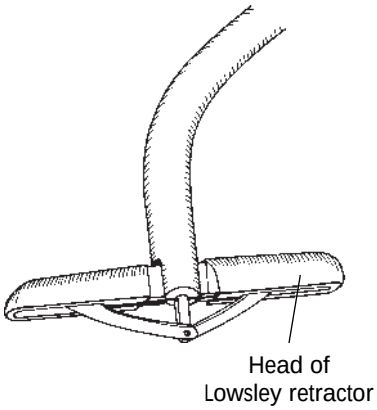

19-2

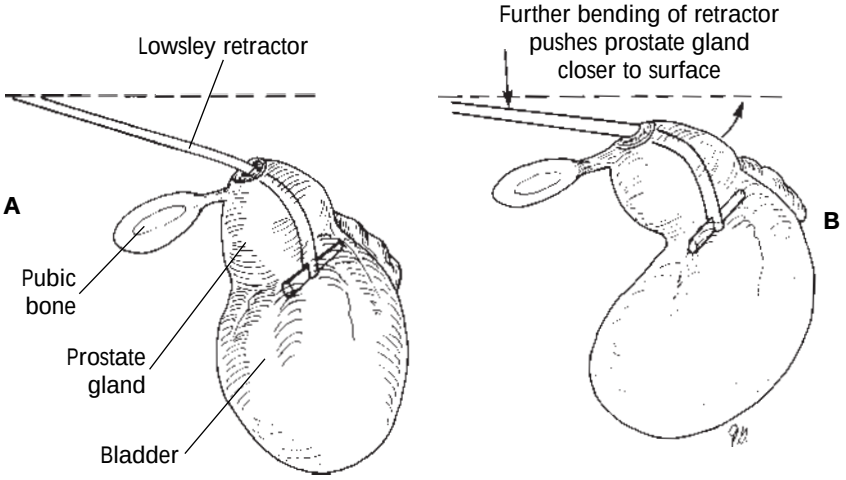

19-3

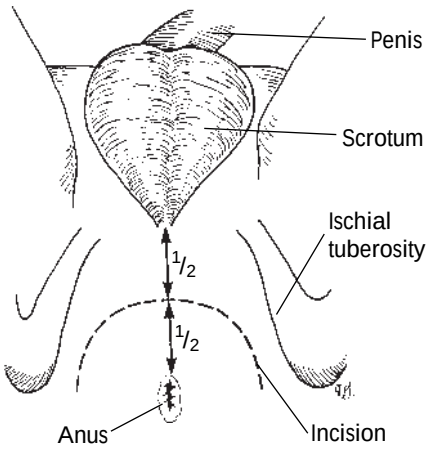

19-4

FIG. 19-4. The inverted-U incision is made halfway between the scrotum and anus and medial to each ischial tuberosity. An incision over the tuberosity would cause discomfort for the patient in a sitting position after surgery.

FIG. 19-5. With blunt dissection through the subcutaneous fat laterally, the surgeon encircles the dense midline tissues and divides the central tendon.

FIG. 19-6. *The most important and difficult part of this operation is the takedown of the rectourethralis muscle and mobilization of the rectum off the prostate gland.*

After using Kelly clamps to spread the fatty tissues deeper directly into the ischiorectal fossa from the more lateral approach, the surgeon inserts two index fingers to palpate for the prostate gland. The assistant must push the Lowsley retractor down and forward so that the posterior aspect of the prostate gland protrudes into the wound.

FIG. 19-7. Through the fatty tissues, the surgeon can easily feel the posterior surface of the prostate gland, the Lowsley retractor near the prostatic apex, and the more proximal portion of the prostatic base.

FIG. 19-8. Selecting a point in the lateral midprostatic area, the surgeon now performs gentle blunt dissection, with the index fingers coming toward the midline from

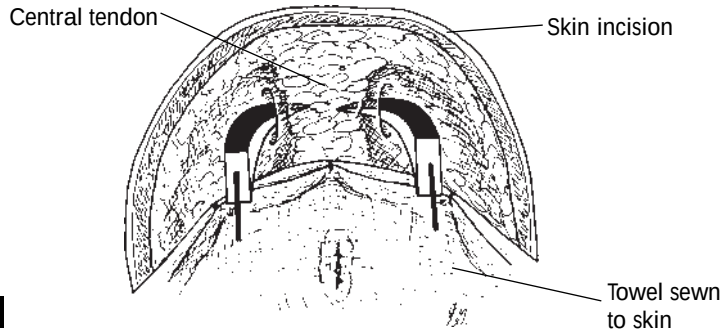

19-5

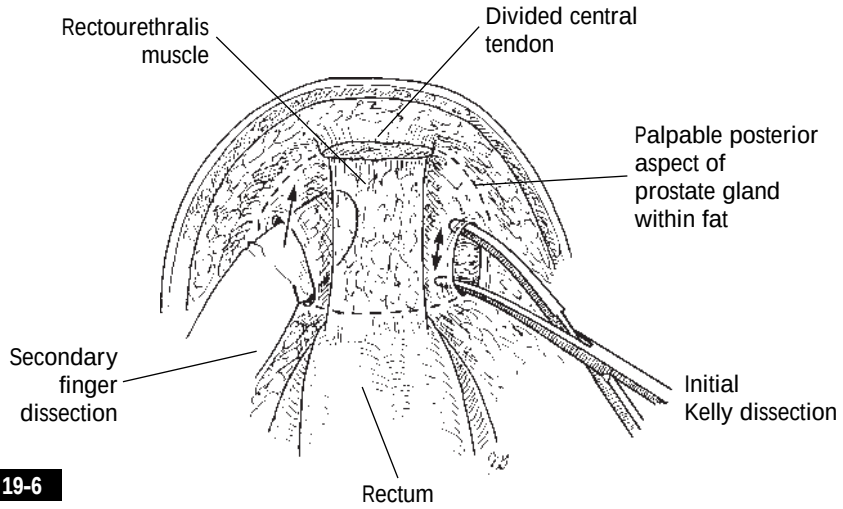

19-6

Oblique View

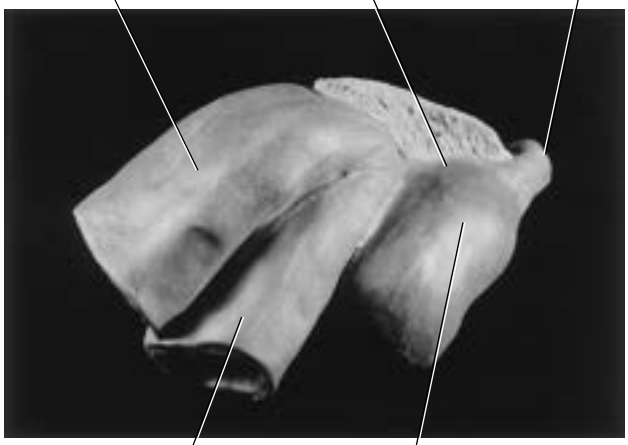

19-7

Anterior Posterior View

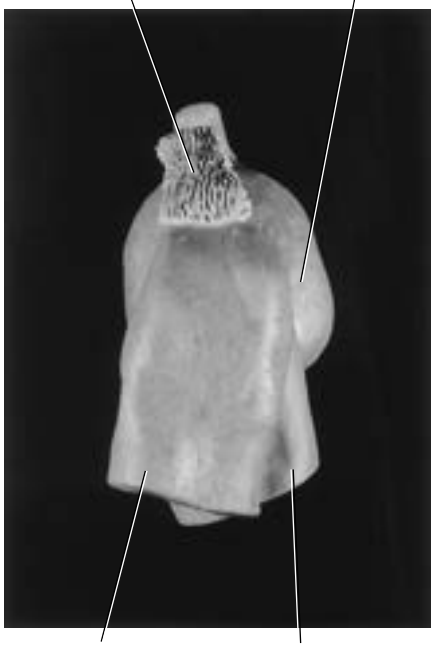

a lateral position. With this gentle blunt dissection, *always* staying on the surface of the prostate gland, the surgeon uses the index fingers to lift the fibrous tissues overlying the posterior aspect of the prostate gland, maneuvering the fingers toward the midline until they meet. The rectourethralis muscle is now free from the prostate gland.

FIG. 19-9. The rectourethralis muscle is still attached to the rectum below. The surgeon places the left index finger under the muscle and uses the knife carefully to divide the muscle. The posterior surface of the prostate gland is now safely exposed.

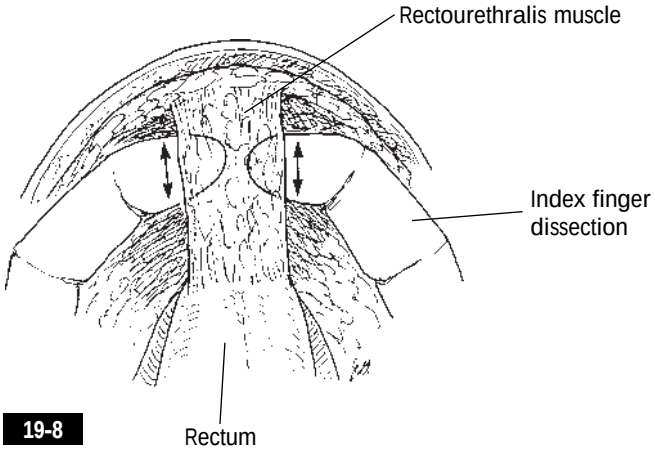

19-8

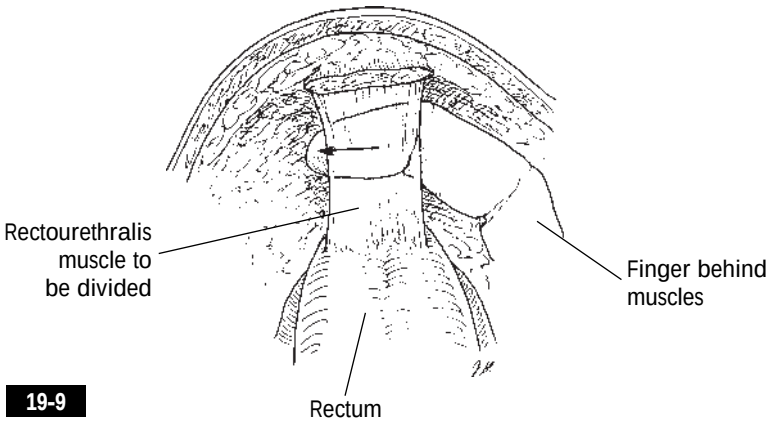

19-9

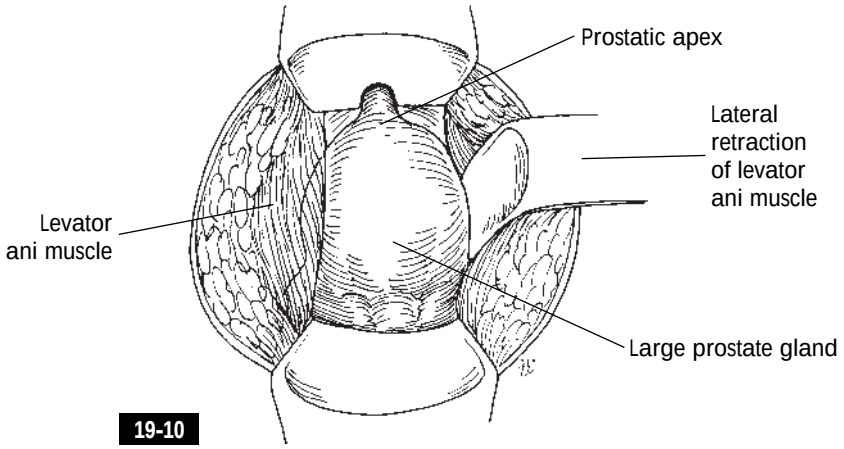

19-10

FIG. 19-10. The rectum is thus mobilized posteriorly and covered with gauze. A posterior flat retractor is placed over it and retracted inferiorly for the rest of the surgery.

If the prostate gland is large, it may be necessary at this point to incise the medial edges of the levator ani muscles and retract them laterally to gain sufficient exposure for the next steps.

DENONVILLIERS' FASCIA AND THE "PEARLY GATES"

FIG. 19-11. By making a vertical incision over the posterior leaf of Denonvilliers' fascia *(1)* rather than the classical horizontal one, the surgeon will not injure the neurovascular bundles. This vertical incision must be carried further toward the prostatic base *(2)* because this potential space between the two leaves of Denonvilliers' fascia may lie more proximally than expected. It is not uncommon to find the leaves of Denonvilliers' fascia fused as the dissection approaches the prostatic apex *(3)*. The "pearly gates" refer to the inner surface of the space between the leaves and are more often encountered near the prostatic base. They classically signify safety, but occasionally the prostate surface is clearly exposed without any "pearly gates" really being recognized.

Once the posterior surface of the prostate gland is clearly seen, the surgeon can now isolate the prostatic apex and encircle the urethra *(4)*. The proximal dissection at this point should extend into the region of the seminal vesicles *(2)* to make later dissection of these structures much easier.

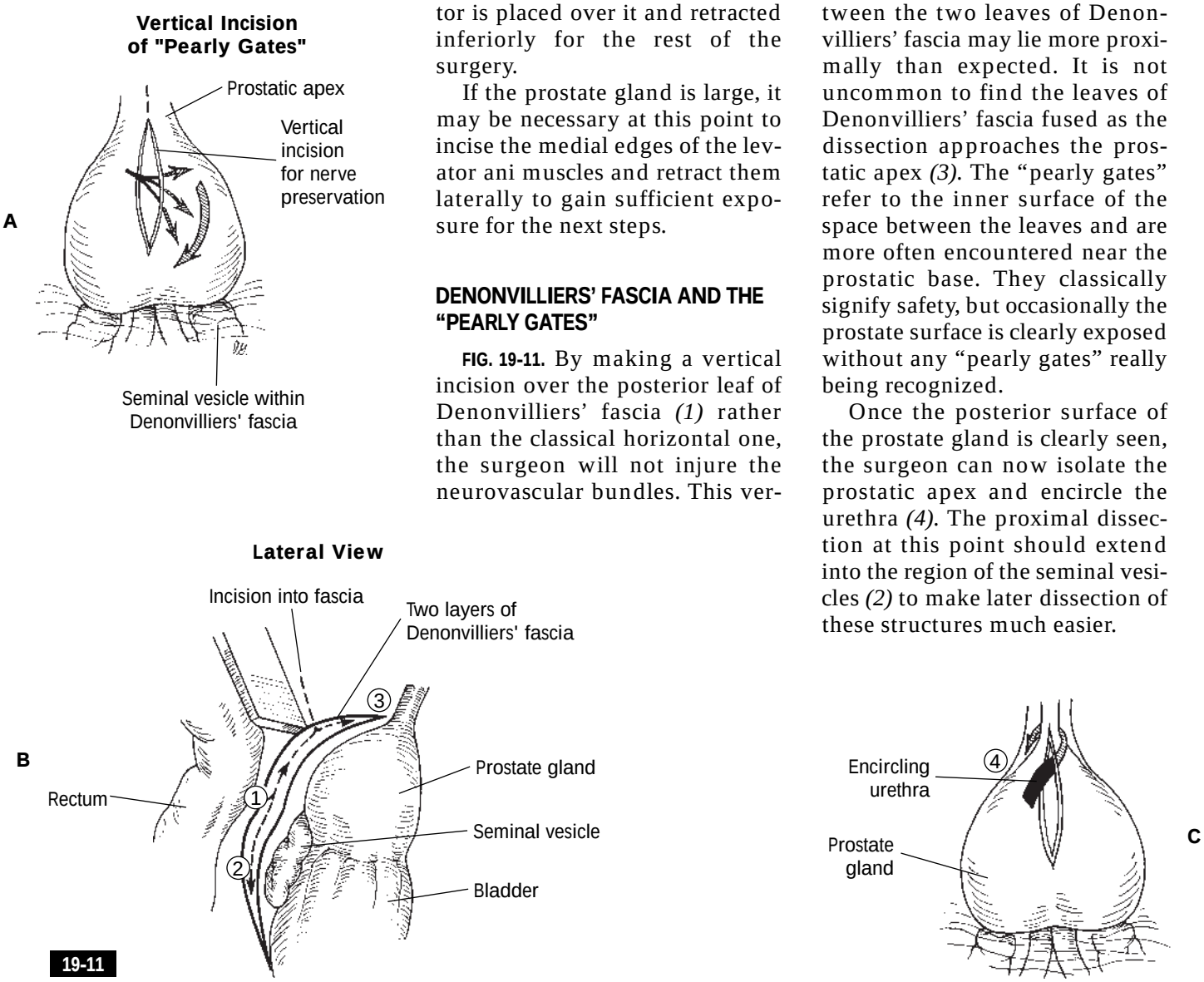

19-11

URETHRAL AND ANTERIOR PROSTATE DISSECTION

FIGS. 19-12 AND 19-13. The urethra is freed circumferentially distal to the prostatic apex and opened transversely to expose the shaft of the Lowsley retractor.

The Lowsley retractor is replaced by the Young tractor through this urethral opening. The urethra is now completely transected.

FIG. 19-14. With the left hand on the Young tractor, the surgeon uses the right index finger to establish a plane between the anterior surface of the prostate gland and its overlying fascia. This is quickly and easily done by finger dissection. Since this dissection is performed between the prostate gland and the anterior fascial layers, the dorsal venous complex is never encountered and therefore bleeding is minimal.

This anterior dissection is continued to the prostate gland–bladder junction and around to the prostatic pedicles laterally.

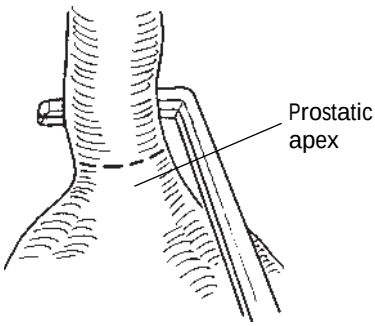

19-12

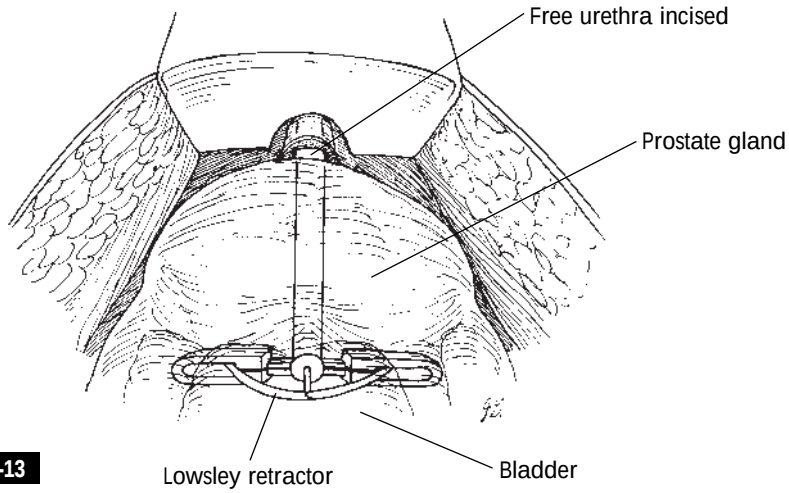

19-13

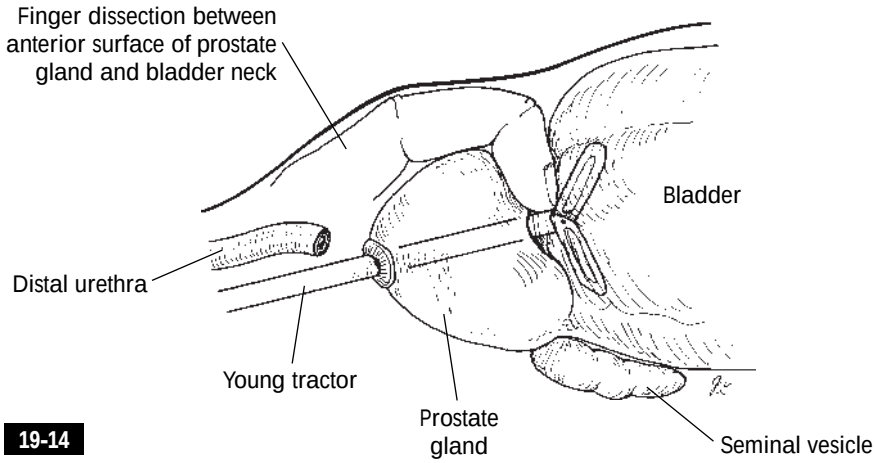

19-14

BLADDER NECK AND SEMINAL VESICLE DISSECTION

The surgeon now feels the Young tractor at the bladder neck junction and uses mostly blunt dissection to establish a plane between the prostate gland and the bladder. It is remarkably easy to winnow this tissue down to just the bladder neck and pedicles.

FIG. 19-15. With further finger dissection drawing the prostate gland distally, the surgeon should make every attempt to preserve a cuff of proximal prostatic urethra circumferentially measuring 1 to 2 cm from the bladder neck. We have found this maneuver offers early postoperative recovery of continence with both this operation and radical retropubic prostatectomy.[1,2] This maneuver also protects against transection occurring too close to the trigone, with attendant ureteral damage. Only rarely is the bladder neck involved with the tumor; in those cases more classical transection can be done. The surgeon still must be careful to cut the bladder neck or proximal prostatic urethra straight back and avoid any tendency to angle the cut cephalad.

FIG. 19-16. The Young tractor is removed and the proximal prostatic urethral cuff is transected with right-angle scissors.

FIGS. 19-17 AND 19-18. A urethral catheter is placed through the prostate gland for traction. A Foley catheter may be placed in the bladder with the balloon inflated to 30 to 50 ml for gentle retraction cephalad.

The only structures holding the prostate gland now are the vasa deferentia, seminal vesicles, and lateral prostatic pedicles. These structures are ligated and divided by either the anterior or posterior approach. The artery of each seminal vesicle is located almost at the tip of the seminal vesicle; it is small but worth controlling. Cancerous involvement of the seminal vesicles is almost always only in the intraprostatic portion of the seminal vesicles, so leaving a small cephalad fragment of these friable structures is not a crime.

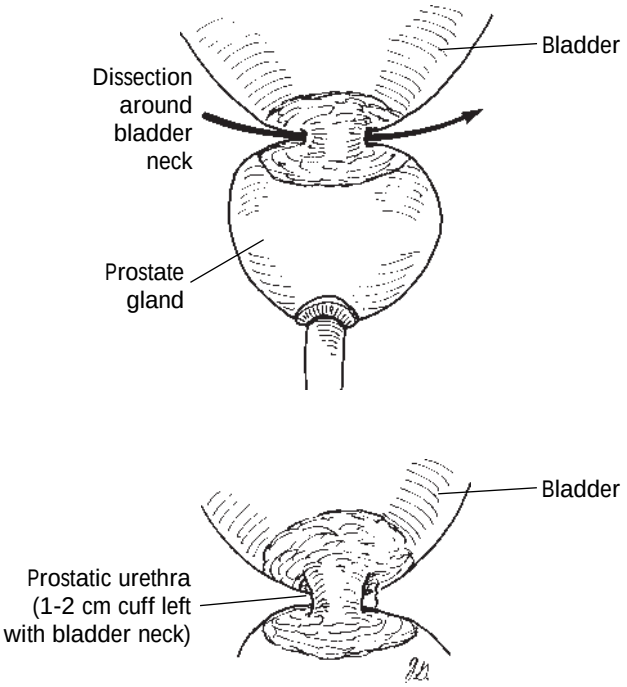

19-15

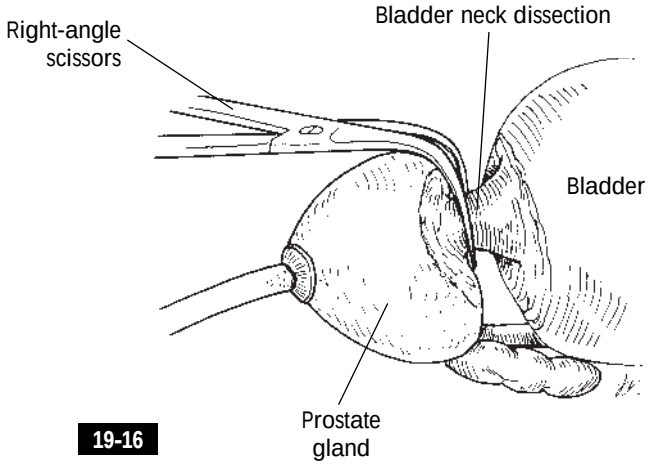

19-16

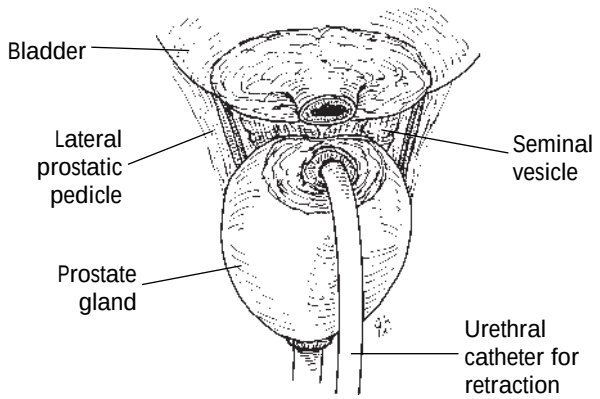

19-17

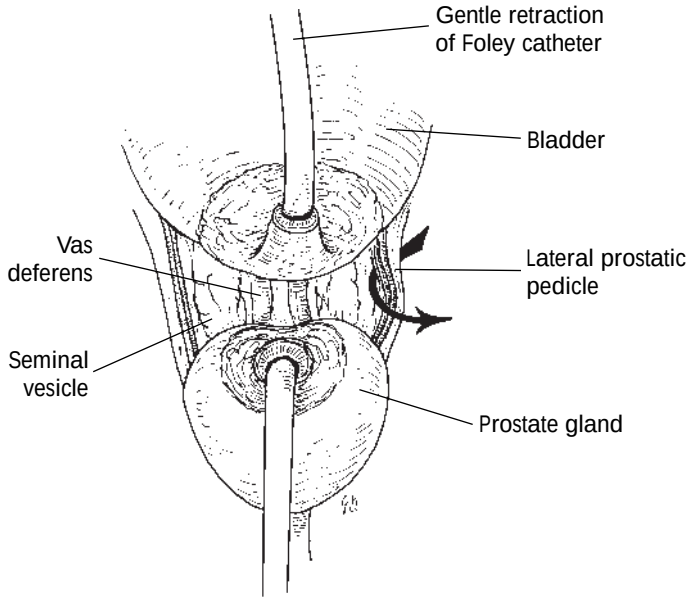

19-18

Vesicourethral Anastomosis

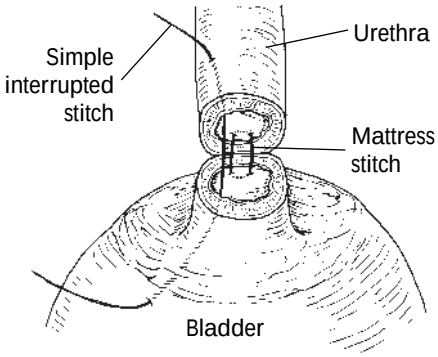

19-19

URETHRAL–BLADDER NECK RECONSTRUCTION

In contrast to the retropubic approach, the easiest part of this operation is the urethral–bladder neck anastomosis. Sometimes the structures of the bladder neck and distal urethra are so close that it almost appears as if no stitches at all are needed. They are, though.

FIG. 19-19. A good, secure horizontal mattress stitch (2-0 Vicryl) is placed in the anterior 12-o'clock position before the Foley catheter (22 Fr with 30 ml balloon) is inserted through the distal urethra and into the bladder.

The remaining three simple interrupted stitches are placed at the 3-, 6-, and 9-o'clock positions. The trigone and ureters are usually well back from the anastomosis, but it does not hurt to check once again. There is no need for bladder neck "tailoring."

A drain is placed, and the levator ani muscle, central tendon, subcutaneous tissues, and skin are reapproximated with simple interrupted stitches. A mesh panty holds a simple dressing in place and the Foley catheter is placed for constant drainage.

KEY POINTS

- The patient is positioned so that the perineum is parallel to the operating room floor.
- The Lowsley retractor is manipulated by the assistant to push the prostate gland toward the perineum.
- An incision is made halfway between the scrotum and the anus and medial to the ischial tuberosity.
- The central tendon is divided.
- The rectourethralis muscle is mobilized by the surgeon with two index fingers.
- The levator ani muscle must be mobilized laterally if the prostate gland is large.
- A vertical incision is made in the posterior leaf of Denonvilliers' fascia to expose the "pearly gates" of the anterior leaf. This vertical incision preserves the neurovascular bundles for a nerve-sparing procedure.
- Dissection posteriorly is performed distally around the urethra and proximally up over the seminal vesicles.
- The urethra is incised against the Lowsley retractor and then this retractor is removed.
- The Young tractor is depressed, allowing quick and simple anterior prostate dissection with a finger, avoiding the dorsal venous complex entirely.
- The plane between the prostate gland and the bladder is easily bluntly developed using the shaft of the Young tractor as a guide.
- The bladder neck is dissected, preserving a 2 cm cuff of the prostatic urethra.
- After the Young tractor is removed, the bladder neck and/or cuff are divided.
- A urethral catheter is placed through the prostate gland for traction.
- The vasa deferentia, seminal vesicles, and lateral prostatic pedicles are ligated and divided.
- A horizontal mattress stitch is placed at the anterior 12-o'clock position and then three simple interrupted stitches are placed to complete the urethral–bladder neck anastomosis.

POTENTIAL PROBLEMS

- *Poor exposure of perineum:* Check for proper positioning → manipulate the Lowsley retractor
- *Rectal laceration:* Perform a two-layer closure → interpose the anal sphincteric muscle when finishing the surgery → ensure that a watertight closure of the bladder neck has been obtained → cover with systemic antibiotics for 7 days
- *Large prostate gland:* Mobilize the levator ani muscle laterally
- *Unable to find space between two leaves of Denonvilliers' fascia:* Extend vertical incision more proximally and expose prostate surface
- *Penetration of dorsal venous complex during anterior prostate dissection:* Apply manual pressure over the complex → resume dissection in the correct plane
- *Bleeding from lateral prostatic pedicles:* Visualize the pedicles and apply suture ligatures → pack the area for a tamponade effect
- *Unanticipated extension of tumor into bladder neck:* Resect the tumor if at all possible and tailor the bladder neck
- *Bladder neck transection is too close to trigone:* Tailor bladder neck by closing it posteriorly so that anastomosis is made to the anterior bladder neck opening

REFERENCES

1 Gomez CA et al: Bladder neck preservation and its impact on positive surgical margins during radical prostatectomy, *Urology* 42(6):689, 1993.

2 Malizia AA et al: Modified radical retropubic prostatectomy: double continence technique [abstract]. Presented at the Annual AUA meeting. Dallas: May 10, 1989.

SUGGESTED READINGS

Frazier HA, Robertson JE, Paulson DF: Radical prostatectomy: the pros and cons of the perineal versus retropubic approach, *J Urol* 147:888, 1992.

Paulson DF: Complications of perineal prostatectomy. In Smith RB, Ehrlich RM, editors: *Complications of urologic surgery,* Philadelphia, 1990, WB Saunders, pp 395-405.

Resnick MI: Radical perineal prostatectomy redux, *Contemp Urol* 3(12):44, 1991.

Tobin CE, Benjamin JA: Anatomical and surgical restudy of Denonvilliers's fascia, *Surg Gynecol Obstet* 80:373, 1945.

Weldon VE, Tavel FR: Potency-sparing radical perineal prostatectomy: anatomy, surgical technique and initial results, *J Urol* 140:559, 1988.

SUPRAPUBIC PROSTATECTOMY

20

The most difficult part of an open prostatectomy, whether by a suprapubic or retropubic approach, is the control of bleeding after the enucleation of the prostate gland.

CONTROL OF BLEEDING BEFORE PROSTATE GLAND ENUCLEATION

With precautionary maneuvers such as (1) temporary hypogastric artery ligation, (2) ligation of the deep dorsal venous complex, and (3) stitch ligation of the prostatic pedicles before the actual procedure, we have had good control of bleeding after the prostate gland has been enucleated.

Temporary Hypogastric Artery Ligation

Although temporary ligation of the hypogastric artery will not prevent bleeding after enucleation of the prostate gland, the maneuver will lessen the bleeding so that the surgeon has an acceptable field of visualization.

FIG. 20-1. As in radical retropubic prostatectomy (see p. 170), retroperitoneal pockets are created first. The malleable blade is used to retract these pockets, and the hypogastric artery is isolated.

Rather than using bulldog clamps, we prefer to use vessel loops looped twice around the vessel and then tied. These vessel loops are easily removed after the main steps of the operation have been completed.

Ligation of Dorsal Venous Complex

Although ligation of the dorsal venous complex has been cited as providing improved hemostasis for retropubic prostatectomy for benign disease,[1] we have found this maneuver useful for the suprapubic approach as well.

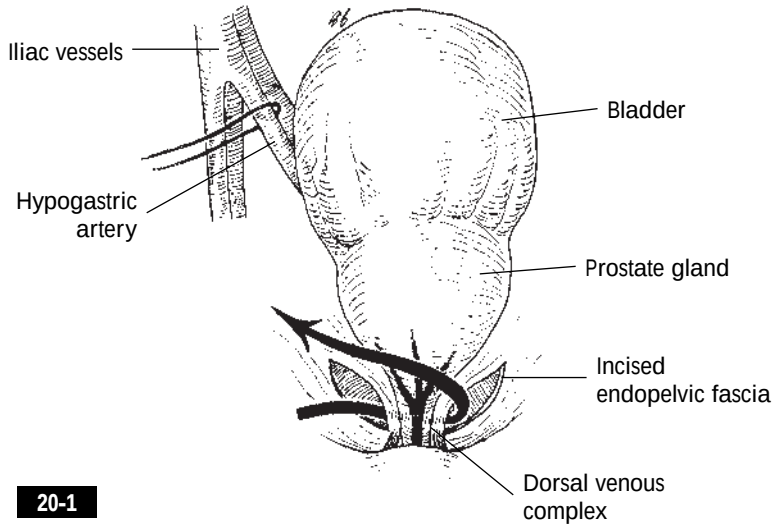

20-1

As for radical retropubic prostatectomy (see p. 172), the surgeon first isolates the deep dorsal venous complex (see Fig. 20-1).

FIG. 20-2. After opening the endopelvic fascia bilaterally, the surgeon does *not* divide the puboprostatic ligaments as is done in radical prostatectomy.

FIG. 20-3. The surgeon establishes a plane between the deep dorsal venous complex and the urethra and then passes a suture (0 Vicryl) around the complex and the puboprostatic ligaments as one unit.[2]

Two ties are usually sufficient for good hemostasis.

Ligation of Prostatic Pedicles

FIGS. 20-4, 20-5, AND 20-6. The prostatic pedicles are located at the inferior junction between the bladder and the prostate gland at the 5- and 7-o'clock positions.

The seminal vesicles are medial and posterior to these pedicles, whereas the rectum is posterior to the seminal vesicles.

After palpating and visualizing the vesicoprostatic junction, the surgeon places a figure-of-eight stitch (0 absorbable) at this junction almost parallel to the rectum.[3-5]

Finger-Pinching of Dorsal Venous Complex

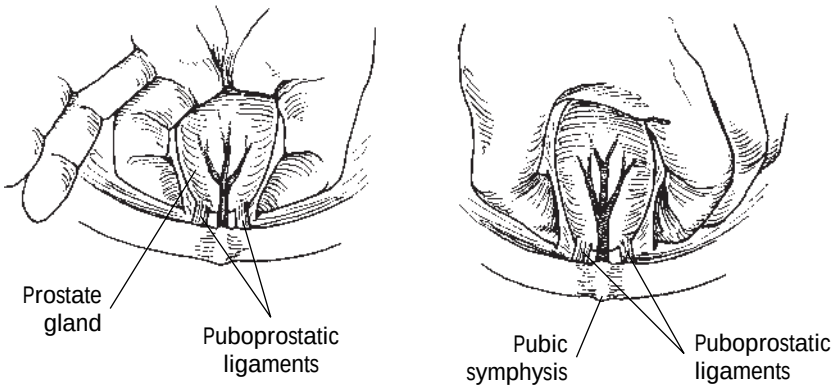

20-2

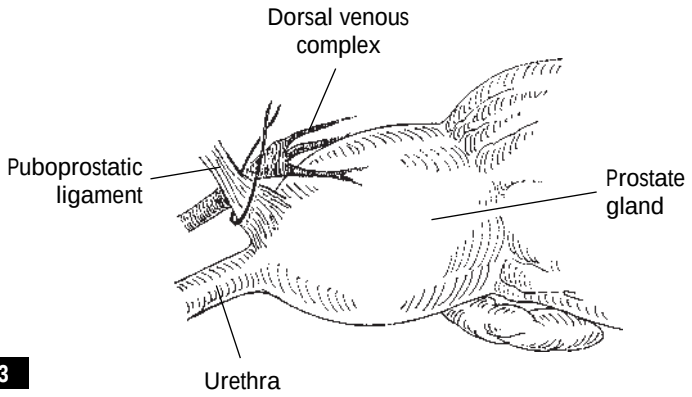

20-3

Lateral View

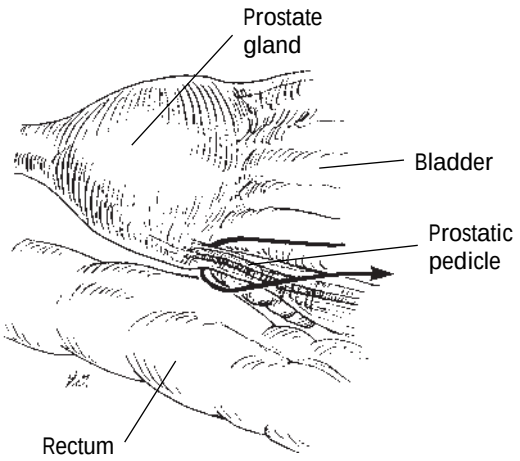

20-4

Oblique View

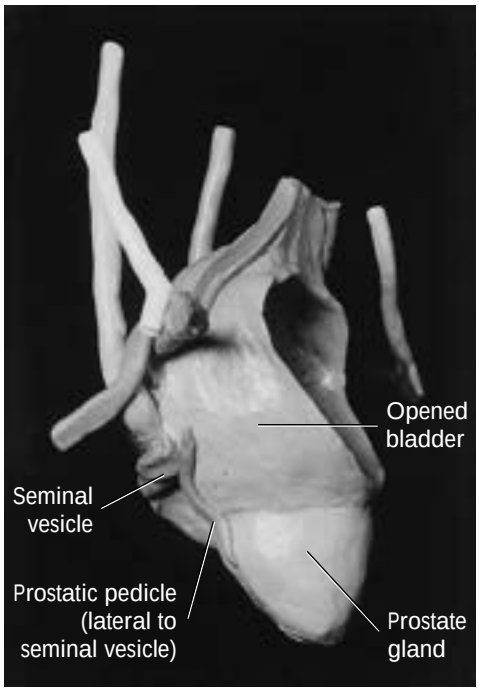

20-5

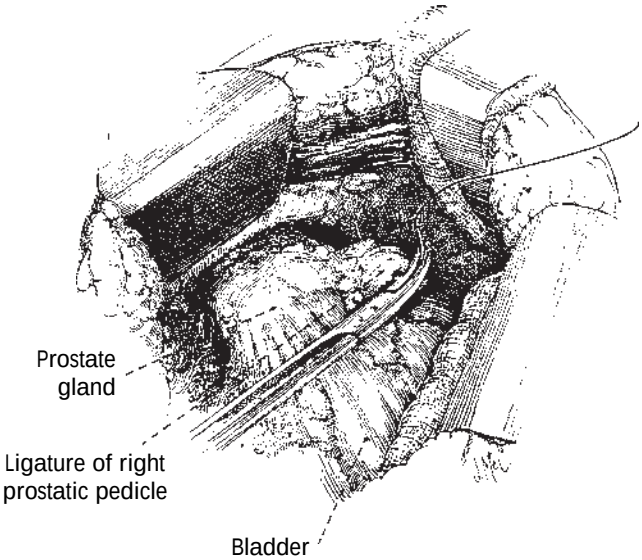

From Bensimon H: *Urologic surgery,* New York, 1991, McGraw-Hill.

20-6

EXPOSURE OF BLADDER AND PROSTATE GLAND ENUCLEATION

Rather than immediately enucleating the prostate gland after the bladder is opened, we prefer first to obtain the best exposure of the bladder and to define the most proximal dissection, thus protecting the ureters. This approach will also facilitate the placement of hemostatic stitches once the prostate gland has been removed.

FIG. 20-7. The placement of four or five sponges within the bladder with a malleable blade retracted cephalad and fixed to the Balfour retractor will provide a good field for the initial maneuvers **(A).**

The ureteral orifices are identified, and a feeding tube or stent is placed within if needed **(B).**

A traction stitch (0 Prolene) is placed into the median lobe of the prostate gland with multiple bites for better maneuverability **(C).** When the traction stitch is retracted distally, the space between the ureters and the median lobe is better identified.

FIG. 20-8. The urothelium above, the median lobe, and the prostatic capsule are incised via electrocautery. With scissors the surgeon can now establish a clean plane of proximal bladder dissection as well as define the base of the prostate gland within the prostatic capsule.

FIG. 20-9. At this point the surgeon has the option of continuing the dissection with the index finger to either go around the base of the prostate gland toward the prostatic apex *(1)* or break the anterior commissure, start the dissection at the prostatic apex, and work toward the base *(2)*.

We prefer to work from the base toward the prostatic apex while encircling the urethra and cutting the urethra flush against the apical tissues.

When enucleating the prostate gland, the surgeon should apply finger pressure against the prostate surface and not on the capsular side to avoid false passage and capsular lacerations.

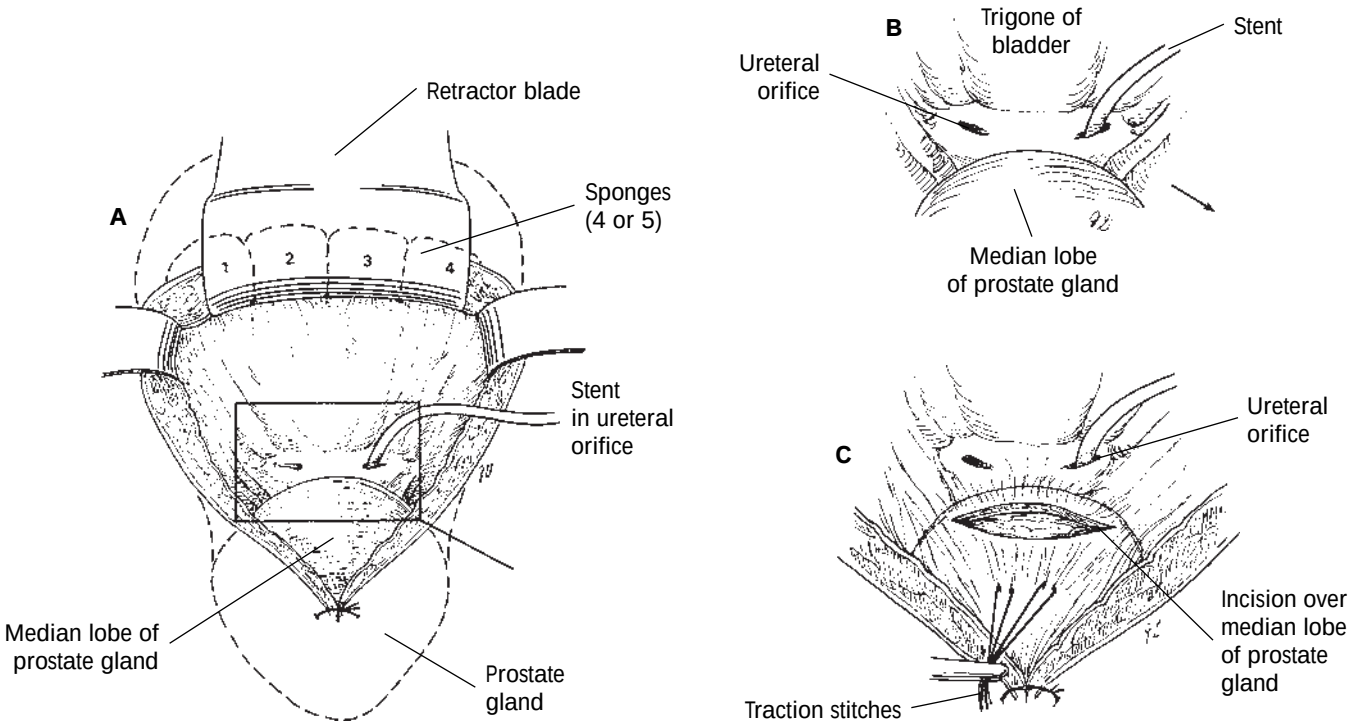

20-7

Sharp Dissection of Median Lobe of Prostate Gland

Frontal View

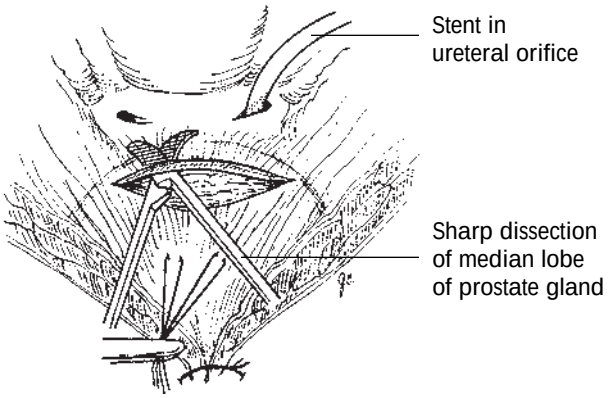

Lateral View

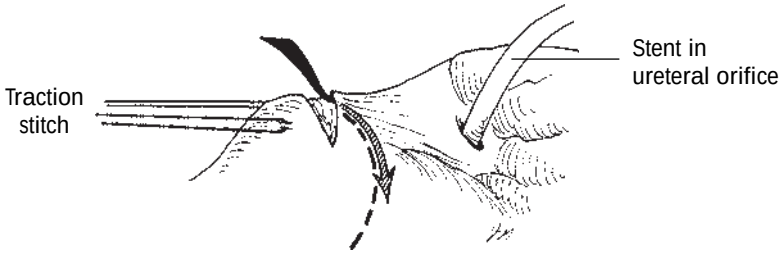

20-8

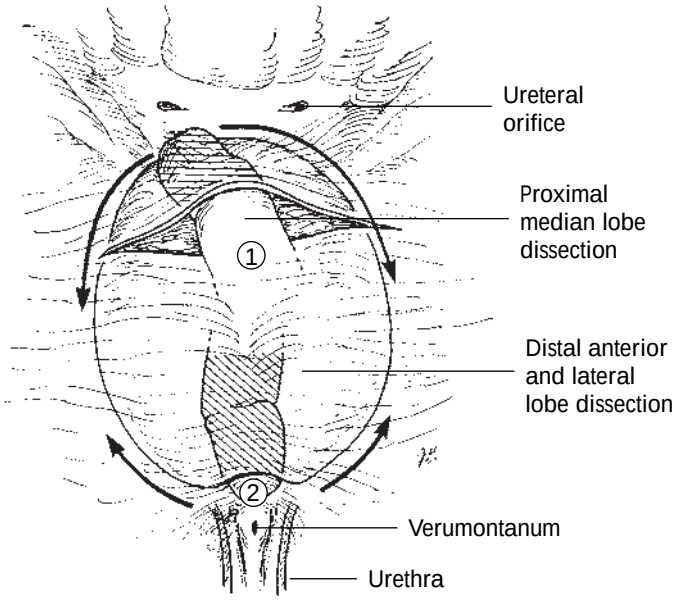

20-9

CONTROL OF BLEEDING AFTER PROSTATE GLAND ENUCLEATION

The *most important maneuver* in suprapubic open prostatectomy is the control of bleeding within the prostatic fossa after enucleation.

FIG. 20-10. By placing a long nasal speculum or a narrow Deaver retractor into the prostatic fossa, the surgeon can better visualize the region for hemostatic stitch placement.

FIGS. 20-11 AND 20-12. Allis clamps applied at the 5- and 7-o'clock positions of the proximal prostatic fossa and the bladder edges should incorporate at least a 1 to 2 cm depth of the tissues. While applying cephalad traction with clamps, the surgeon can place a running stitch into the 5- and 7-o'clock positions (0 absorbable or 2-0 Vicryl).

Before placing these stitches, the surgeon should have a good sense of the location of the prostatic pedicles, seminal vesicles, and rectum.

Fearful of injuring the rectum, surgeons generally tend to take excessively shallow suture bites, which have no effect on hemostasis. With experience, the surgeon learns the proper depth of each bite of the stitch.

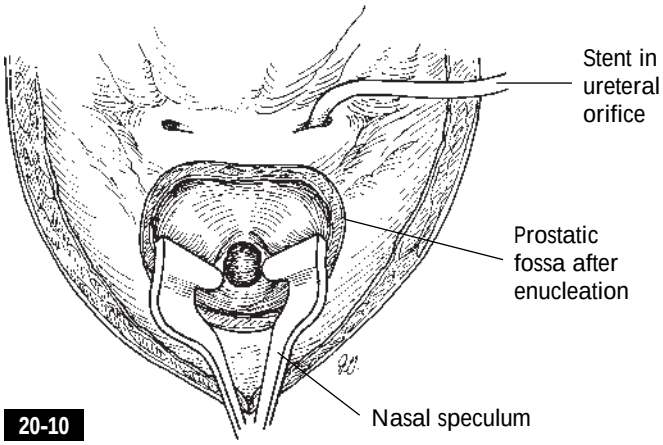

20-10

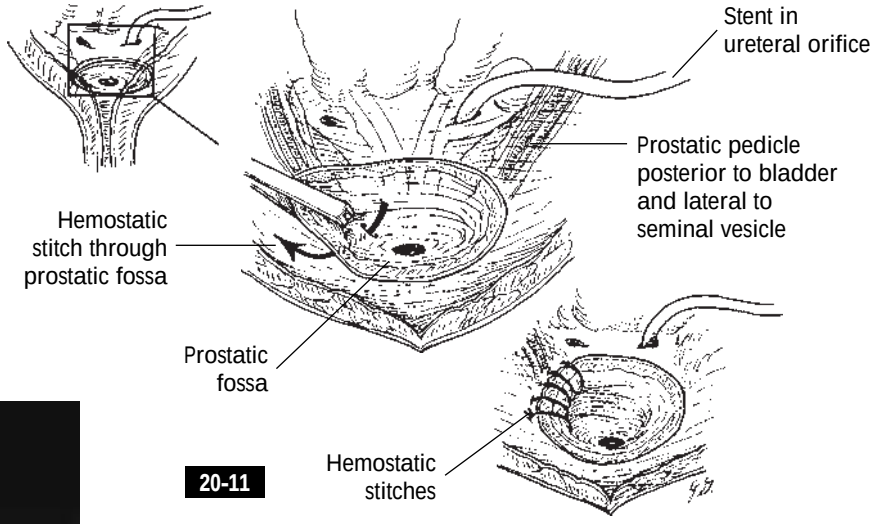

20-11

Frontal View (with Section of Bladder Removed)

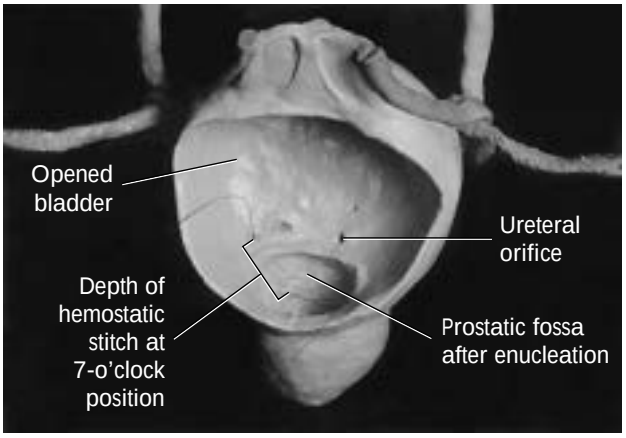

20-12

Alternately, if necessary, the surgeon can actually palpate and check for the appropriate depth of stitch placement by palpating in the rectum with (1) a finger, (2) an inflated rectal catheter, or (3) a sponge stick.

Malament Stitch

The purpose of the Malament stitch is to compartmentalize the prostatic fossa from the bladder and thereby compress the bleeding surfaces of the fossa.[6,7]

FIG. 20-13. Using a 1-0 nylon or Prolene stitch, the surgeon can use a pursestring or a running stitch 2 cm apart to encircle the bladder neck **(A).** The stitch should be easily movable and, as it comes through the prostatic capsule at the 12-o'clock position, it should be crossed and brought out to the skin with some tension **(B).**

This stitch should be under tension to create a true tamponade effect, and it should be removed within 5 to 10 hours postoperatively. If this stitch is left in for a prolonged period (3 to 5 days), it can lead to a bladder neck contracture.

The Foley catheter is best left in for a 10- to 14-day period to avoid cross adhesions at the bladder neck, whereas the suprapubic tube can be removed as soon as the bleeding has subsided and the large clot has been removed.

Plication Stitch of Prostatic Fossa

FIG. 20-14. The plication stitch essentially obliterates the prostatic fossa while compressing potential bleeding sites.[8] Large bites with absorbable sutures (e.g., 0 absorbable) is the best choice.

The Foley catheter (24 Fr) with the balloon inflated to 30 ml can be placed under traction to compress the prostatic fossa whether or not the surgeon uses hemostatic stitches.

Malament Stitch

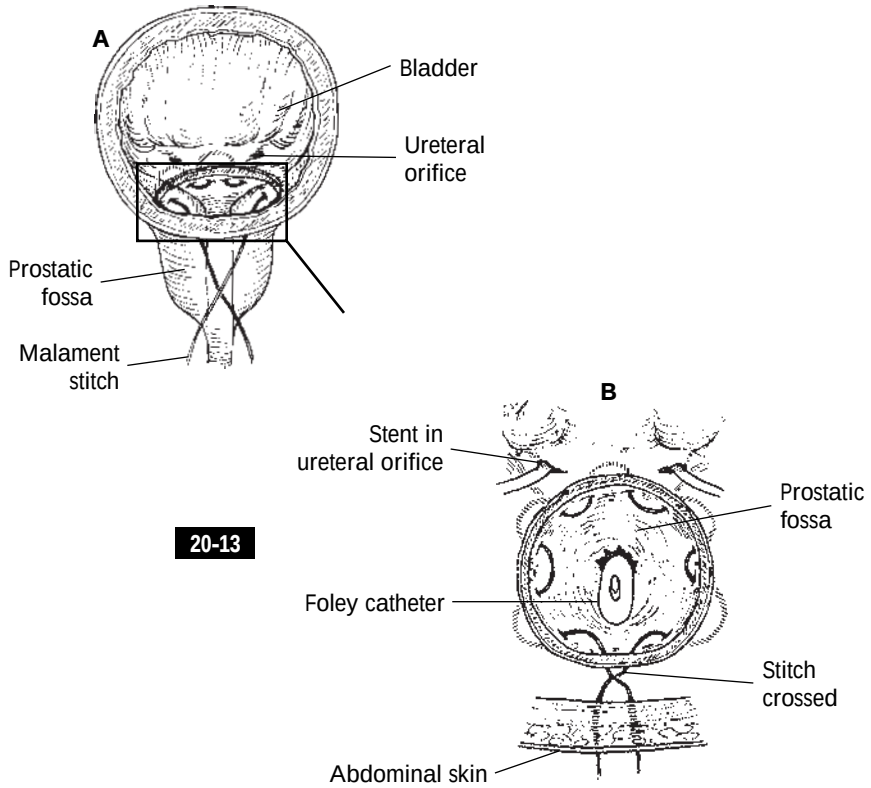

20-13

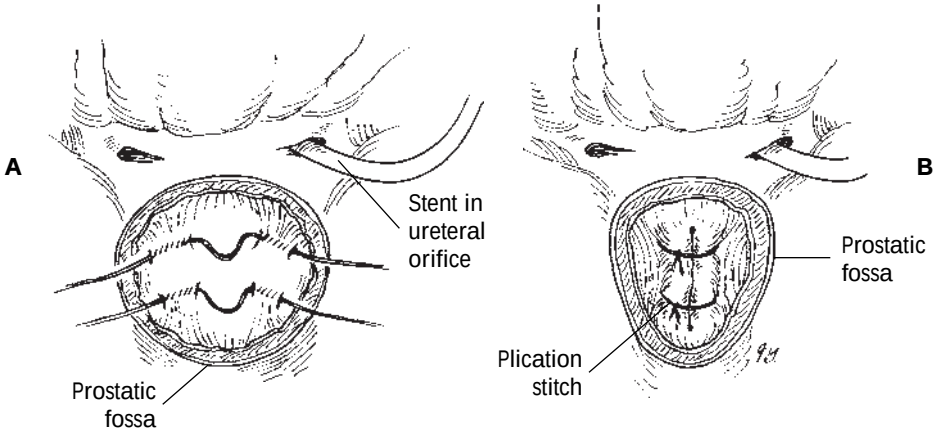

20-14

KEY POINTS

CONTROL OF BLEEDING BEFORE PROSTATE GLAND ENUCLEATION

- The hypogastric artery is ligated temporarily.
- The dorsal venous complex is ligated.
- Suture ligation of the prostatic pedicles is performed.

PROSTATE GLAND ENUCLEATION

- The bladder is exposed using a malleable retractor blade.
- The ureteral orifices are identified and stents are placed.
- A traction stitch is placed in the median lobe of the prostate gland.
- Proximal bladder dissection is performed via electrocautery incision in the prostatic capsule.
- Sharp and blunt dissection of the prostate base or distal dissection at the prostatic apex is performed.
- Finger pressure is applied against the prostate surface during prostate gland enucleation.

CONTROL OF BLEEDING AFTER PROSTATE GLAND ENUCLEATION

- A nasal speculum can be used for improved exposure of the prostatic fossa.
- At the 5- and 7-o'clock positions of the proximal prostatic fossa, running stitches can be placed.
- A 1-0 nylon Malament stitch can be used to compress the bleeding surfaces of the prostatic fossa.
- Plication stitches (0 chromic) can be placed to obliterate the prostatic fossa.

POTENTIAL PROBLEMS

- *Capsular laceration during enucleation:* Repair laceration and continue with the operation
- *Injury of ureteral orifice:* Place stent
- *Bleeding after enucleation of prostate gland:* Consider all maneuvers before and after enucleation as discussed

REFERENCES

1 Walsh PC, Oesterling JE: Improved hemostasis during simple retropubic prostatectomy, *J Urol* 143:1203, 1990.

2 Yu GW, Melograna FS, Miller HC: Surgical modifications for ligation of deep dorsal vein complex from the retropubic space, *Urology* 40:545, 1992.

3 Bensimon H: *Urologic surgery*, New York, 1991, McGraw-Hill, pp 253-261.

4 Cockett ATK, Koshiba K: *Manual of urologic surgery: comprehensive manuals of surgical specialties*, vol 5, New York, 1979, Springer-Verlag.

5 Mayo G, Zingg EJ: Prostatectomy. In *Urologic surgery: diagnosis, techniques, and postoperative treatment*, New York, 1976, John Wiley, pp 326-330.

6 Cohen SP, Kopilnick MD, Robbins MA: Removable purse-string suture of the vesical neck during suprapubic prostatectomy, *J Urol* 102:720, 1969.

7 Malament M: Maximal hemostasis in suprapubic prostatectomy, *Surg Gynecol Obstet* 120:1307, 1965.

8 O'Connor VJ Jr: Suprapubic prostatectomy. In Glenn JF, editor: *Urologic surgery*, Philadelphia, 1983, JB Lippincott, pp 853-860.

TRANSURETHRAL RESECTION OF THE PROSTATE GLAND

21

Prostatic sonographic studies of patients who have undergone a transurethral resection of the prostate gland reveal large volumes of residual prostate tissue surrounding the open channel. The objective of this operation is to create an open prostatic urethra with a resultant ovoid, funnel-shaped opening of the prostatic fossa.

The technology may change, but whether conventional electric cutting loops, laser beams, high-frequency electrovaporization, or newer modalities are used, the principles of this operation are the same.

Varying the strength of electric currents and laser beams can achieve two objectives: (1) to coagulate and denature tissues, which will result in tissue ischemia and hemostasis, and (2) to remove tissues by electric resection or vaporization by laser or high-frequency current.

In general, we will not perform transurethral resection in patients with an infected urinary tract. Even with preoperative administration of intravenous antibiotics, patients can suffer from urosepsis with severe blood pressure fluctuations postoperatively. It is better to treat the infection and then perform the elective surgery.

Diagnostic cystoscopy performed before the actual surgery provides the surgeon a chance to plan and adapt special variations of the operation, although some urologists have considered this to be an unnecessary step.

Before the resectoscope is inserted, urethral dilatation with Van Buren sounds will decrease the chance of iatrogenic stricture formation.

BLADDER NECK AND PROXIMAL PROSTATE RESECTION

The surgeon should always identify the location of the ureteral orifices before any maneuvers are performed because their position may vary in relation to the bladder neck.

FIG. 21-1. One of the troublesome bleeding sites associated with this surgery is the raw edges of the bladder epithelium, which can be difficult to find at the end of the resection. To avoid this problem, the surgeon coagulates this area before beginning the resection by resting the loop against the proximal side of the bladder neck at the 5-, 6-, and 7-o'clock positions and then coagulating these areas for 2 to 3 seconds each. Then, without the position of the cutting loop at the bladder neck being changed, a cut is made into the proximal prostate gland through this cauterized bladder neck epithelium. It is not necessary or wise to cauterize the epithelium in the remaining circumference of the bladder neck because oozing from lateral or anterior vessels can easily be seen and controlled.

FIG. 21-2. Especially in young men with small, obstructive prostate glands, aggressive circumferential resection of the bladder neck often results in bladder neck contractures.

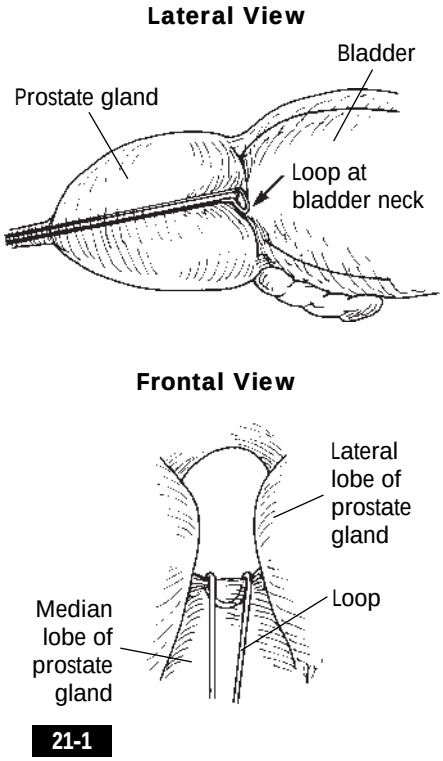

21-1

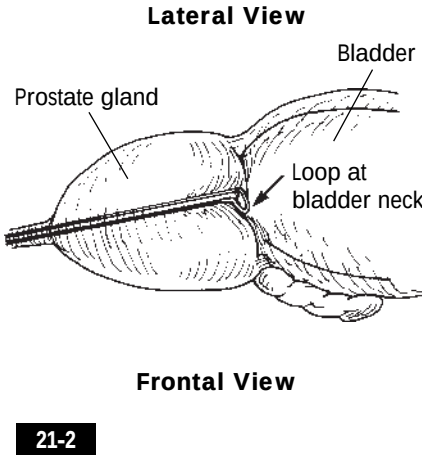

21-2

The surgeon should initiate these first three cuts at the 5-, 6-, and 7-o'clock positions with *straight,* full excursions of the cutting loop.

Even in the proximal resection of the prostate gland, the surgeon should always check for the location of the verumontanum, which is the *distal landmark* of the resection.

FIG. 21-3. We prefer to resect from the 7- to 11-o'clock positions and 5- to 1-o'clock positions **(A)** rather than use the Nesbit approach from the top[1] **(B).** The illustration shows the exact order of resection. It is best to resect the median lobe in two stages: one major part at the beginning of the procedure and the second trimming when the procedure is near completion.

Resecting down to the circular fibers in the major central portion of the prostate gland increases the surgeon's risk of cutting into venous sinuses and even capsular walls but will not increase the likelihood of improved voiding results postoperatively. Sculpting a smooth, funneled cavity with no bulging adenoma seen coming into the cavity should be the goal. Once this is accomplished, the resection has gone deep enough.

The proximal anterior aspect of the prostate gland from the 11- to 1-o'clock positions is usually thin. The surgeon should remember that it is also at the distal anterior prostate region where continence may be affected by the resection.

FIG. 21-4. While resecting a large median lobe, inexperienced surgeons invariably overcut or excessively "scoop" too early in the operation. This action results in elevation of the bladder neck with undermining of the trigone region. Once the trigone has been undermined by the excessive resection, the bladder neck at the 6-o'clock position moves further and further cephalad *(1, 2, 3)* as the surgeon continues the procedure. By the end of the surgery, the bladder neck not only has moved cephalad but also is elevated above the line of the urethra. Reinsertion of the scope and the Foley catheter is difficult.

The use of a guidewire with the Foley catheter often is required in catheter insertion into an undermined bladder. To facilitate insertion, the guided Foley catheter should "hug" the anterior urethra.

DISTAL PROSTATE RESECTION

FIG. 21-5. The verumontanum is always distal to the resection. The preservation of this landmark facilitates the various maneuvers for the distal resection.

Sequence of Transurethral Resection of Prostate Gland (Frontal View)

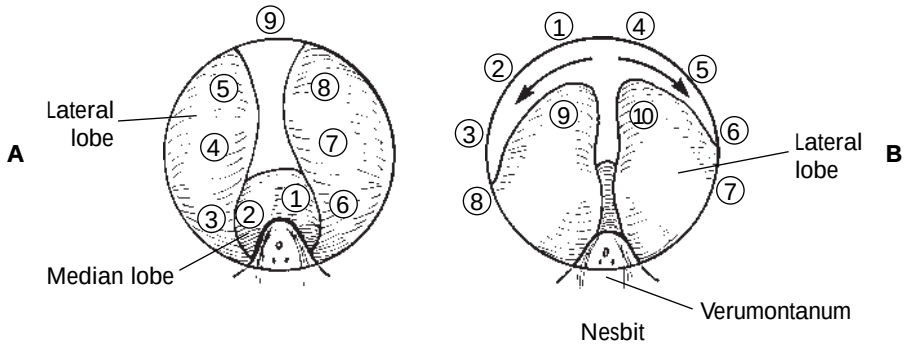

21-3

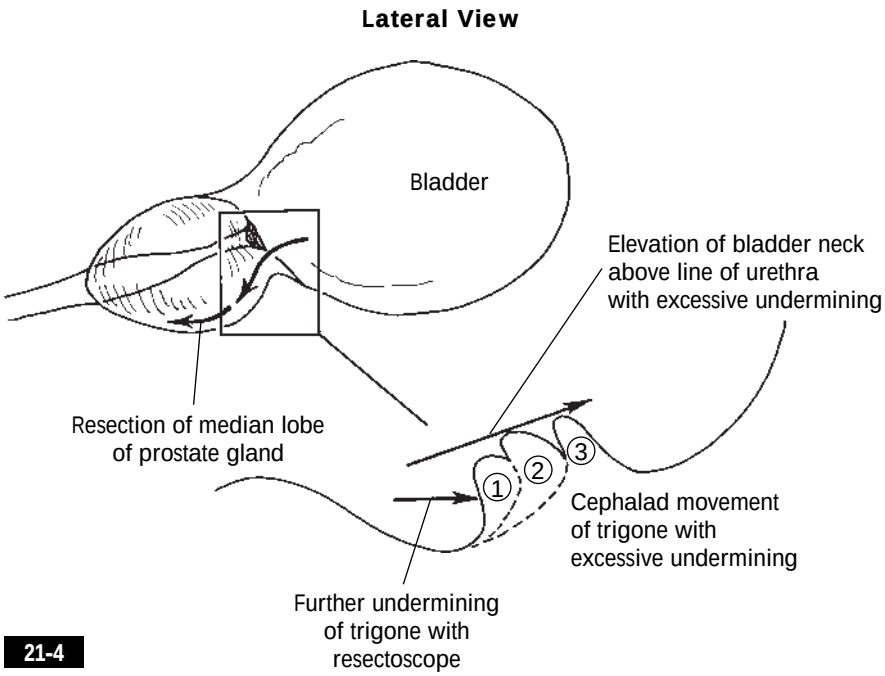

21-4

The surgeon first visualizes the verumontanum distally and then moves the resectoscope proximally or forward toward the bladder until the surgeon is no longer able to see this landmark; this is the correct distal margin of resection. In addition, this maneuver actually pushes the distal apical tissue to a more proximal position in relation to the verumontanum. Consequently, potential sphincter injury is avoided during the resection of this tissue.

The surgeon resects the lateral distal prostatic tissues (6- to 3-o'clock and 6- to 9-o'clock positions).

Some surgeons insert the index finger into the rectum through an O'Connor sheath during the resection of the floor of the prostate gland (5- to 7-o'clock positions), but we have not used this extra aid, believing it leads to undermining.

The anterior distal aspect of the prostate gland should be resected carefully in small "nibbles." There is little prostate tissue in this region, and excessive resection may lead to permanent incontinence.

The surgeon should visualize the verumontanum, move proximally, and then rotate the resectoscope 180 degrees for the anterior resection. The resection must not extend past the region of the verumontanum.

If the patient is in a Trendelenburg position, the surgeon must correct the orientation of the resectoscope to avoid a long anterior cut, which may end up more distal than the verumontanum.

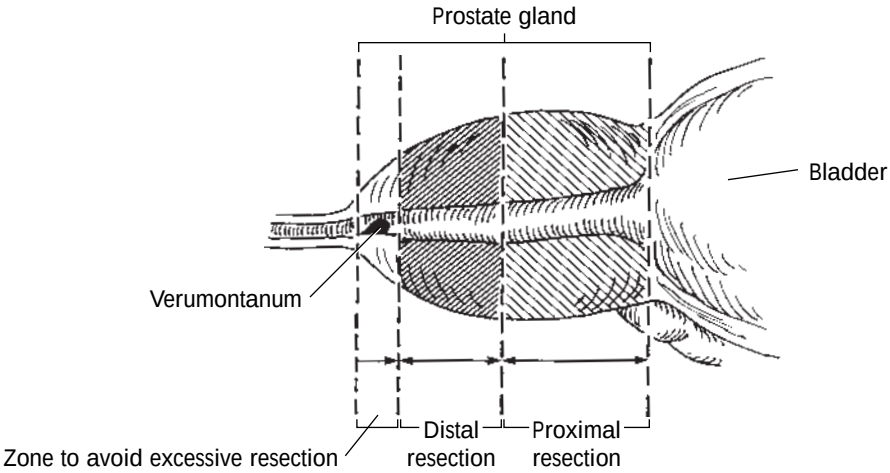

21-5

Resection in Straight Line Rather Than "Scooping" Motion

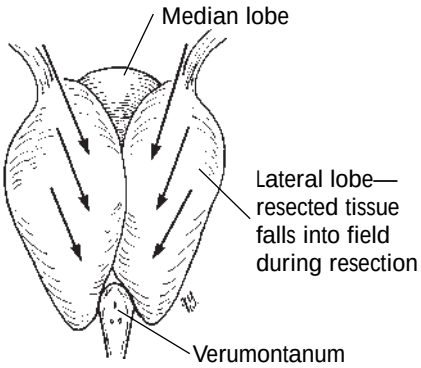

21-6

RESECTION TECHNIQUES

The size and shape of the prostatic "chips" reveal the experience and skill of the surgeon.

FIG. 21-6. Each cut should be smooth and straight with full excursion of the cutting loop.

The cutting current is engaged until the loop retracts inside the resectoscope.

Segments of resected prostate tissue are sometimes too large to fit through the resectoscope sheath. This usually means the surgeon has "scooped" during the cut. It should be avoided. Faced with very large fragments, the surgeon may have to recut the fragments and/or remove them with grasping instruments with or without removing the resectoscope sheath.

FIG. 21-7. The surgeon should avoid the temptation to "scoop" the prostatic tissue and should cut with *straight excursion* of the cutting loop because then the resected tissues will automatically fall into the resection field. Scooping cuts result in undermining of the trigonal region and cut into vascular sinuses and prostatic capsules unnecessarily.

If the tissues are oozing with blood, the surgeon should use a blend of cutting and coagulating currents to establish hemostasis while resecting tissues.

The thickness of the adenoma varies with each patient. Instead of relying on index finger palpation through an O'Connell sheath for arbitrary thickness of the remaining prostate wall, it is preferable to stop the resection when either no more bulging adenoma is seen when viewed from the verumontanum or when no more "mashed potatoes" (Miller's term) are seen during a cut. In either case, cutting deeper means entering the "circular fibers," which carries a great risk of troublesome bleeding. It does not make for easier voiding by the patient and it does waste time.

HEMOSTASIS

If a venous sinus is open, the surgeon must press the loop against the sinus and obliterate the opening before applying the electric current.

The surgeon should coagulate the tissue to obtain hemostasis while resecting prostatic tissues and not wait until the end of the operation to perform coagulation.

At the end of the surgery, the surgeon should establish a *systematic approach* to check for hemostasis, working from the bladder neck to the distal prostatic fossa.

It is best to check the anterior and lateral prostatic fossa first and leave the prostatic floor for last since the clots collect in this area.

Foley catheter tamponade of the prostatic fossa by traction of the catheter should remain a last resort to establish hemostasis.

Hemostasis should be complete at the end of the procedure, and all chips should be out of the bladder.

Transurethral Resection

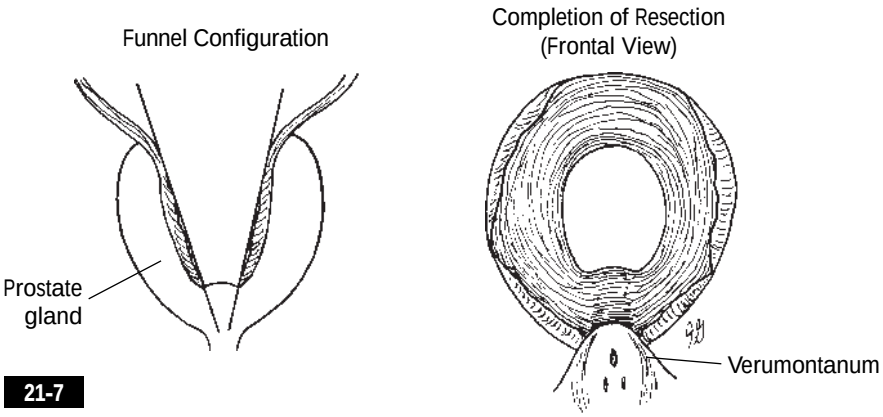

21-7

USE OF PERINEAL URETHROTOMY FOR TRANSURETHRAL RESECTION

FIG. 21-8. In situations in which the patient has had either a semirigid or even an inflatable penile prosthesis inserted, the rigidity of the proximal prosthesis or rear-tip extenders of the inflatable prosthesis pressing against the bulbous urethra prevents easy access and maneuverability of the resectoscope.

In this situation, a perineal urethrotomy facilitates access of the resectoscope into the prostatic fossa and bladder without lateral compression from the prosthesis.[1]

FIG. 21-9. After placing a 24 Fr Van Buren sound (with or without a groove) in the urethra, the surgeon incises the perineal skin (**A** and **B**) and continues the incision through the bulbospongiosus muscle and the corpus spongiosum into the urethra **(C).**

When the cut urethral edges expose the Van Buren sound within, the surgeon places full-thickness stitches from the urethral edges to the perineal skin on both sides **(D).**

The incision should be at least 3 cm in length. Three stitches on each side are required to keep the urethral edges fixed to the perineal skin.

The resectoscope is inserted through the urethrotomy for the resection.

At the end of the operation the Foley catheter is inserted through the penile urethra into the bladder, and the perineal wound is reapproximated with figure-of-eight stitches (2-0 chromic) from urethra to skin to compress the bleeding corpus spongiosum tissues.

Pressure Point of Prosthesis at Bulbous Urethra

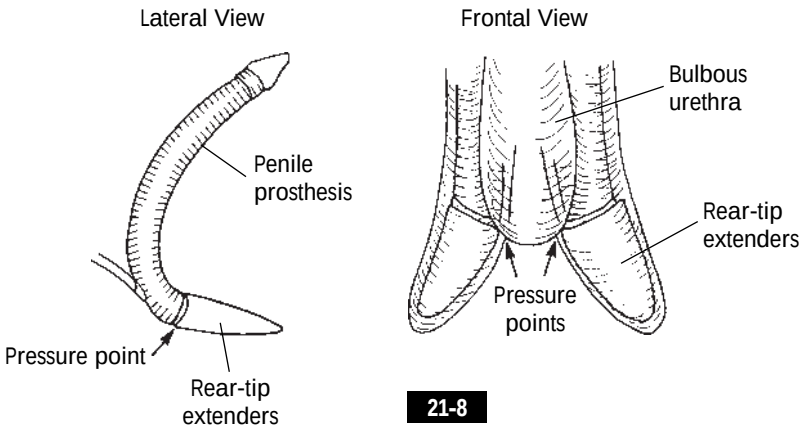

21-8

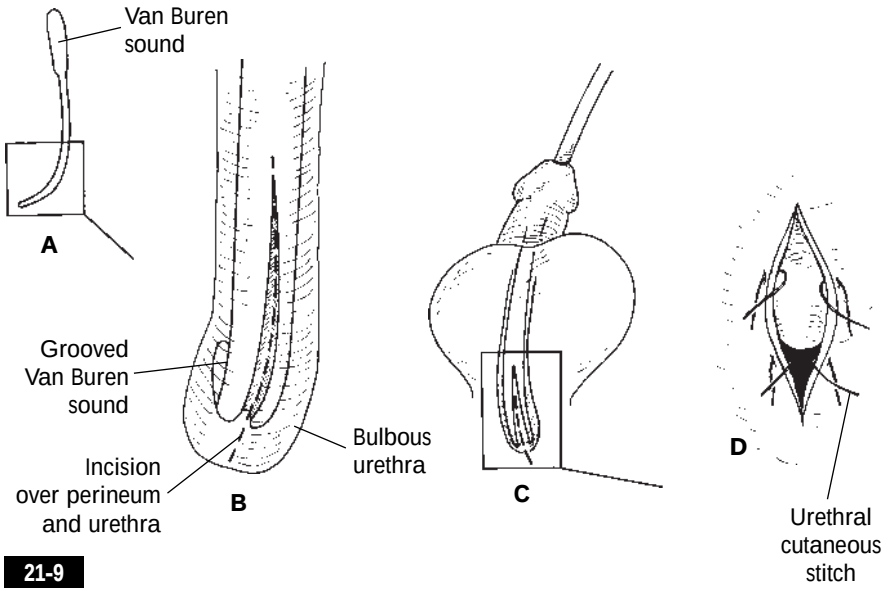

21-9

KEY POINTS

- The urethra is dilated with Van Buren sounds before inserting the resectoscope.
- The bladder neck epithelium is coagulated at the 5-, 6-, and 7-o'clock positions and then the proximal prostatic tissue is resected through the cauterized epithelium.
- The rest of the bladder neck muscles are preserved and the lateral prostatic lobes are resected from the 7- to 11-o'clock positions and 5- to 1-o'clock positions.
- The anterior lobe, especially the distal region, is carefully resected.
- The verumontanum is visualized and then the resectoscope is moved proximally toward the bladder past the verumontanum and the lateral tissues are resected.
- Small nibbles of the anterior distal aspect of the prostate gland are resected.
- A systematic check to verify hemostasis is conducted.
- The resection should not take longer than 1 hour.

POTENTIAL PROBLEMS

- *Venous sinus opened:* Press loop against the sinus to obstruct it and then coagulate
- *Capsular tear:* Continue the operation
- *Unidentifiable bleeding site:* Check the proximal bladder epithelial edges for bleeding
- *Prostatic chips too large for resectoscope sheath:* Press loop against chip, coagulate, and remove resecting loop with adherent chip
- *Hyperabsorption syndrome (hypertension, restlessness, nausea):* Provide furosemide (Lasix) diuresis and hypertonic saline replacement[2]
- *Trigone is undermined and attempted catheterization of bladder is unsuccessful:* Use a guidewire with the Foley catheter and pass it into the urethra so that it hugs the anterior urethral wall
- *Medical condition unstable:* Perform coagulation to achieve hemostasis and insert Foley catheter → postpone the resection

REFERENCES

1 Nesbit R: Transurethral prostatic resection. In Campbell M, Harrison J, editors: *Urology*, ed 3, vol 3, Philadelphia, 1970, WB Saunders, p 2490.

2 Holtgrewe HL: Transurethral prostatectomy, *Urol Clin North Am* 22:357, 1995.

SUGGESTED READINGS

Greene LF: Transurethral resection: technique, operative complications, and postoperative management. In Greene LF, Segura JW, editors: *Transurethral Surgery*, Philadelphia, 1979, WB Saunders, pp 108-179.

Mebust WK, et al: Transurethral prostatectomy: immediate and postoperative complications: a cooperative study of 13 participating institutions evaluating 3885 patients, *J Urol* 141:243-247, 1989.

URETHROPLASTY 22

FIG. 22-1. In an ideal situation, the surgeon should reconstruct a neourethral lumen of 30 to 40 mm circumference for the meatus and penile shaft, whereas the bulbous and the membranous urethral lumen should have a circumference between 40 and 50 mm. The circumference of the meatus should always be slightly larger than the penile urethra because it will usually contract in the healing stages.

Experienced surgeons realize that in most cases it is not possible to reconstruct a neourethral lumen of the ideal size and that it is necessary to improvise to achieve an end-to-end anastomosis or a pedicled patch graft as the second-best choice.

Whether the urethroplasty involves an anterior or posterior stricture, the principles of surgery are common to both.

FIG. 22-2. The entire diseased segment of stricture and the periurethral scar or fibrotic tissues must be excised until healthy tissues are identified on both ends **(A).**

The two ends are spatulated to create the largest lumen possible **(B).**

If the two spatulated ends can overlap by 2 cm **(C),** then a primary end-to-end anastomosis is possible. The approximation of urothelium to urothelium is the ideal reconstruction (**D** and **E**).

Urethroplasty in Various Locations

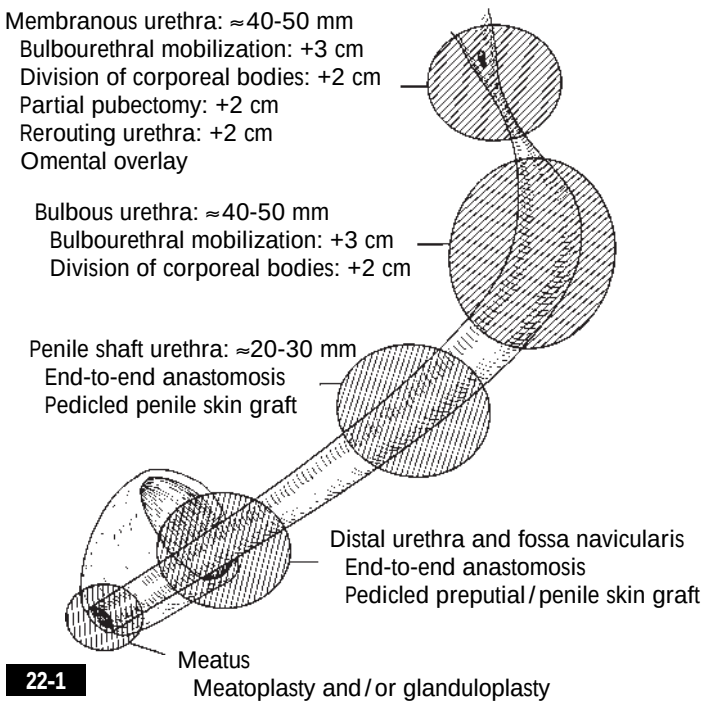

22-1

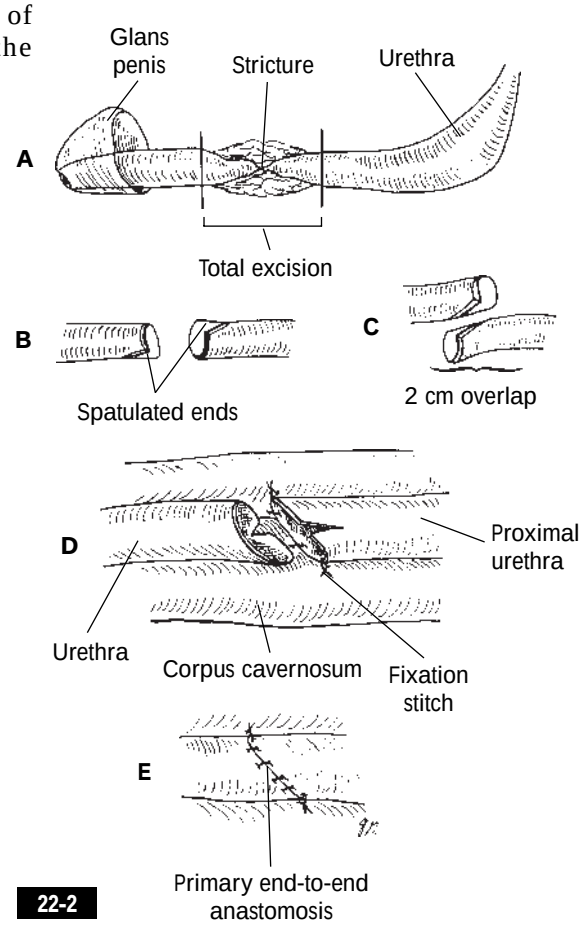

22-2

FIG. 22-3. If an overlap is not possible **(A),** the next best choice for urethral reconstruction is to incorporate "wet skin" in the repair. "Wet skin," such as penile and preputial skin, is ideal for grafts because it does not have hair-bearing properties and it will not contract to form scar or loosen to form a diverticulum.[1,2]

Pedicled skin grafts or skin flaps, with intact vasculature and lymphatics, have the highest chance of survival.

When choosing a pedicled skin graft, the surgeon should use a partial graft rather than a circumferential or tubular graft to complete the urethroplasty. Even with an intact blood supply, circumferential urethral grafts have a greater chance of stricture formation.

Whether an end-to-end anastomosis or a pedicled patch graft urethroplasty (**B** and **C**) is performed, *fixation* of the proximal end and *flattening* of the urethral lumen are critical maneuvers for the success of the operation.[1,2] Fixation of the proximal urethra ensures that there is no tension at the anastomosis. Flattening the lumen prevents postoperative urethral contractions and cross adhesions leading to strictures. For pedicled patch graft urethroplasty, fixation and flattening of the "roof" or anterior urethra with urothelial continuity of the two free ends are critical for a successful result.

For anterior urethroplasty, the surgeon excises the stricture, spatulates the ends, and then fixes and flattens the proximal and/or distal ends to the adjacent corporeal cavernosal bodies before the anastomosis. For a patch graft, the anterior surfaces of the urethral ends are fixed and flattened to the corporeal bodies before graft placement.

FIG. 22-4. The Turner-Warwick bilaterally pedicled island penile skin procedure and the Orandi procedure are excellent choices for a pedicled patch graft.[1-3] The pedicled patch in the Turner-Warwick procedure receives its blood supply from both sides and thus has excellent vascularity.

Pedicled Patch Graft Urethroplasty

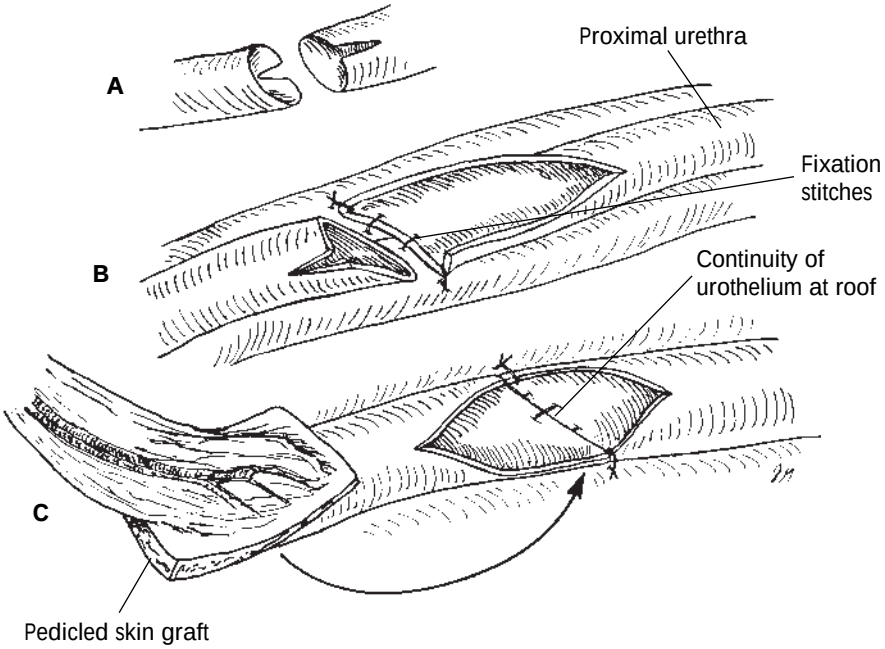

22-3

Turner-Warwick Procedure

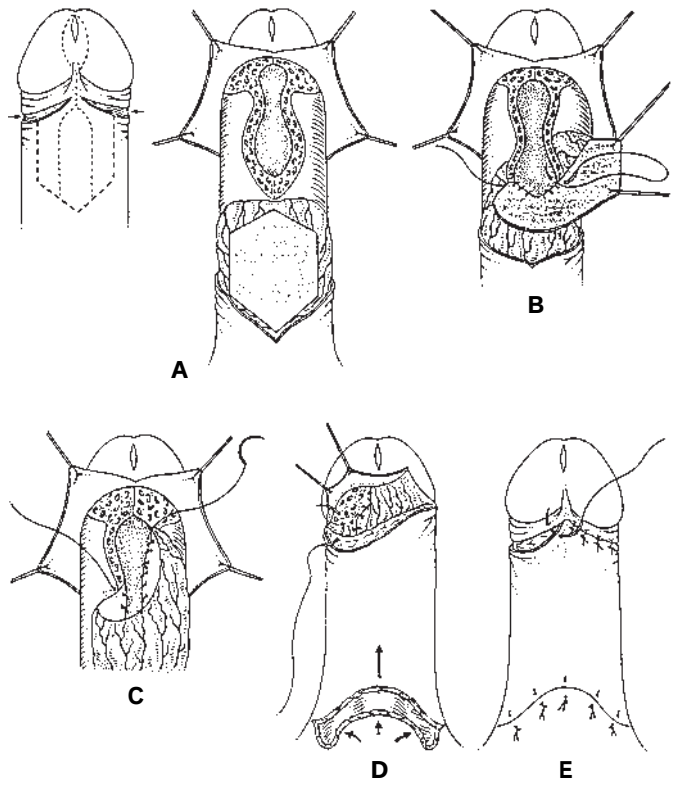

22-4

Lithotomy Position for Combined Perineal and Abdominal Approach

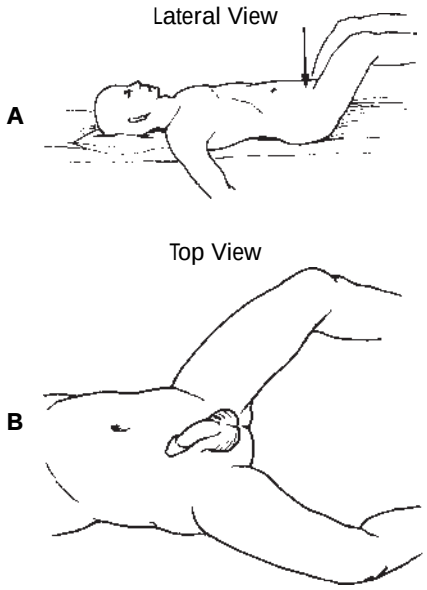

Exaggerated Lithotomy Position

22-5

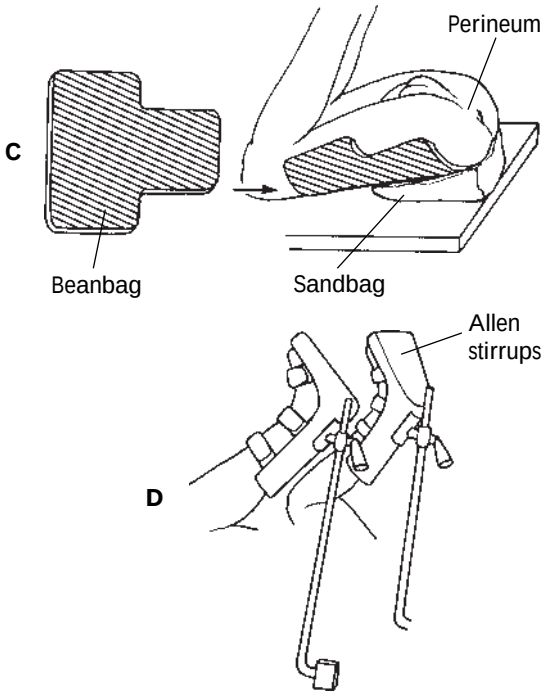

PATIENT POSITIONING FOR POSTERIOR URETHROPLASTY

FIG. 22-5. For this procedure we prefer a simple moderate lithotomy position, which allows easy access to both the perineum and the lower abdomen (**A** and **B**). Some surgeons prefer to have the patient in an exaggerated lithotomy position as for radical perineal prostatectomy, whereby the perineum is actually parallel to the floor of the operating room **(C)** (see p. 189). Allen stirrups **(D),** sandbags or a beanbag, and shoulder supports are all useful to maintain this position throughout the operation.[2,4]

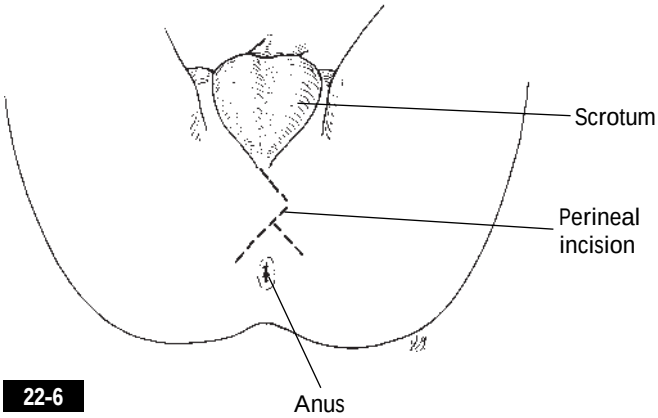

22-6

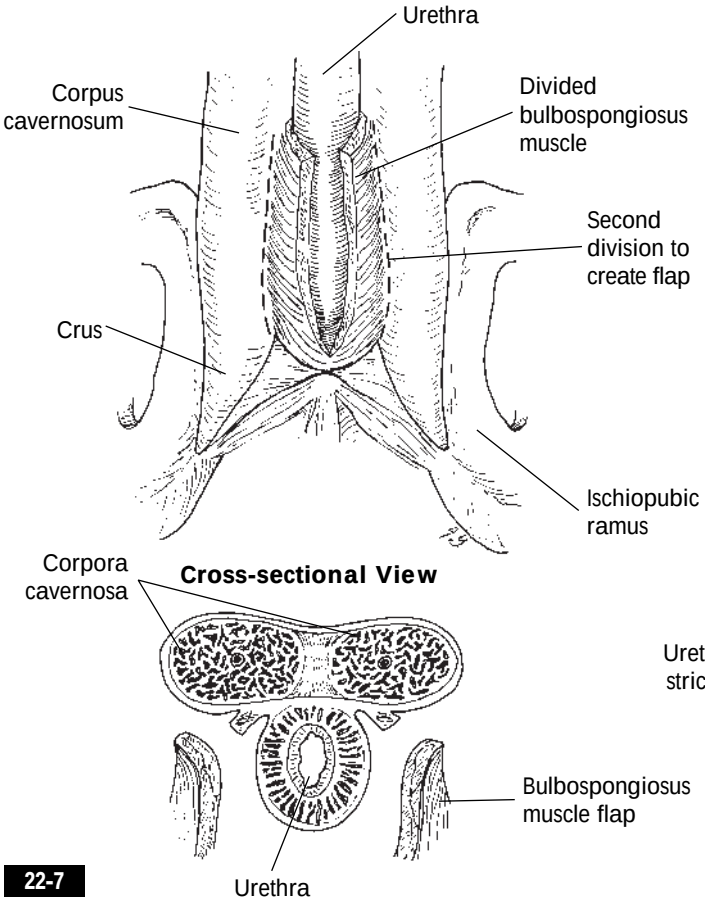

22-7

DISSECTION OF THE BULBOUS URETHRA

FIG. 22-6. After the skin incision, with the aid of a Van Buren sound (22 to 24 Fr) placed to the point of the stricture, the surgeon dissects through the perineal fat and identifies the bulbospongiosus muscle surrounding the posterior urethra.

FIG. 22-7. This muscle is divided at the midline as well as at the lateral borders so that it can be peeled off as two flaps for later use.

FIG. 22-8. After the diseased stricture segment has been excised, the surgeon can dissect the thick corpus spongiosum, leaving only a 3 mm thick residual tissue layer surrounding the proximal healthy urethra and thus creating two flaps of corpus spongiosum for later use.

FIG. 22-9. These two layers are reapproximated after urethral reconstruction to add support, prevent diverticulum formation, and fill in dead spaces, which can accumulate extracellular fluid.

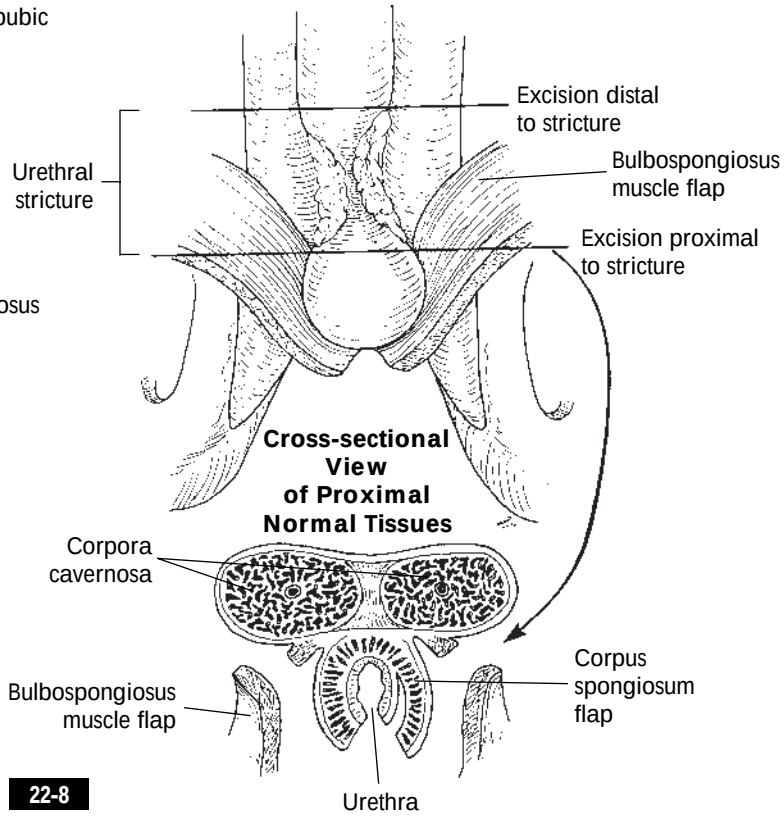

22-8

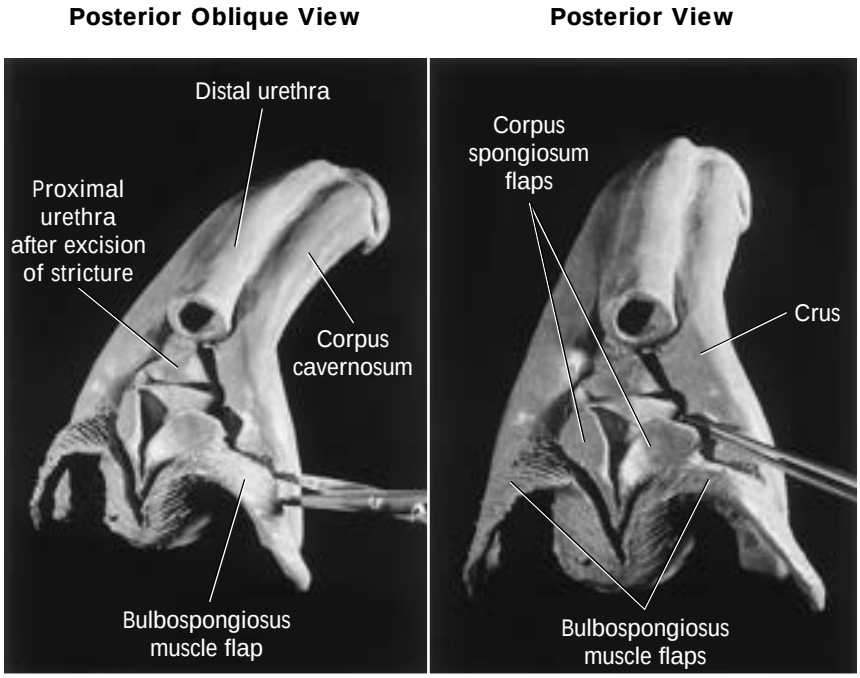

22-9

URETHRAL RECONSTRUCTION

FIG. 22-10. As noted previously, the best reconstructive option is an end-to-end anastomosis if a 2 cm overlap of the two healthy ends is possible **(A).** A pedicled patch graft would be the second choice **(B).**

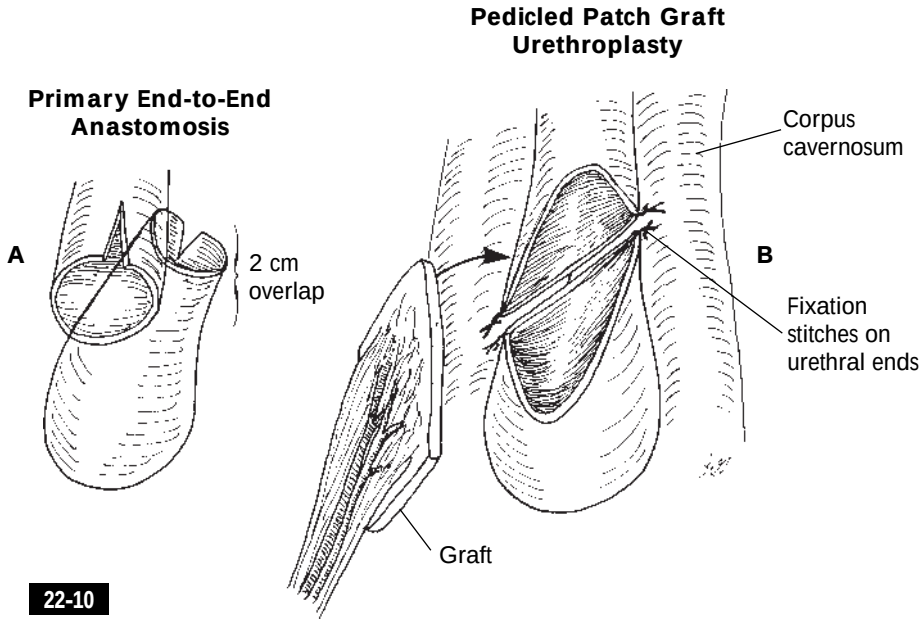

22-10

Cross-sectional View

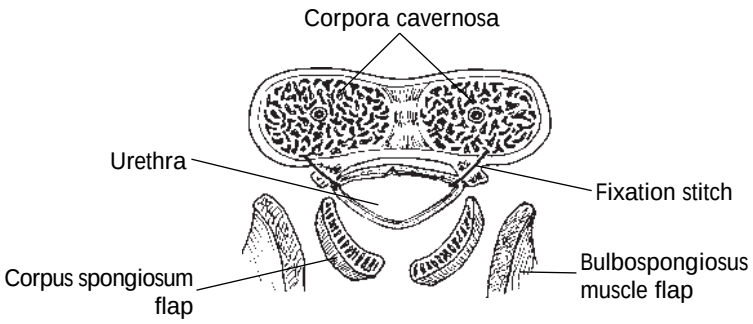

22-11

Posterior Oblique View

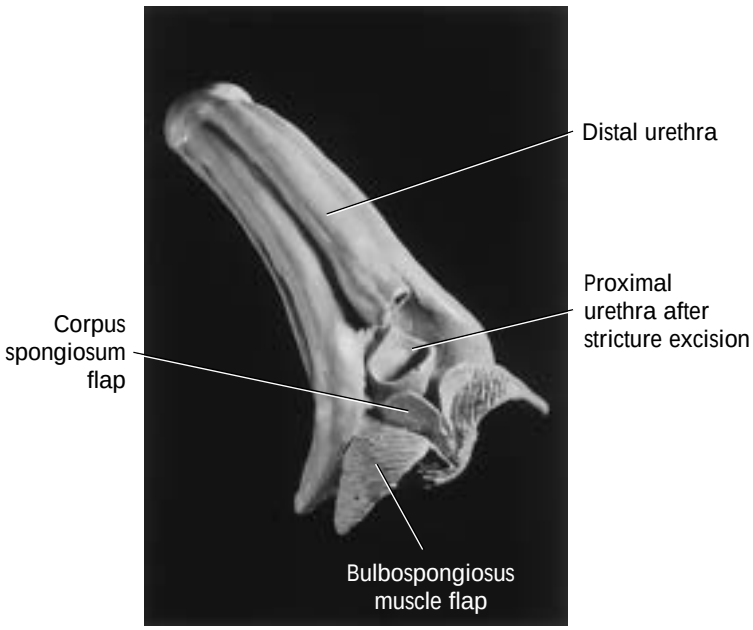

22-12

Turner-Warwick Needles

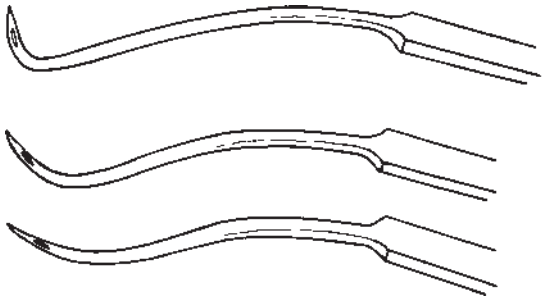

22-13

FIGS. 22-11 AND 22-12. No matter which method of urethroplasty is selected, the most important maneuver is fixation and flattening of the proximal and/or distal urethral ends after urethral spatulation. The fixation stitch (2-0 Vicryl) is secured to the lateral corporeal bodies or the crura, which are more proximally located. With the securing of these fixation stitches, in essence the flattening effect is simultaneously accomplished. The anterior urethra or "roof" of the urethra is flattened against the corporeal bodies above. This will not only avoid placing tension on the urethral anastomosis but also create a wide, flattened urethral lumen that cannot contract.

FIGS. 22-13 AND 22-14. The use of Turner-Warwick needles facilitates stitch placement in a small confined space.

In every case the surgeon must be prepared to use a pedicled graft if a primary end-to-end anastomosis is not possible.

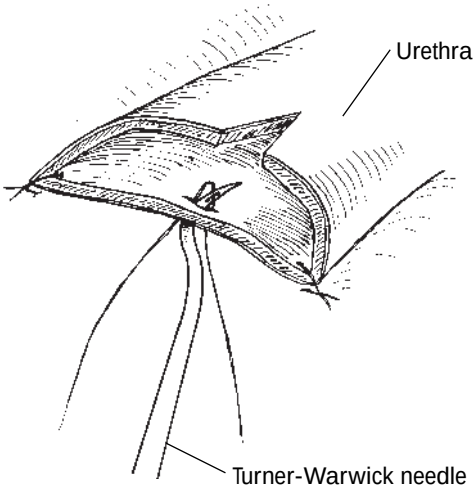

22-14

FIGS. 22-15, 22-16, AND 22-17. "Wet" penile *(1)* or preputial *(2)* skin can be mobilized down to the perineal region as a pedicled flap *(3)* with its own blood supply.[5] Although scrotal skin has rich vascularity, its hair-bearing properties, elasticity (which can lead to potential diverticulum formation), and reactions to direct contact with urine (encrustation) make it less desirable as the first choice for a pedicled graft.

If a scrotal pedicled graft is to be used, a staged approach is required. In the first stage, the hair on the scrotal skin is epilated. In the second stage 4 to 6 months later, the scrotal pedicled graft must be stretched maximally to cover the strictured segment, thus avoiding diverticular formation in the late postoperative period.[6]

If pedicled scrotal grafts or flaps are used for a second layer or as the only alternative for the primary urethroplasty, it is important to create this flap from one side of the scrotum *(4)*. Flaps that cross the median raphe will have poor vasculature at the distal half (*5* and *6*).

Different Sites for Pedicled Skin Graft

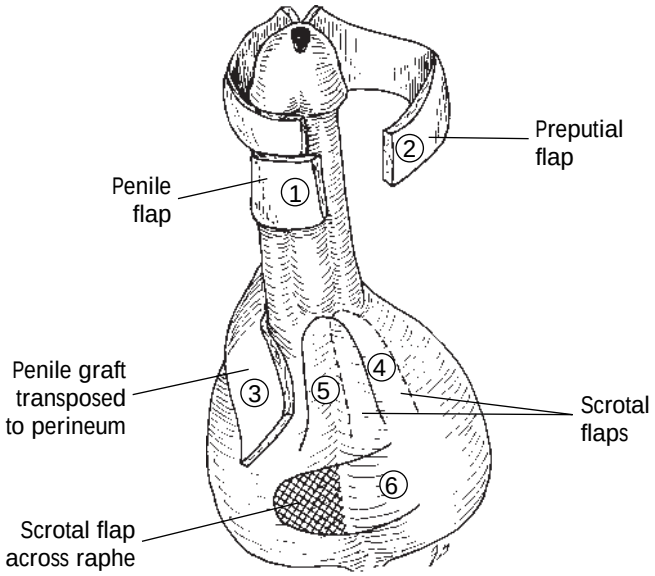

22-15

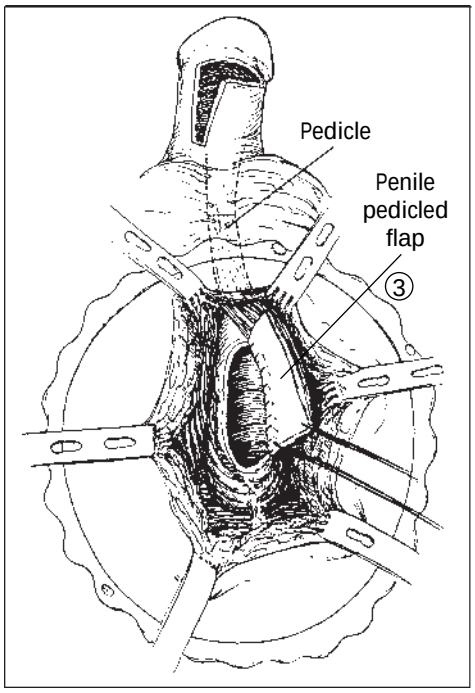

From Bensimon H: *Urologic surgery,* New York, 1991, McGraw-Hill.

22-16

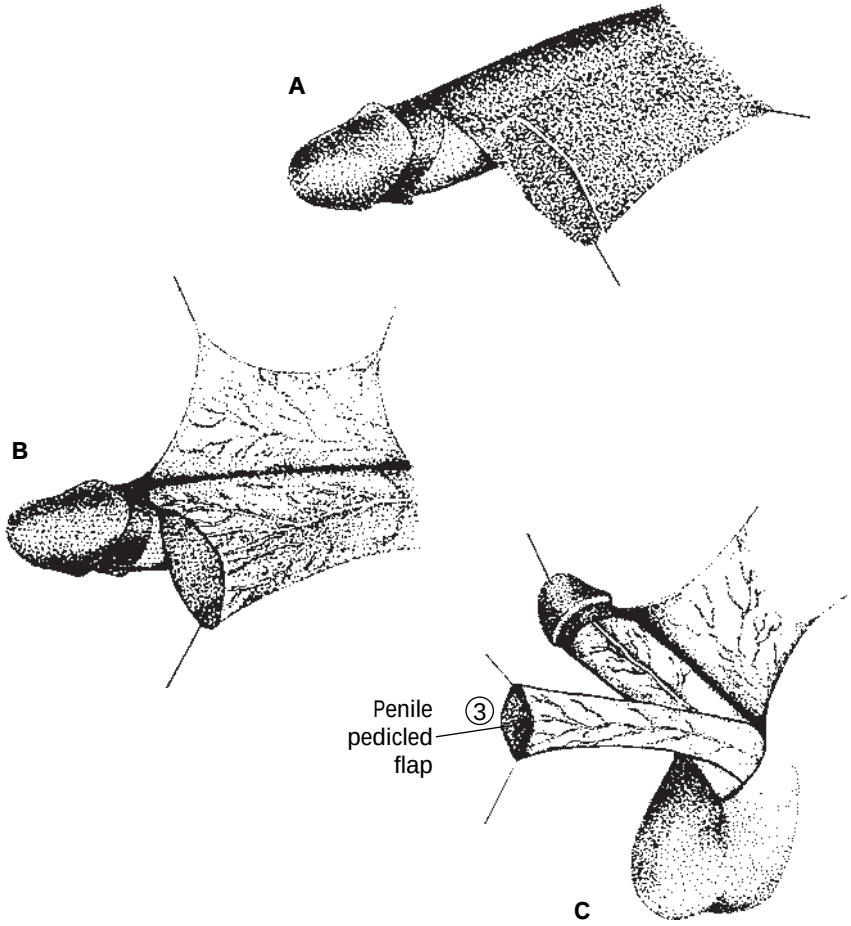

From Quartey JKM: *J Urol* 129:284, 1983.

22-17

Operative Maneuvers to Approximate Free Urethral Ends

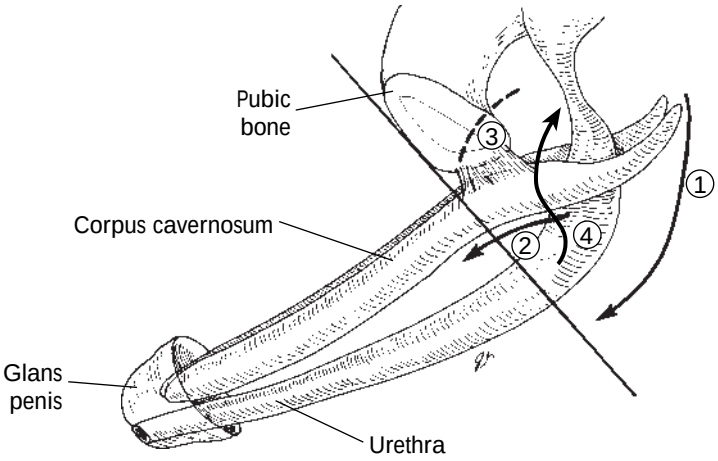

22-18

POSTERIOR URETHRAL MOBILIZATION

FIGS. 22-18 AND 22-19. After the excision of the stricture, the surgeon has the option to use a number of maneuvers to bring the two healthy urethral ends as close as possible[7,8]: bulbourethral mobilization *(1)*, division of the triangular fascia and corpora cavernosa *(2)*, partial inferior pubectomy *(3)*, and rerouting the urethra around one corporeal body *(4)*. We prefer to use a combined perineal and abdominal approach to complete the reconstruction. While mobilizing the urethra below, the surgeon can create the cystostomy and pass the Van Buren sounds or guidewires down the bladder neck to define the proximal urethral end for the urethroplasty.

Freeing the bulbous urethra distally to the level of the base of the penis adds an additional 3 cm of length. This maneuver does not devascularize the urethra as long as the dissection remains just proximal to the base of the penis.

Bulbourethral Mobilization

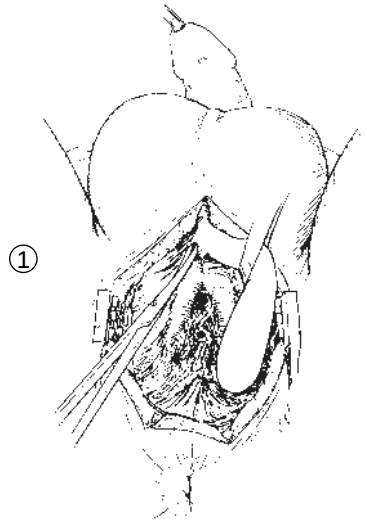

Division of Inferior Fascia and Corpora Cavernosa

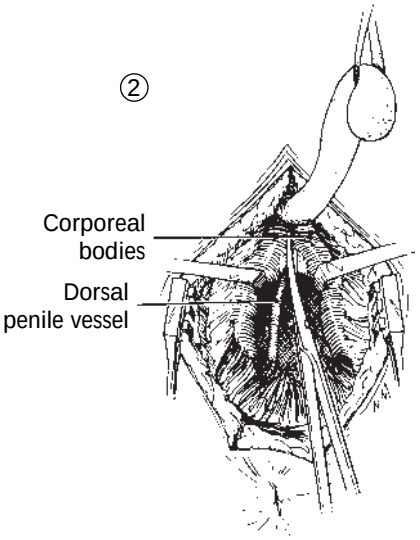

Partial Inferior Pubectomy

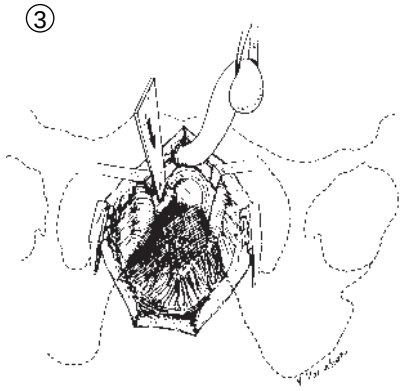

Rerouting Urethra Around Corporeal Body

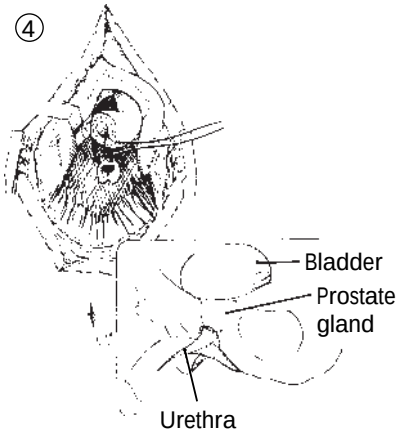

From Webster G, Ramon J: *J Urol* 145:744, 1991.

22-19

FIG. 22-20. Division of the inferior (triangular) fascia of the urogenital diaphragm and the proximal corpora cavernosa at the midline by 3 to 4 cm shortens the distance between the two urethral ends by another 2 cm. This maneuver does not lead to excessive bleeding or subsequent impotence.

FIGS. 22-21 AND 22-22. After dividing the dorsal penile vein, the surgeon can perform a partial pubectomy of the inferior surface of the pubic bone by using Kerrison or Adson rongeurs to remove a segment of bone, thus creating a horseshoe-shaped defect. This maneuver shortens the distance between the two urethral ends by another 2 cm. The rough inner surface can be further enlarged and smoothed with a dermal abrader.[9]

Corporeal Body Separation and Division of Inferior Fascia

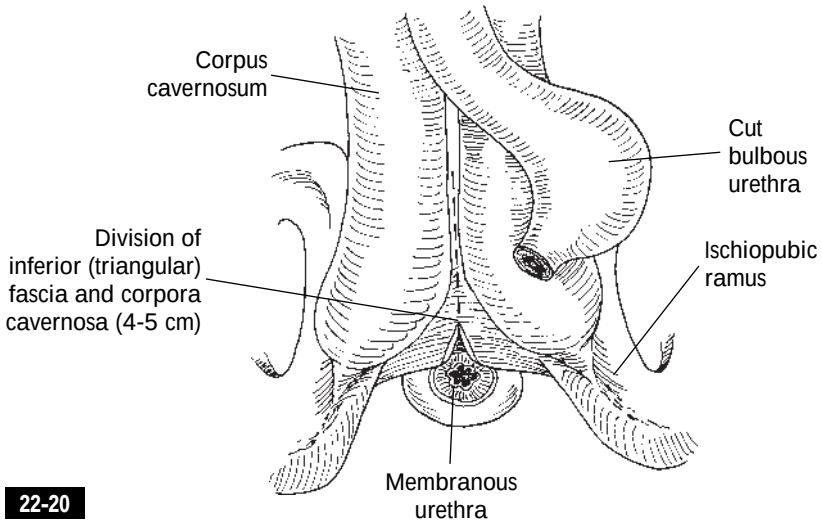

22-20

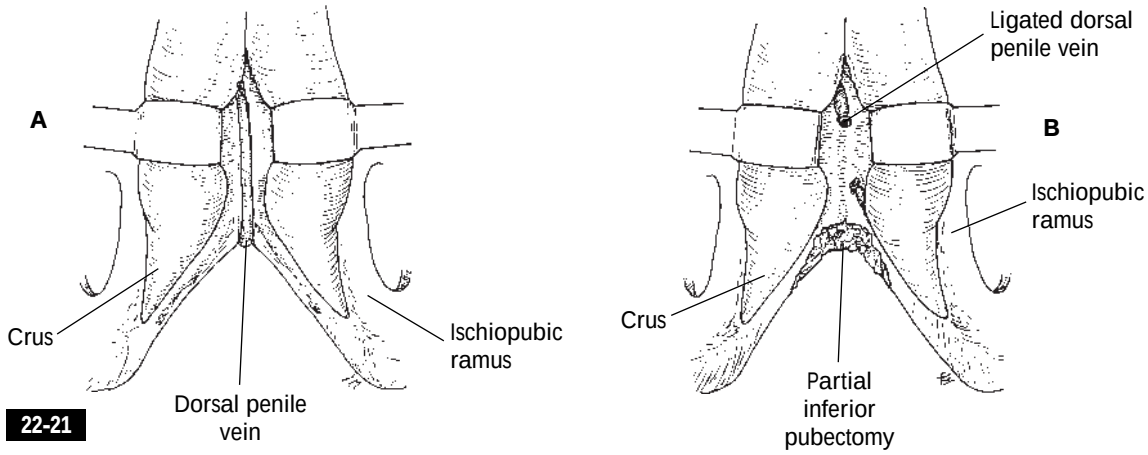

22-21

Lateral View **Frontal View**

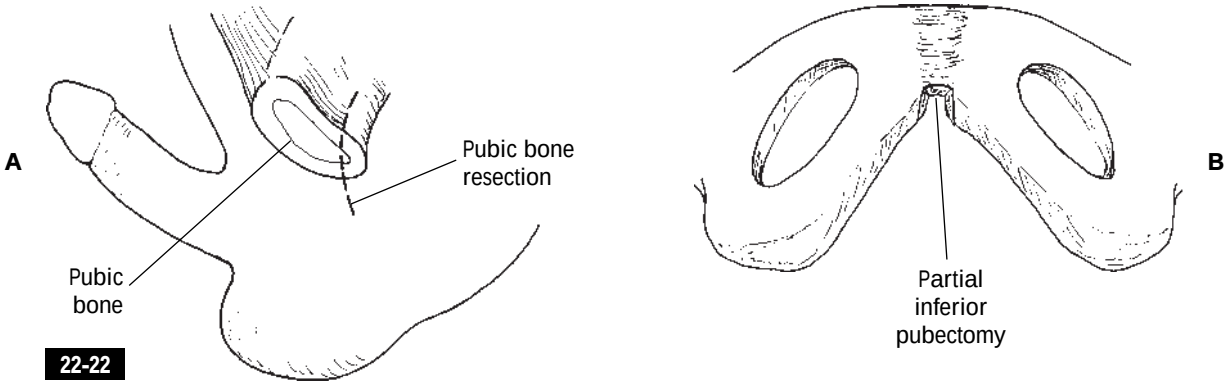

22-22

Excessive Pubectomy

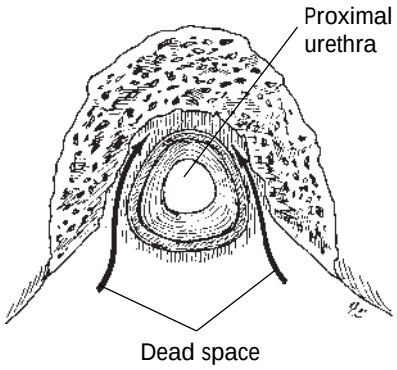

22-23

FIG. 22-23. This defect should not be too large because it can act as a compartment of dead space for fluid accumulation. After the urethroplasty, the surgeon should use the two residual corpus spongiosum flaps and the two bulbospongiosus muscle flaps to fill the space around the defect of the pubectomy. If this tissue is insufficient, the surgeon can incorporate omentum into this space.

FIG. 22-24. Rerouting the urethra around one corporeal body surprisingly shortens the distance between the two urethral ends by another 2 cm.

FIG. 22-25. If all of these maneuvers for the urethroplasty cause a slight ventral chordee of the penis, the surgeon has the option of dividing the suspensory ligaments at the penile base to correct the problem with minimal retraction of the penis.

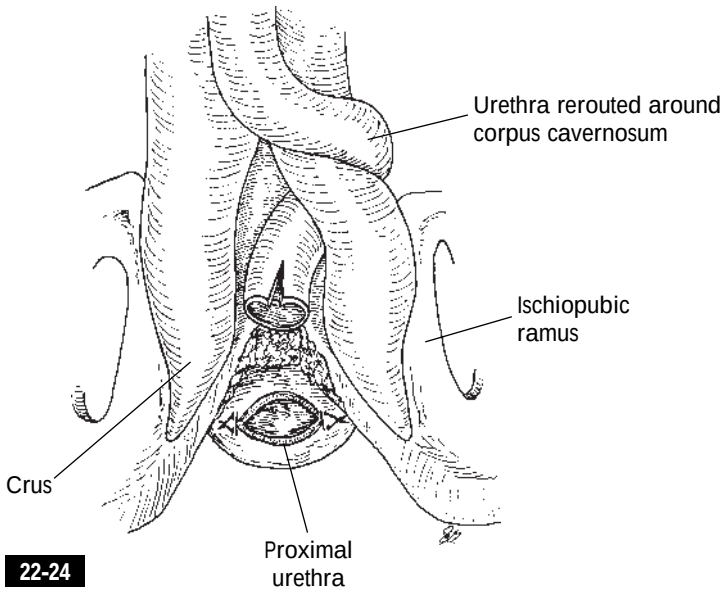

22-24

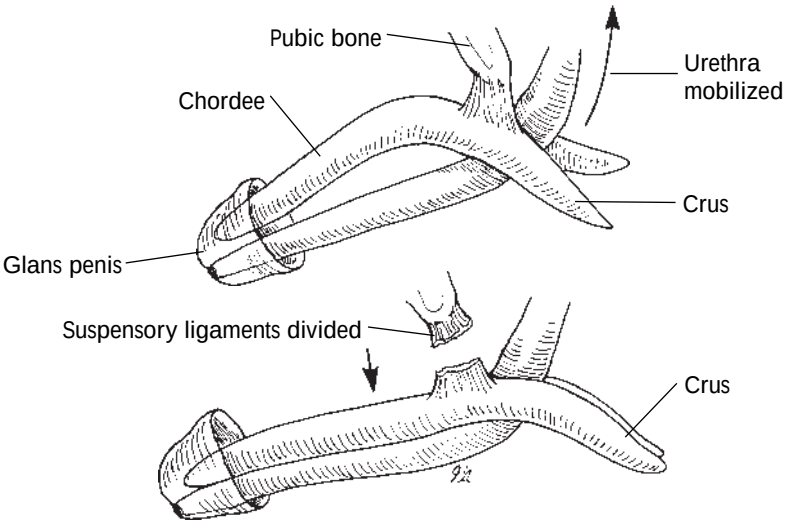

22-25

URINARY DIVERSION AND SUPRAPUBIC CATHETERS

The suprapubic tube should be the main route for urinary diversion.

FIG. 22-26. For stenting the urethroplasty, we prefer to use Silastic tubing (16 to 19 Fr) with a cutout trough[10] placed from the meatus past the segment of the urethral repair. For anterior urethroplasty, the stent is placed up to the bulbous urethra and secured at the meatus *(1)*. For posterior urethroplasty, the stent is placed past the bladder neck and secured with a nylon suture to the abdominal wall *(2)*.

FIG. 22-27. The stent is placed so that it extends 3 mm from the tip of the glans meatus and it is sutured in position with fixation stitches.

FIG. 22-28. The use of a fenestrated tube through the urethra and secured to a suture fixed to the abdominal wall is also an excellent method to ensure proper urethral drainage.[1,2]

Open-Trough Silastic Stent

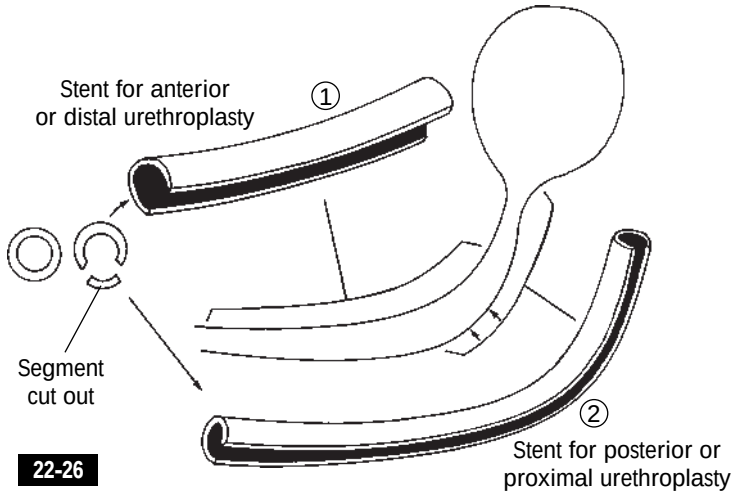

22-26

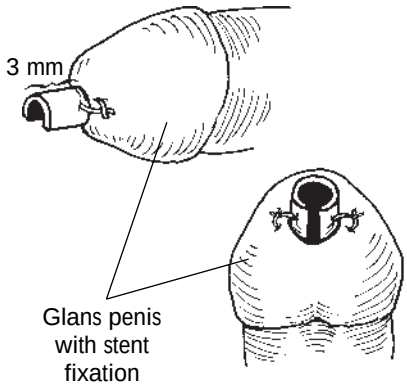

22-27

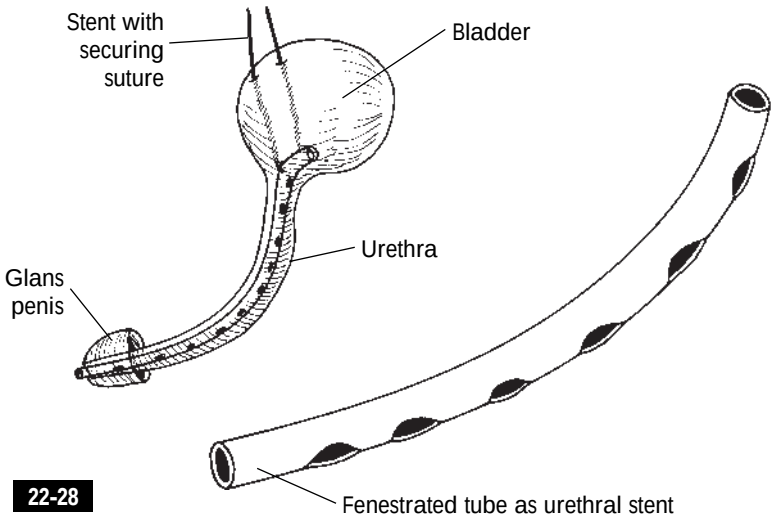

22-28

SPONTANEOUS NOCTURNAL PENILE TUMESCENCE

FIG. 22-29. We regularly induce an artificial erection with an intracorporeal injection of prostaglandin E_1 (20 µg) after the urethroplasty to check for excessive skin tension. If the surgeon believes that the tension could jeopardize the repair, small relaxing incisions 1 to 2 mm in length can be made on the dorsal penile skin to decrease the tension. Multiple, small incisions heal much faster than one large incision.

TWO-STAGE REPAIR WITH THE DROPBACK MANEUVER

If the surgeon plans a two-stage posterior urethroplasty, the scrotal dropback maneuver is useful in the preparation period 6 to 8 months before the second stage.[1,2]

By mobilizing the scrotum posterior to the marsupialized strictured segment, the surgeon can easily inspect and manipulate the area of future reconstruction.

Even with urethral marsupialization, which not only fixes but also flattens the urethral plate, it is inevitable to have cross synechial adhesions that require dilatation.

Multiple epilations ensure that proper, hairless adjacent skin will be available for the neourethra.

FIG. 22-30. After a perineal incision is made **(A),** urethrotomy is performed and should include the entire strictured segment.

Scar tissues around the urethra are totally excised proximally and distally.

The residual urethral plate should be *fixed and flattened* to the adjacent corporeal bodies.

The scrotum is pulled posteriorly behind the strictured site **(B),** and a second incision is made that is superimposed over the urethrotomy of the strictured segment. By this maneuver, the surgeon has essentially moved the scrotum into a *more posterior or inferior position* in relation to the strictured segment.

After the second incision is made, the urethral plate edges, which have already been fixed to the corporeal bodies, are sewn to the edges of the second incision **(C).**

The first incision is reapproximated in a horizontal configuration and a drain is left within. In essence, the first incision has been moved posterior to the strictured urethral segment.

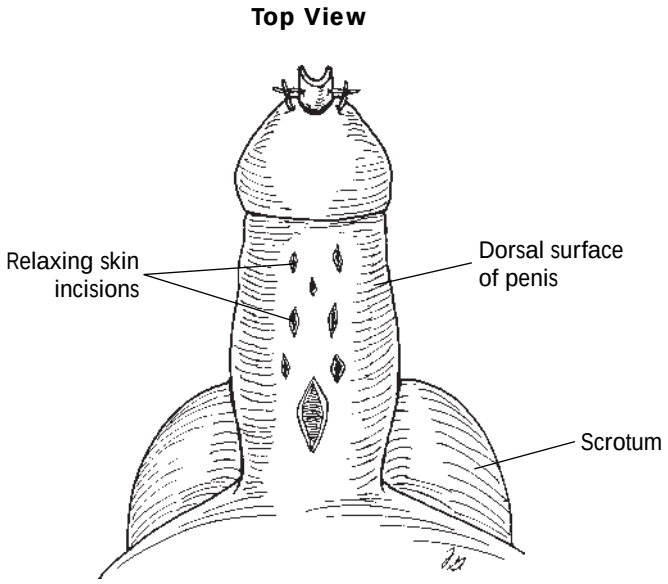

22-29

Scrotal Dropback Maneuver (Posterior View)

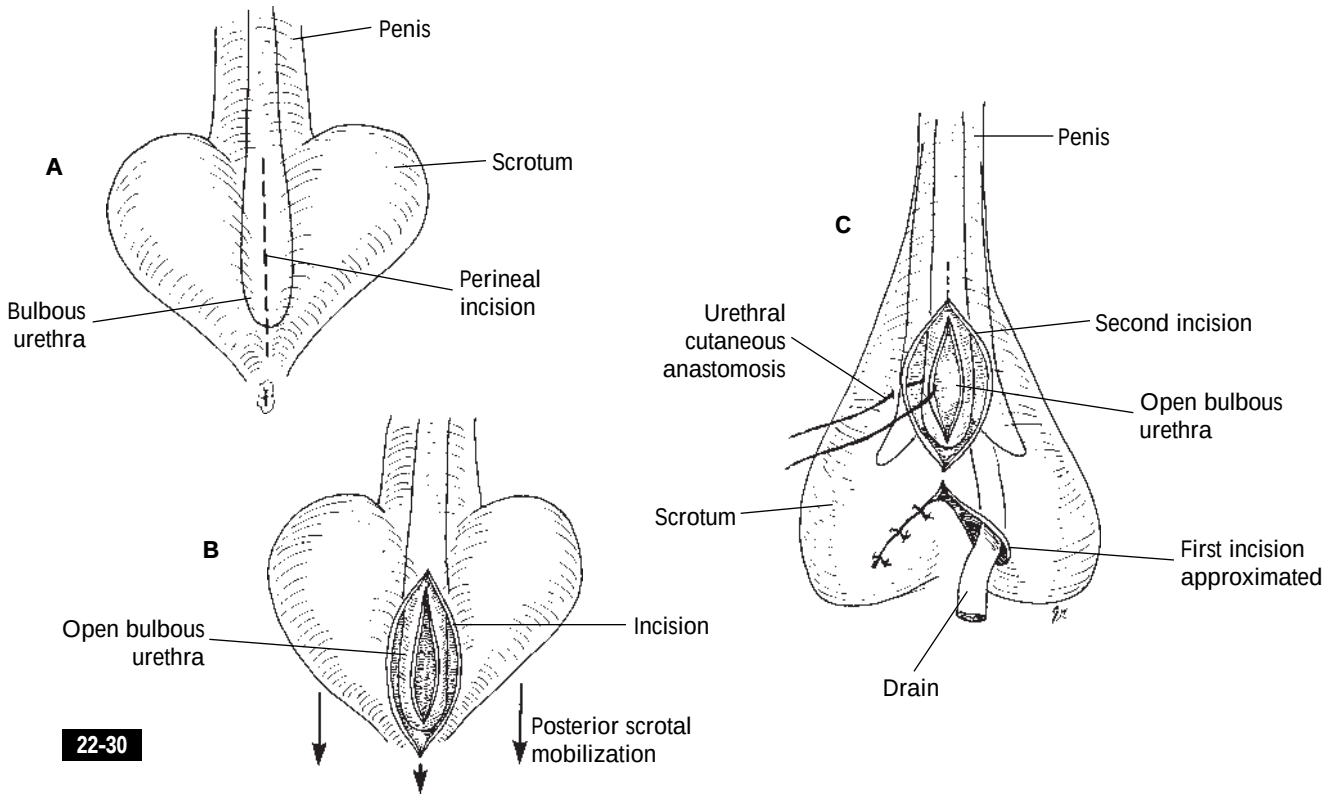

KEY POINTS

- An end-to-end anastomosis is the reconstructive procedure of choice; a pedicled skin graft is the next alternative.
- Complete excision of the stricture is performed.
- A 2 cm overlap of the spatulated urethral ends is optimal.
- The urethral ends are fixed to and flattened against the corpora cavernosa and a tension-free anastomosis is then performed.
- For a pedicled skin graft, the "roof" or anterior urethral ends should be fixed, flattened, and in continuity.
- For the pedicled graft, "wet skin" from the penis should be used and a partial rather than a circumferential repair should be performed.
- If necessary, maneuvers for posterior urethroplasty should be performed to bring the two urethral ends closer: bulbourethral mobilization, division of the inferior (triangular) fascia and the proximal corporeal bodies, partial inferior pubectomy, and urethral rerouting.
- Via a combined perineal and abdominal approach, the cytostomy is created and sounds or guidewires are used to define the proximal and distal urethral ends.
- The residual corpus spongiosum flaps and the bulbospongiosus muscle flaps are reapproximated to provide support for the urethroplasty and to fill the dead spaces.
- If necessary, the suspensory ligaments are divided.
- A suprapubic tube is placed to serve as a urinary stent.
- An artificial erection is induced to check for skin tension. If necessary, small relaxing incisions are made on the dorsal penile skin to decrease tension.

POTENTIAL PROBLEMS

- *End-to-end anastomosis not possible:* Use a pedicled patch graft
- *Penile pedicled skin graft cannot reach posterior urethra:* Use scrotal skin as a second choice → perform a dropback procedure for delayed two-stage urethroplasty using epilated scrotal skin
- *Excessive dead space around posterior urethroplasty:* Fill dead space with omentum
- *Ventral chordee after mobilization maneuvers and urethroplasty:* Divide the suspensory ligaments
- *Excessive skin tension after repair with or without erection:* Make relaxing incisions on the dorsal penile skin

REFERENCES

1. Turner-Warwick R: Complications of urethral stricture surgery and some ways of preventing them. In Smith RB, Ehrlich RM, editors: *Complications of urologic surgery,* Philadelphia, 1990, WB Saunders, pp 435-457.
2. Turner-Warwick R: Complications of urethral surgery in the male. In Skinner D, Smith RB, editors: *Complications of urologic surgery, prevention and management,* Philadelphia, 1976, WB Saunders.
3. Orandi A: One-step urethroplasty: 4-year follow-up, *J Urol* 107:977, 1972.
4. Devine CJ, Jordan GH, Schlossberg SM: Surgery of the penis and urethra. In Walsh PC et al, editors: *Campbell's urology,* vol 3, ed 6, Philadelphia, 1992, WB Saunders, pp 2959-3032.
5. Quartey JKM: One-stage penile/preputial cutaneous island flap urethroplasty for urethral stricture, *J Urol* 129:284, 1983.
6. Blandy JP, Singh M: The technique and results of one-stage island patch urethroplasty, *Br J Urol* 47:83, 1975.
7. Webster GD: Perineal repair of membranous urethral stricture, *Urol Clin North Am* 16:303, 1989.
8. Webster G, Ramon J: Repair of pelvic fracture posterior urethral defects using an elaborated perineal approach: experience with 74 cases, *J Urol* 145:744, 1991.
9. Golimbu M, Al-Askari S, Morales P: Transpubic approach for lower urinary tract surgery: a 15-year experience, *J Urol* 143:72, 1990.
10. Mitchell ME, Kulb TB: Hypospadias repair without a bladder drainage catheter, *J Urol* 135:321, 1986.

SUGGESTED READINGS

Bensimon H: Penis and urethra. In *Urologic surgery,* New York, 1991, McGraw-Hill, pp 351-369.

Middleton RG, Sutphin MD: Pubectomy in urological surgery, *J Urol* 133:635, 1985.

Miller EB, Schlossberg SM, Devine CJ: New incision for penile surgery, *J Urol* 150:79, 1993.

23

The Use of Deepithelialization in Urethroplasty

Healing in any reconstructive surgery depends on not only the intact arterial supply but also the reconstitution of venous and lymphatic drainage. Without adequate drainage, extracellular fluid collections form dead spaces and lead to complications.

The additional use of the deepithelialization technique in reconstructive procedures such as in hypospadias repairs and urethroplasties in the construction of the neourethra or as flaps to cover the neourethra has resulted in more successful outcomes with a significantly lower incidence of fistula formation.[1,2]

In contrast to deeper reticular dermis, superficial papillary dermis contains smaller caliber vasculature and lymphatic vessels. Removing the epidermis with the preservation of part of the papillary dermis not only avoids extensive trauma and hemorrhage but also maintains the integrity of more of the smaller caliber arteries, veins, and lymphatics. The traumatized smaller vessels seem to recanalize faster than the deeper, larger caliber vessels.

When the surgeon performs a deepithelialization procedure, the object is to harvest the epidermis while retaining in situ as much of the papillary and reticular dermis as possible.

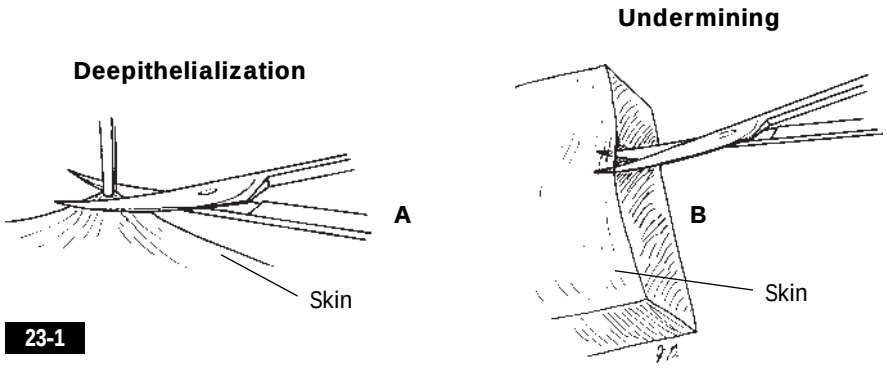

23-1

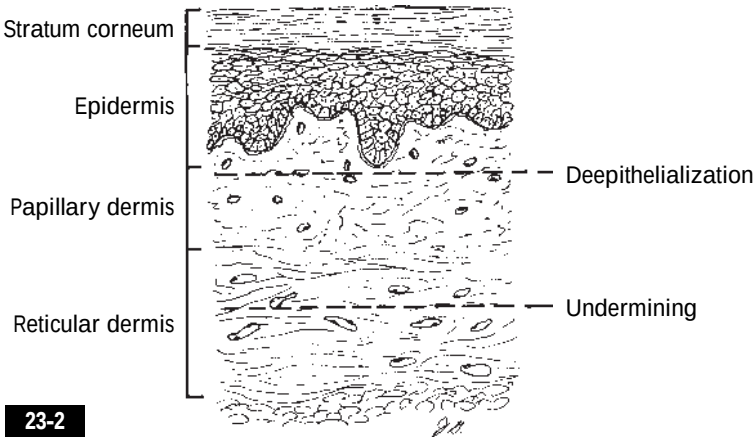

23-2

FIGS. 23-1, 23-2, AND 23-3. We prefer to use the deepithelialization technique described by Belman[1] and Smith.[2] Cutting away the epidermis with fine tenotomy scissors (Fig. 23-1, **A**) produces the simplest and best results, even though the method is time-consuming.

In our experience, histologic examinations confirm that papillary dermis is preserved by this deepithelialization technique, whereas with undermining of the skin (Fig. 23-1, **B**) this dermis layer has a greater chance of being destroyed. Although much faster, skin undermining techniques seem to pene-

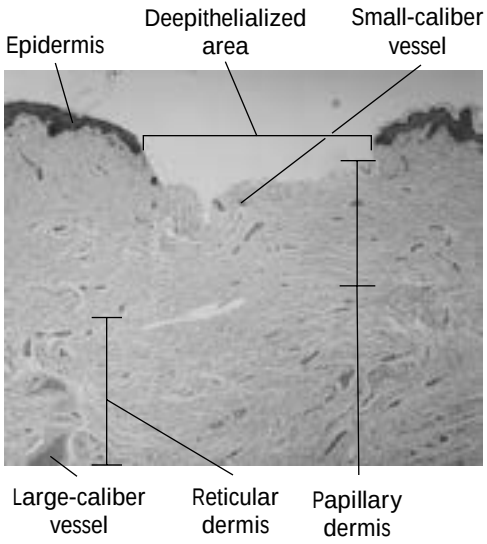

Courtesy Joan E. Woodward, M.D., Anne Arundel Medical Center; and Carmen M. Williams, M.D., George Washington University Medical Center.

23-3

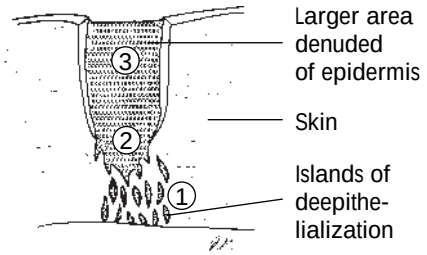

23-4

trate deep into the reticular dermis more often with resultant soft tissue trauma and hemorrhage.

FIG. 23-4. Although the deepithelialization technique is a tedious process, a large area can be denuded by taking small islands of epithelium *(1)* that collect into large areas (*2* and *3*). The surgeon does not need to use magnifying lenses to perform this procedure.

Belman[1] and Smith[2,3] have used deepithelialized skin for flaps to cover hypospadias repairs with a resultant fistula rate of less than 5%.

We have adapted this same technique used in hypospadias repairs and incorporated it in urethroplasty procedures for adults with urethral stricture disease.

We have used pedicled flaps of preputial and penile skin for the neourethra and flaps of deepithelialized scrotal skin to cover the neourethra.

FIG. 23-5. For both hypospadias repair and urethroplasty, we have used partially deepithelialized flaps in which the remaining dermis serves as the pedicle of the neourethral graft *(1)*. In addition, deepithelialized penile and scrotal skin has been used as a secondary flap to cover the primary repair *(2)*.

FIG. 23-6. For a second-degree hypospadias repair involving midshaft hypospadias, the surgeon can select a skin segment for neourethra reconstruction and deepithelialize the skin surrounding the neourethra rather than undermining on both sides.

Deepithelialization ensures maximal integrity of the underlying arterial, venous, and lymphatic systems in the area of the neourethra.

The denuded area of papillary and reticular dermis should be used as flaps and reapproximated before skin closure.

FIG. 23-7. For fistula closure, after the fistula is repaired primarily *(1)*, deepithelialized skin around the fistular tract can be used as a dermal flap to serve as a second layer of closure *(2)* before the skin edges are reapproximated *(3)*.

FIG. 23-8. For midshaft urethral stricture disease, the surgeon can incorporate deepithelialized skin around a selected pedicled skin graft. The opposite skin edge can be deepithelialized and used as a secondary flap to cover the neourethra.

FIG. 23-9. For posterior urethral strictures in which primary reanastomosis is not possible, a pedicled patch skin graft is useful.

Penile skin, characterized as "wet" and not reactive to urine,[4] can be tunneled from its origin to the reconstructive site.[5]

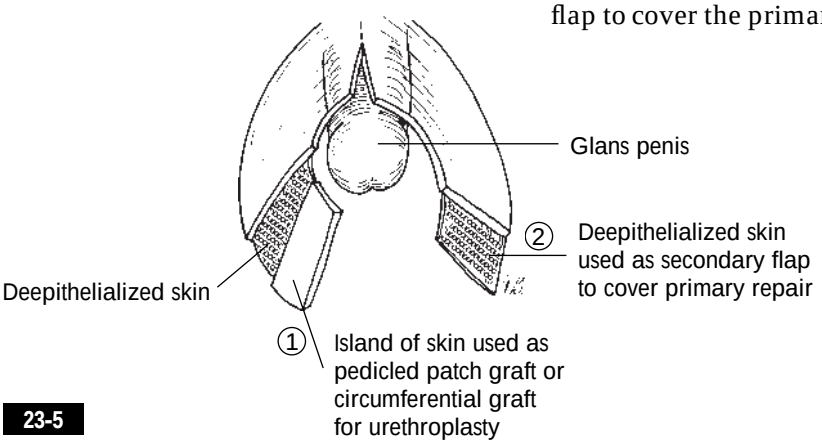

23-5

Deepithelialization for Hypospadias Repair

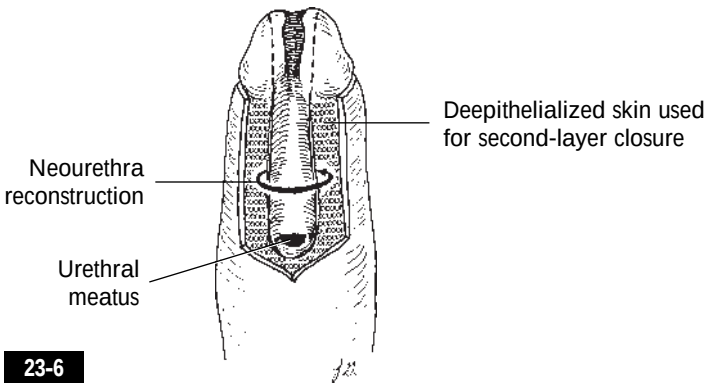

23-6

Deepithelialization for Fistula Closure

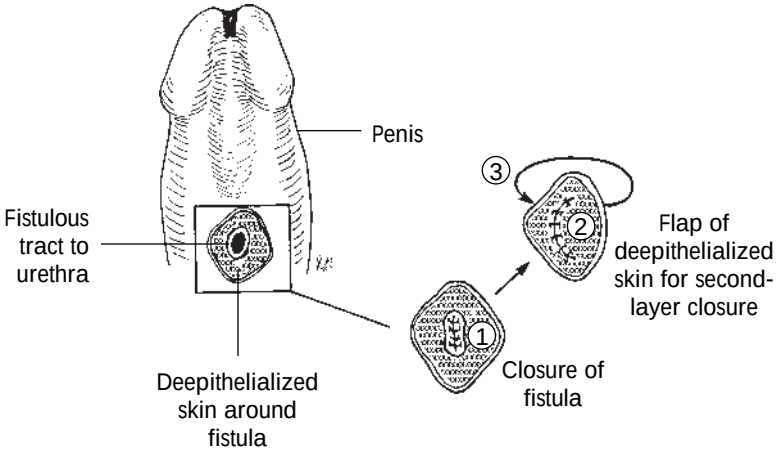

23-7

Pedicled Skin Graft for Patch Graft Urethroplasty

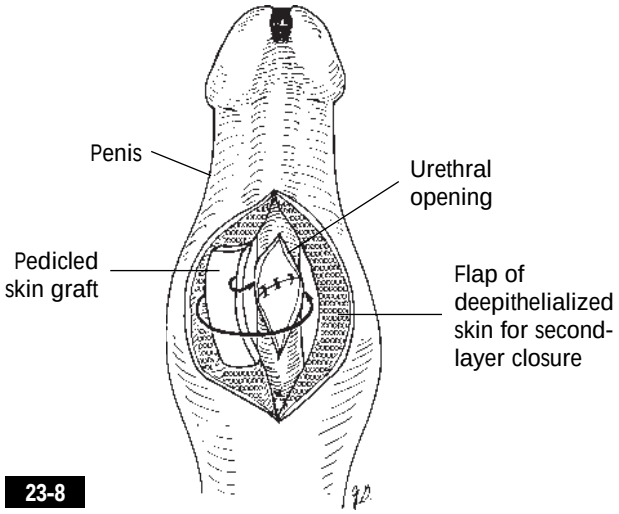

23-8

Deepithelialization to Preserve Vascularity for Pedicled Graft in Posterior Urethroplasty

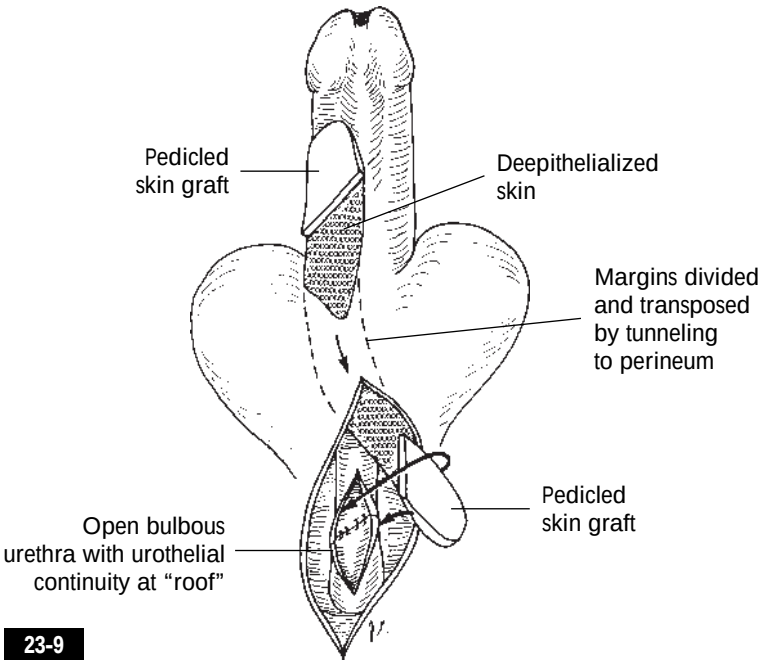

23-9

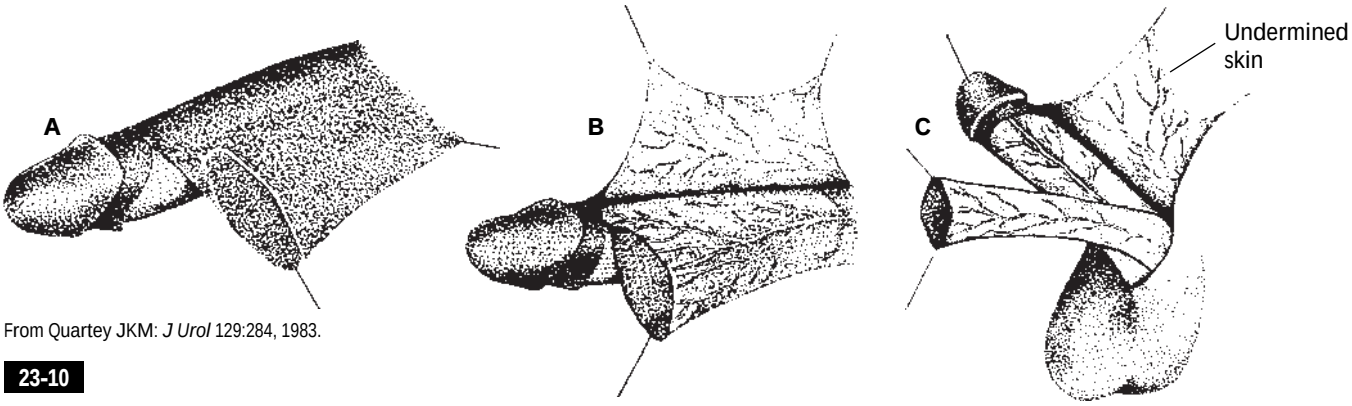

From Quartey JKM: *J Urol* 129:284, 1983.

23-10

FIG. 23-10. Once the skin segment for the pedicled graft has been selected **(A),** the surgeon can deepithelialize the pedicled portion **(B)** instead of undermining the penis skin,[5] free the deepithelialized segment **(C),** and tunnel it to the posterior urethral region.

This technique preserves the vasculature of the pedicled skin graft and that of the adjacent penile skin. In Quartey's series,[5] one complication involved ischemia of the remaining penile skin on the undermined side **(B** and **C).**

Since the penile skin is not undermined but deepithelialized, rolled in, and incorporated in the reconstruction, there is a tendency for there to be skin tension after a repair, especially during spontaneous nocturnal penile tumescence.

FIG. 23-11. We induce an artificial erection after the repair to evaluate skin tension and the potential for strangulation leading to ischemia. Relaxing incisions in the dorsal skin on the opposite side to the urethroplasty decrease this circumferential tension. Small 1 to 2 mm incisions *(1)* are preferable to large ones *(2).* These incisions heal spontaneously.

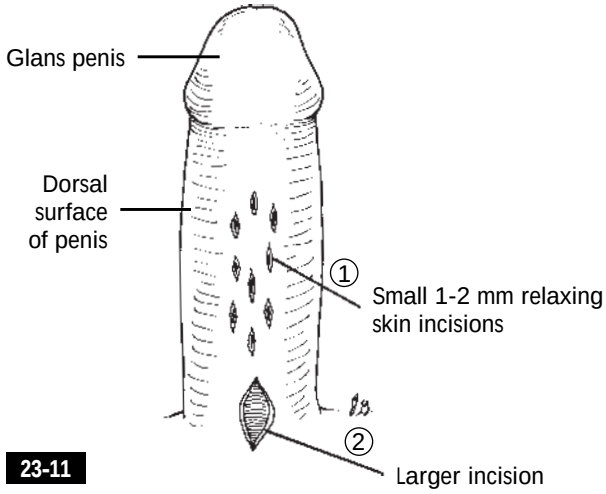

23-11

EXPERIENCE WITH TWO-STAGE URETHROPLASTY USING DEEPITHELIALIZATION TECHNIQUE

We have used the deepithelialization technique in one case of two-stage urethroplasty in which the entire urethra was strictured from the meatus all the way to the proximal bulbous urethra. This description illustrates the versatility and usefulness of the deepithelialization technique as an adjunct to complex urethroplasty.

First Stage

FIG. 23-12. Because the stricture involved the entire urethra, a complete urethrotomy was performed from the meatus to the proximal bulbous urethra **(A).** This maneuver essentially bivalved the scrotum.

The scar tissue surrounding the urethral stricture was excised.

The remaining plate of urethra was stitched to the corporeal bodies to flatten it and then approximated to the adjacent penile and scrotal skin **(B).**

For the stricture involving the posterior urethra, a dropback maneuver was used. The scrotum was stretched posteriorly with the testicles and the scrotal skin was then sutured to the posterior urethral plate (see pp. 224-225).

During an observation interval of 6 months, two epilations were performed to remove hairs and several dilatations were necessary to break up mild strictures that occurred secondary to cross adhesions of the urethral plate. Testosterone cream was applied to the skin adjacent to the urethral plate from the penis to the scrotum to enrich the vascularity and soften the genital skin.

Total Urethroplasty for Complete Urethral Stricture—First Stage: Marsupialization of Urethra and Dropback Procedure

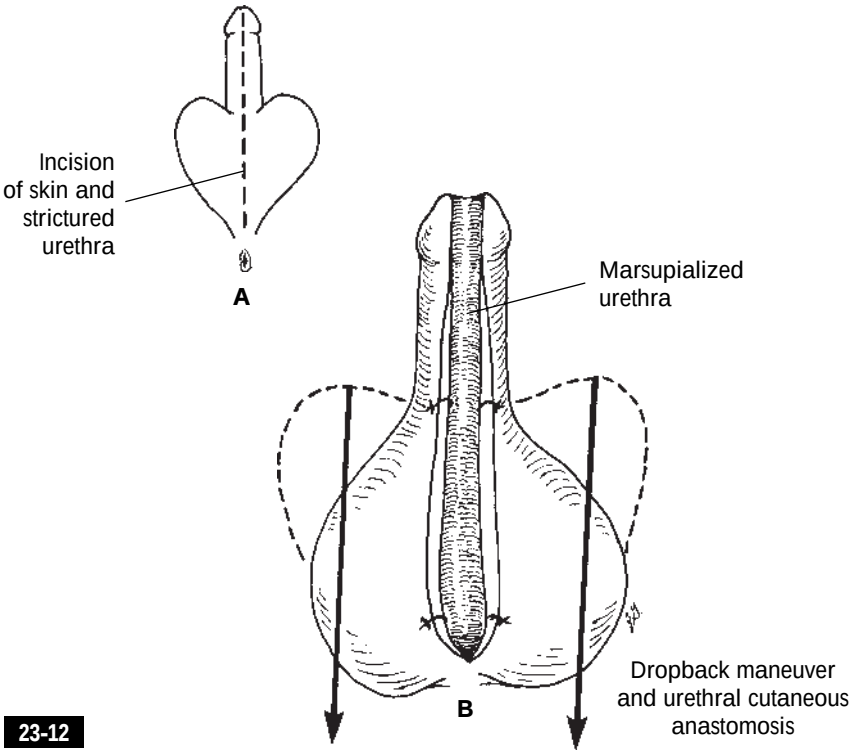

23-12

Second Stage

FIGS. 23-13, 23-14, AND 23-15. We selected the margins necessary to create a neourethra with a measured circumference equal to that of a 20 Fr catheter.

Instead of *undermining* the skin margin of the neourethra, we *deepithelialized* a plate of skin on both sides of the neourethra.

A neourethra was reconstructed *(1)*, and the adjacent deepithelialized dermis was approximated as a second-layer closure *(2)*. The compressive effect of this second layer is important in that it prevents the possible formation of a dead space and concomitant fluid collection.

Since *undermining* was not performed on either the skin adjacent to the neourethra or the lateral skin, the vasculature and lymphatics were intact. In contrast, undermined skin is used to cover the penis in Quartey's method[5] of urethroplasty (see Fig. 23-10), which thus introduces the risk of devascularization.

The skin edges were reapproximated *(3)*, and a suprapubic tube and a Silastic stent with open trough were placed for urinary and secretory diversion.[6]

Delayed Second-Stage Urethroplasty Closure with Deepithelialization

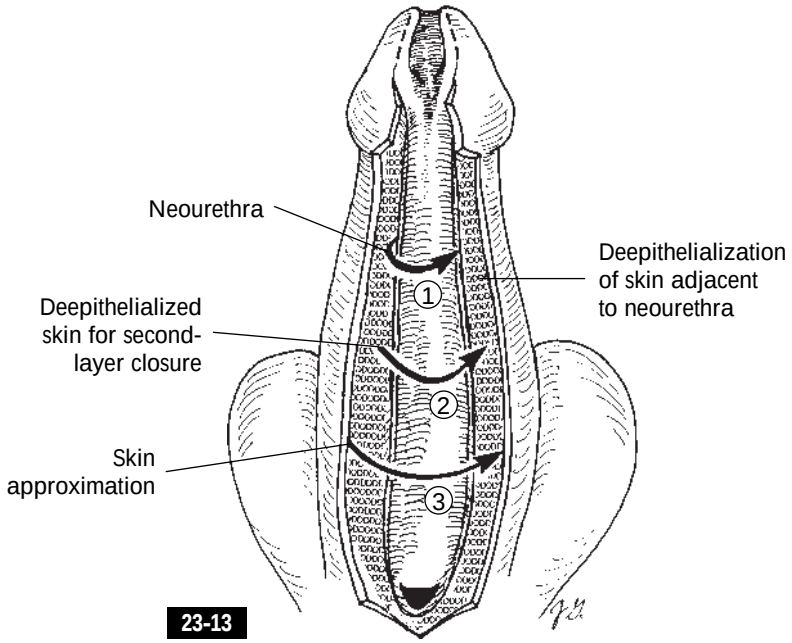

23-13

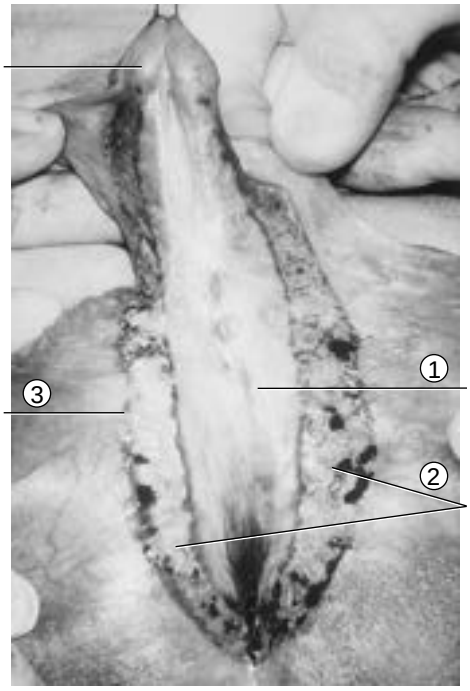
Glans penis
1
Tissue plate for neourethra
3
Skin margin
2
Deepithelialized areas

23-14

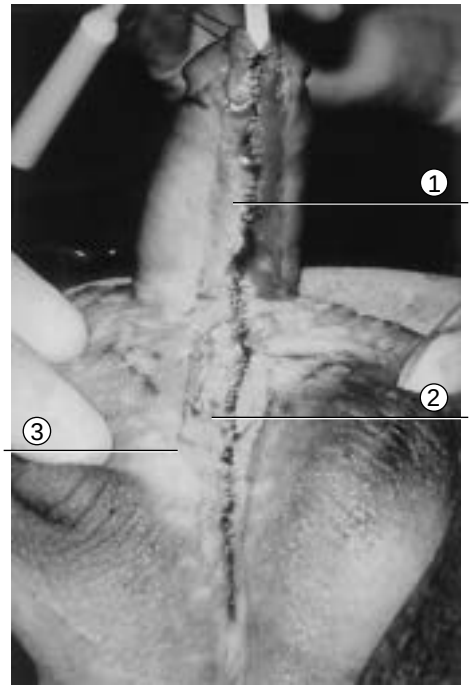
1
Neourethra
2
Deepithelialized dermis for the second-layer closure
3
Skin margin

23-15

REFERENCES

1 Belman AB: Deepithelialized skin flap coverage in hypospadias repair, *J Urol* 140:1273, 1988.

2 Smith ED: Deepithelialized overlap skin flap of the penis. In Strauch B, Vasconez LO, Hall-Findlay EJ, editors: *Grubb's encyclopedia of flaps*, Boston, 1990, Little, Brown.

3 Smith ED: Personal communication, February 1992.

4 Turner-Warwick R: Complications of urethral stricture surgery and some ways of preventing them. In Smith RB, Ehrlich RM, editors: *Complications of urologic surgery*, Philadelphia, 1990, WB Saunders, pp 435-457.

5 Quartey JKM: One-stage penile / preputial cutaneous island flap urethroplasty for urethral stricture, *J Urol* 129:284, 1983.

6 Mitchell ME, Kulb TB: Hypospadias repair without a bladder drainage catheter, *J Urol* 135:321, 1986.

SUGGESTED READINGS

Geltzeiler J, Belman AB: Results of closure of urethrocutaneous fistulas in children, *J Urol* 132:734, 1984.

Kass EJ, Bolong D: Single-stage hypospadias reconstruction without fistula, *J Urol* 144:520, 1990.

Smith ED: A deepithelialised overlap flap technique in the repair of hypospadias, *Br J Plast Surg* 26:106, 1973.

Smith ED: Treatment of hypospadias. In Whitehead ED, editor: *Current operative urology*, Philadelphia, 1989, JB Lippincott.

24

Problems and Variations in the Placement of the Three-Component Inflatable Penile Prosthesis

Troubleshooting for the Malfunctioning Prosthesis

Although there are ongoing changes in the design of penile prostheses, we believe there remain basic surgical considerations that are universal and applicable to all penile prosthesis surgery. We have chosen to discuss the more complex three-component prosthesis to illustrate all possible problems.

IDENTIFICATION OF PROXIMAL URETHRA AND CORPORA CAVERNOSA

FIG. 24-1. After the bladder is emptied by catheterization, an incision at the penile scrotal junction is made over the median raphe extending 4 to 5 cm.

A 22 Fr Van Buren sound is passed into the urethra to facilitate identification of the urethra and the corpora on both sides of the urethra. The surgeon should dissect down to the corpus spongiosum surrounding the urethra and then laterally on either side of the corpus spongiosum to

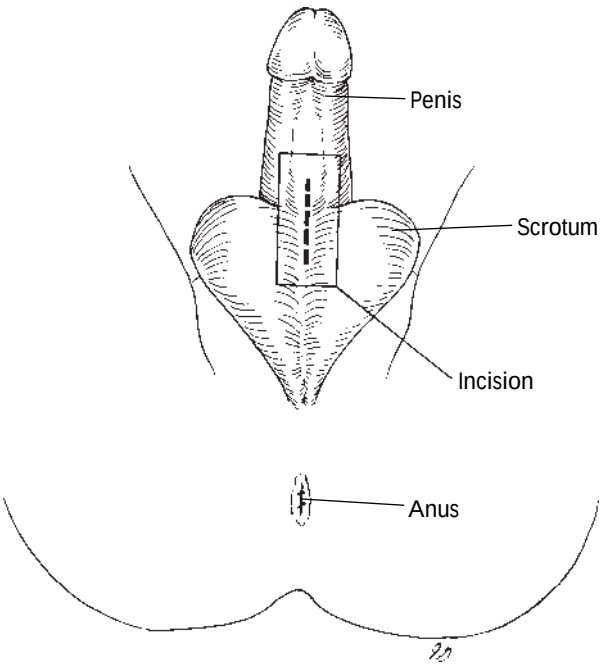

24-1

identify the corpora cavernosa. This dissection defines a clear border between the urethra and corpora cavernosa, thus preventing injury to the urethra during the operation.

An artificial erection can be induced by injecting saline solution with prostaglandin E_1 (20 µg) into a corpus cavernosum for full vasodilation while a tourniquet is applied around the base of the penis. This maneuver will allow the surgeon to estimate erect penile size, diameter, curvatures, and fibrotic plaques and will thus facilitate subsequent corporeal dissection and dilatation.

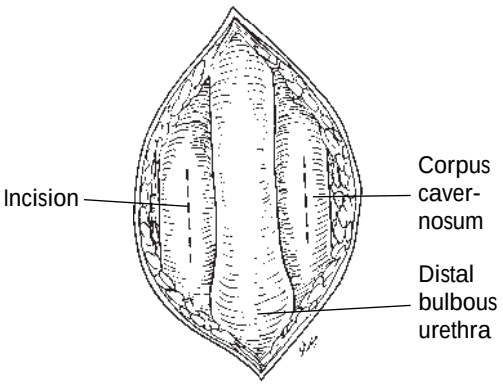

24-2

CORPOREAL INCISION AND DILATATION

FIGS. 24-2, 24-3, AND 24-4. A vertical corporeal incision of 4 cm is made between two traction sutures (0 Prolene) at the 6-o'clock position. The incision should be as proximal as possible and parallel to the urethra.

FIG. 24-5. If the incision is too distal, the surgeon will have difficulty inserting the proximal prosthesis, especially with rear-tip extenders, and the tubing may be pressed against the cylinder wall. Even with the protective sheath over the tubing, the constant pressure over time may cause the cylinder walls to erode.

If the incision is too proximal, the surgeon will have difficulty with distal cylinder insertion and with closure of the corporotomy.

FIG. 24-6. The surgeon first establishes a dissection plane between the most lateral corporeal tunica and sinus bodies using long scissors in a forward-and-backward spreading motion. This dissection technique not only avoids the urethra and the median septum but also preserves as much as possible the sinus endothelium and the cavernosal artery. Preservation of the vascular architecture, even when diseased, enhances the quality of later erections.

FIG. 24-7. After the initial scissors dissection, the space between the corporeal tunica and sinuses is dilated with Hegar size 7 to 13 dilators in preparation for cylinder placement. We prefer to dilate the corpus cavernosum to the size of a size 13 dilator because it makes the cylinder placement easier.

FIGS. 24-8 AND 24-9. The dilatation should extend to the most distal end and reach the most proximal end at the crus. When distal dilatation is incomplete, the surgeon may find a glandular droop "SST syndrome" after placement of the cylinders.

Cross-sectional View

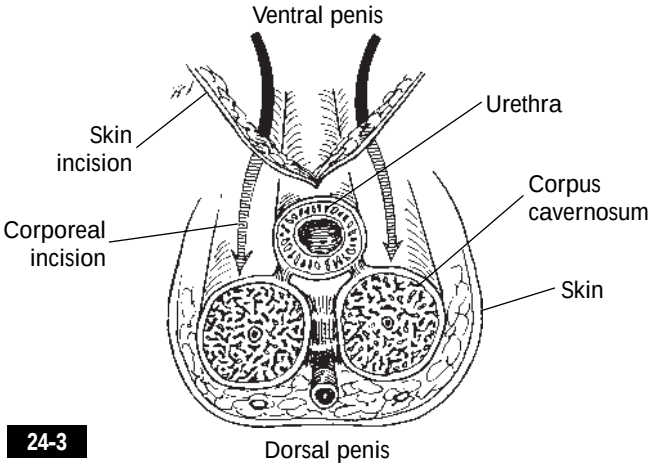

24-3

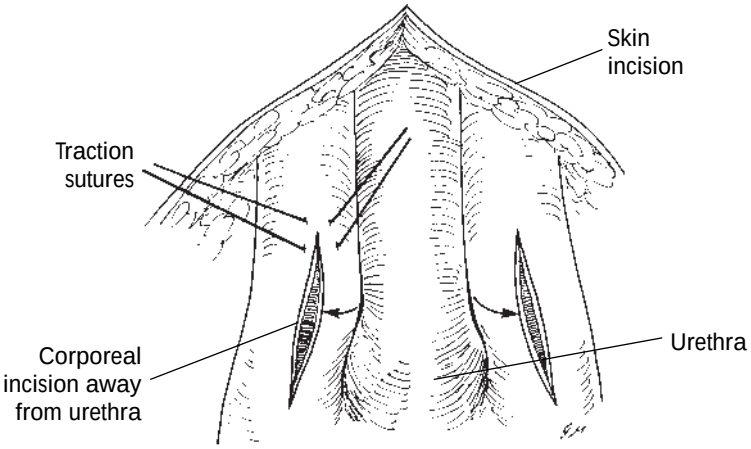

24-4

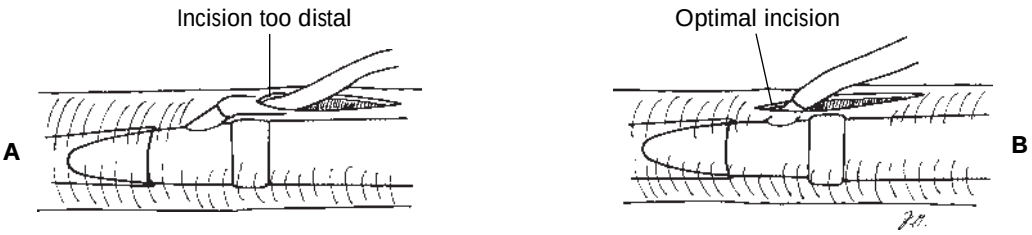

24-5

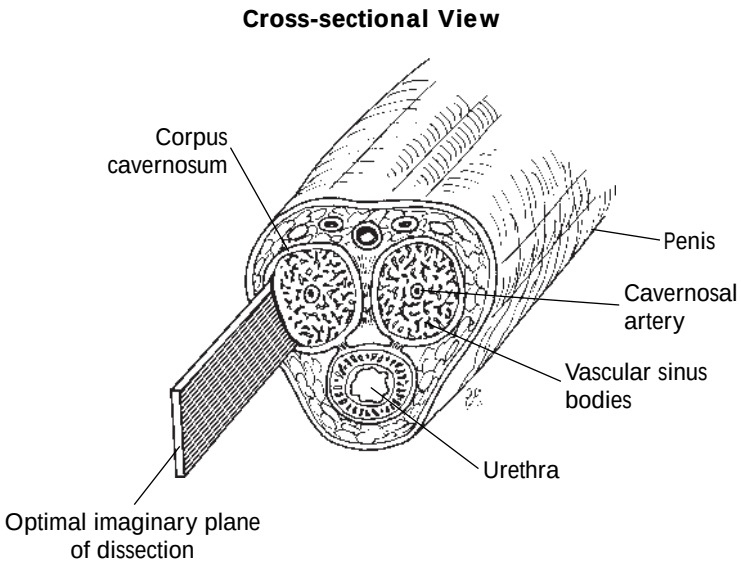

24-6

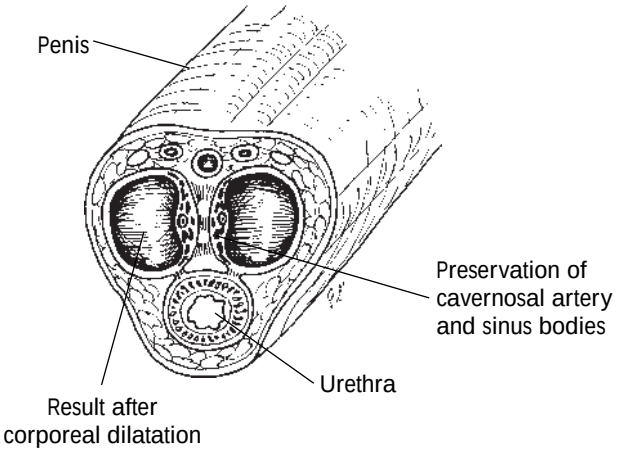

24-7

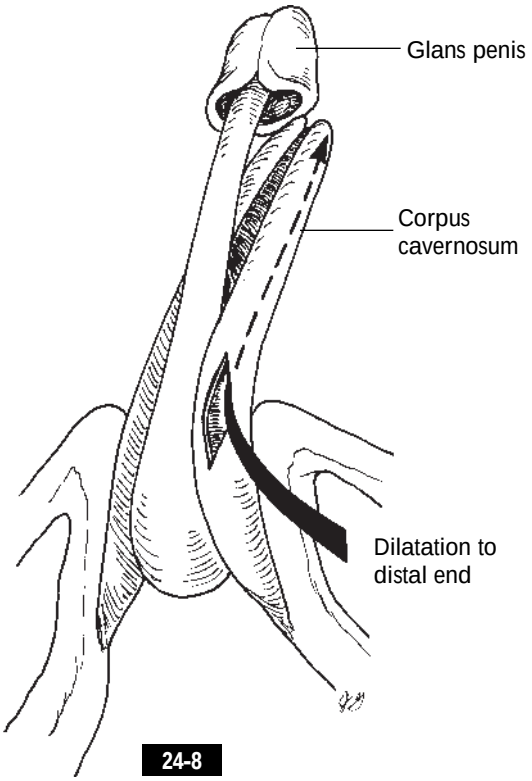

24-8

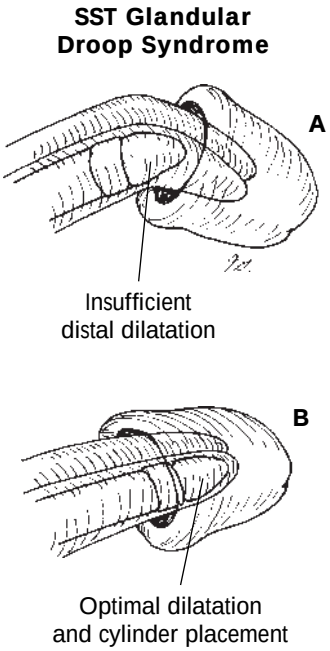

24-9

CYLINDER SELECTION AND INSERTION

We use the American Medical Systems (AMS, Minneapolis, Minn.) inflatable penile prosthesis, which is representative of the generic type of three-component prosthesis.

FIG. 24-10. After the measurements of both cylinder lengths are made, the surgeon has the choice of using three different cylinder sizes (12, 15, or 18 cm) with three different-sized rear-tip extenders (RTE) and two different-sized reservoirs. The shortest rear-tip extenders are placed against the cylinder *first*. For example:

1. 15 cm cylinder 1 cm RTE 2 cm RTE 18 cm (65 ml reservoir)
2. 18 cm cylinder additional RTE if needed >18 cm (100 ml reservoir)

The 12 and 15 cm cylinders always require the 65 ml reservoir, whereas the 18 cm cylinder requires the 100 ml reservoir.

The most common corporeal lengths range from 18 to 20 cm; the 15 cm cylinder is most commonly selected.

The ideal situation is for the inflatable portion of the cylinders to lie within the corpora cavernosa of the penis and the rear-tip extenders to fill the spaces of the two crura.

SPECIFIC DIFFICULTIES IN CYLINDER PLACEMENT

Fibrosis of the corporeal bodies secondary to treatment for priapism from Peyronie's disease, injections, and diabetes can complicate dilatation and cylinder placement.

Distal Corpora Cavernosa

FIG. 24-11. Even with complete dilatation of the distal corpora cavernosa and proper placement of the prosthesis, natural anatomic variation may still result in a drooping glans penis.

In this case a horizontal incision around the base of the glans penis is made, exposing the dorsal nerves, glandular tissues, and distal corporeal bodies. The surgeon should place two stitches approximating the glandular tissues to the corpus cavernosum just lateral to the dorsal nerves to correct the drooping glandular configuration.

FIG. 24-12. When dilating the distal corpora cavernosa, the surgeon may encounter a common problem of mild fibrotic webbing in diabetic patients **(A).** Usually this fibrotic web can be broken up by simply dilating the corporeal tract.

In cases of more severe scarring, such as with Peyronie's disease, an incision or excision with

AMS Inflatable Penile Prosthesis with Rear-Tip Extenders

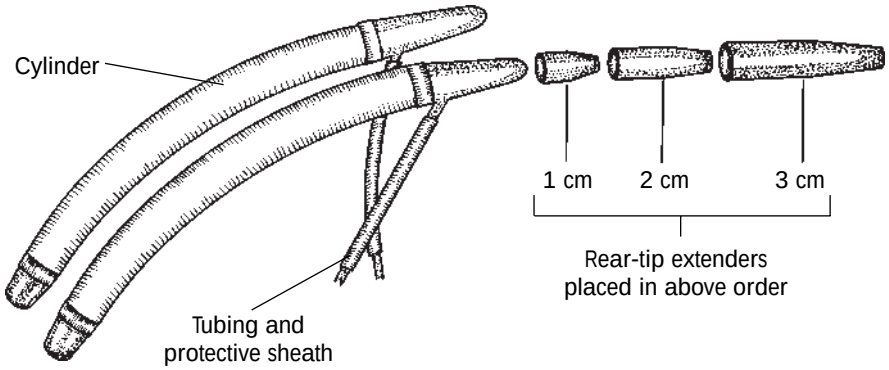

24-10

a replacement graft may be necessary **(B).** We prefer to use a nonexpandable model (CX model; American Medical Systems) for the prosthesis of choice in this situation.

In the dilatation of the fibrotic distal corpus cavernosum, the surgeon may perforate the corporeal tissue and enter the urethra at the fossa navicularis **(C).** The surgeon may still place the cylinder in the intact contralateral corpus cavernosum but should postpone further manipulation of the affected side until a later date.

Aggressive dilatation may also lead to perforation of the distal corporeal body at the glans penis **(D).**

Correction for Natural Glans Penis Droop

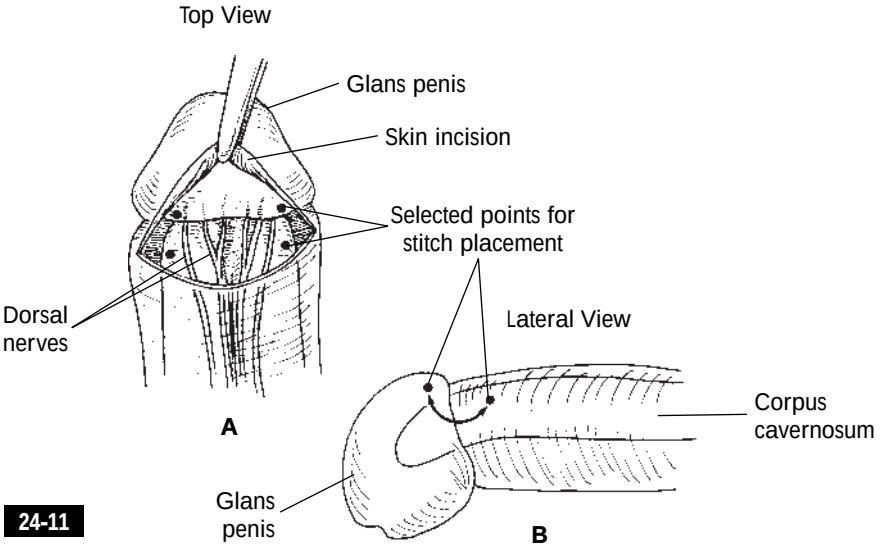

24-11

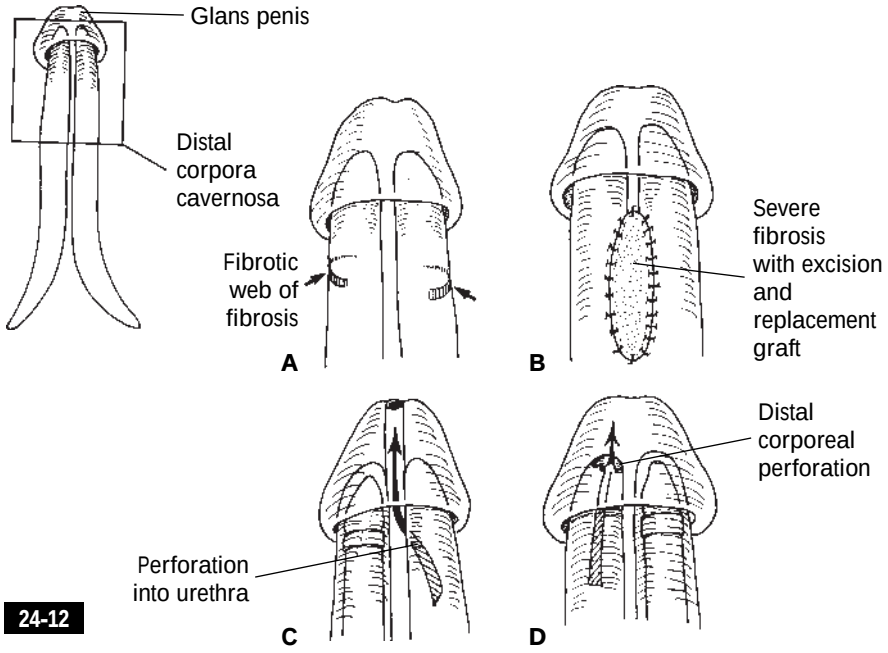

24-12

FIG. 24-13. The primary closure of a perforation is neither effective nor satisfactory. A Dacron "windsock" graft anchored to the corpus cavernosum walls is the only acceptable alternative for primary repair after a distal perforation.[1] The windsock graft should be stitched to the corporeal walls such that the prosthetic cylinder tip matches the contralateral tip.

Another alternative is to postpone any further manipulation for 3 to 6 months and then redilate the corporeal body.

Proximal Corpora Cavernosa and the Crura

For fibrosis of the proximal corpora cavernosa and atrophy of the crura, corrective surgical maneuvers are easier.

FIG. 24-14. If there is a fibrotic narrowing of the crus such that the rear-tip extenders cannot be placed within, the easiest solution is to place a running plication stitch proximally to obliterate the narrowed space **(A).** This stitch ensures that proximal migration of the cylinder will not occur.[2]

Perforation of the proximal crus from aggressive dilatation **(B)** or atrophy of the crus **(C)** requires additional maneuvers. A Dacron windsock graft or a Dacron or Gore-Tex sleeve (2 mm thickness) with a closed blunt end can be anchored to the corpus cavernosum more distally **(D)** and even anchored to the periosteum of the pubic ramus **(E).**[1,3]

Dacron "Windsock" Graft for Repair of Distal Corpus Cavernosum Perforation

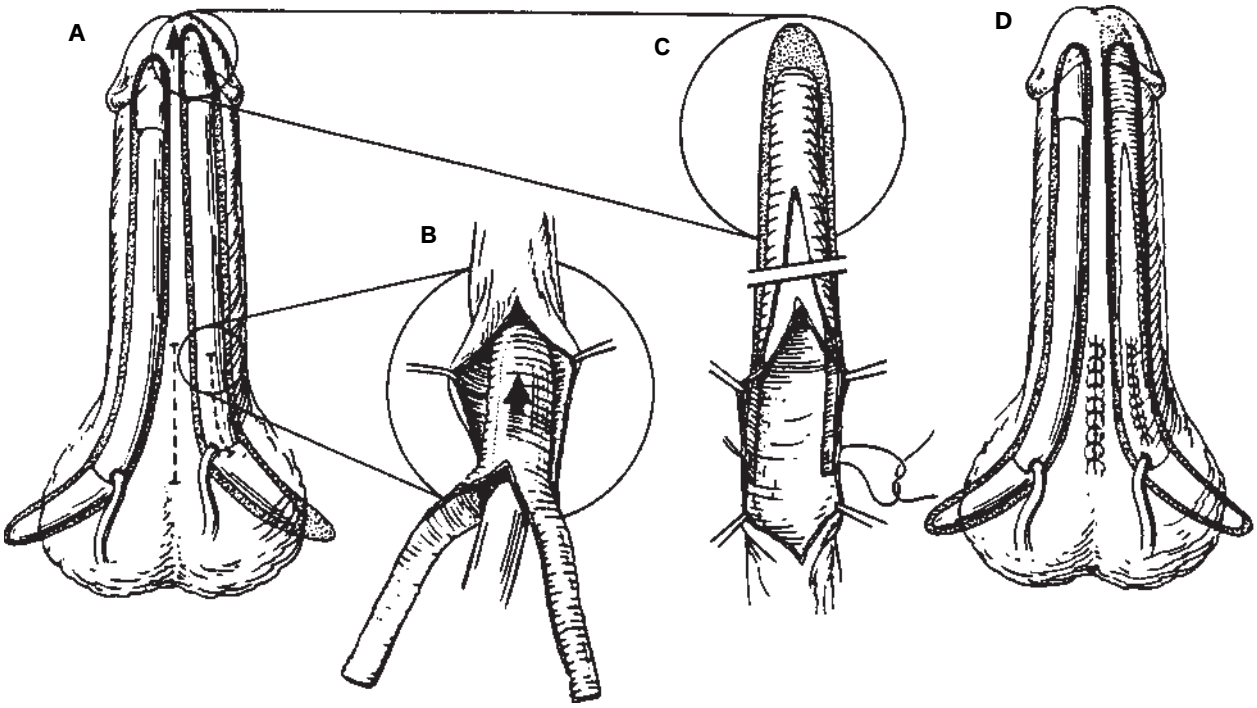

From Fishman IJ: *Contemp Urol* 51, 1991.

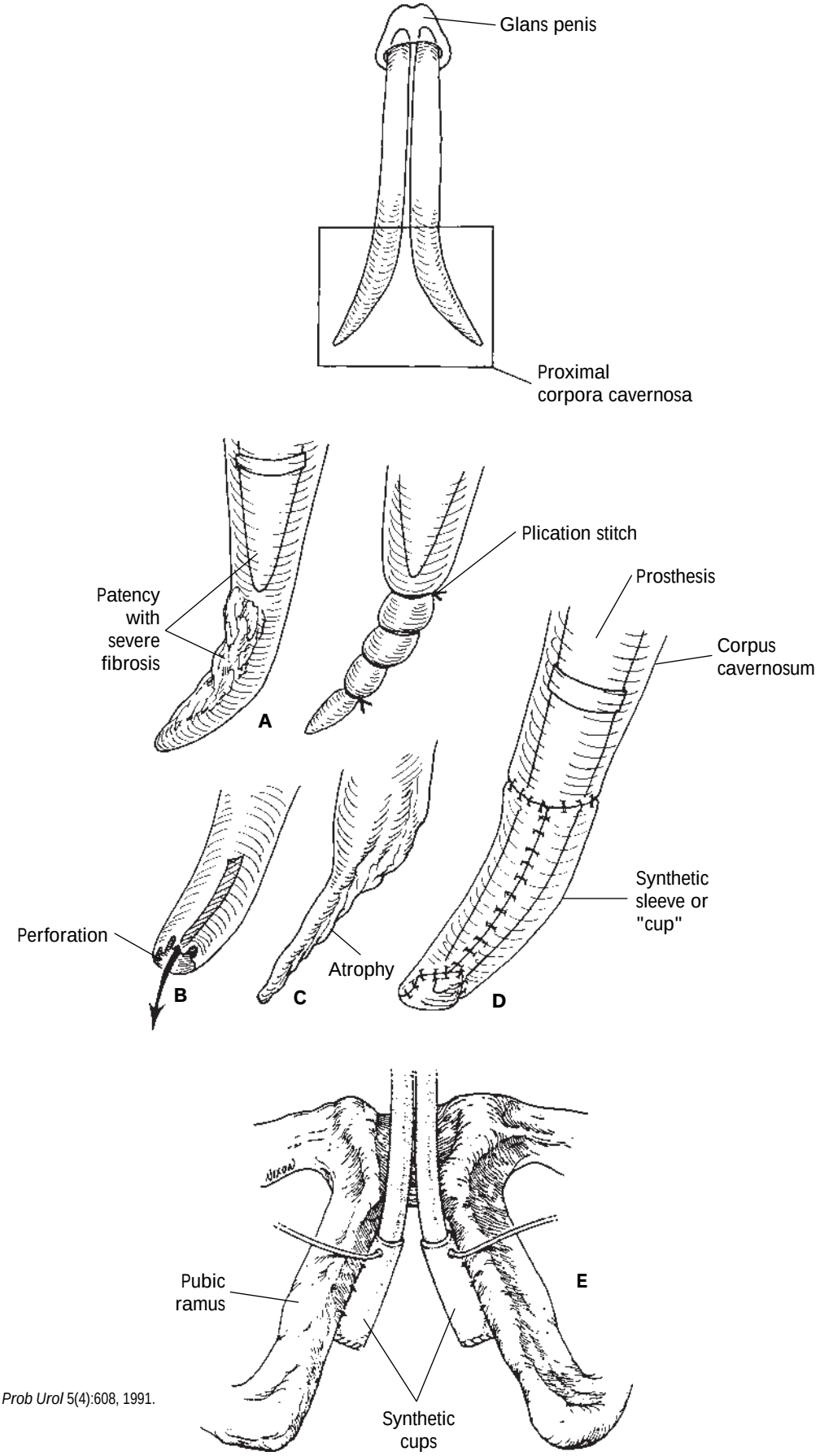

E from Mulcahy JJ: *Prob Urol* 5(4):608, 1991.

FIG. 24-15. When there is a disruption of the median septum, the surgeon may have difficulty with dilatation and subsequent cylinder placement in the proper corporeal body. By first establishing the correct space for one side and inserting a Hegar size 8 dilator within, the surgeon can dissect and then dilate the opposite side and establish a proper compartment for cylinder placement. The cylinder should be placed while the Hegar dilator is still within the opposite corporeal body. Once one cylinder is in place, the other cylinder replaces the Hegar dilator.

FIG. 24-16. An aneurysm of the corpus cavernosum may be resected, and nonexpandable cylinders (e.g., CX model; AMS) may be inserted.

FIG. 24-17. Once the cylinders have been placed, the surgeon should check for any filling difficulties or any "buckling" effect of the cylinders. Buckling suggests that either the cylinder is too long or the diameter of the corpus is too narrow for the selected cylinder.

The 12 cm cylinders have a noninflated diameter of 8.5 mm and the 15 and 18 cm cylinders have a noninflated diameter of 10.5 mm, which can be expanded to 18 mm or greater.

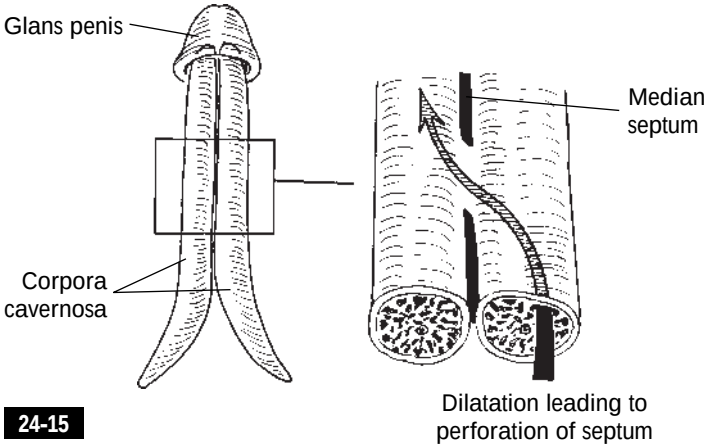

24-15

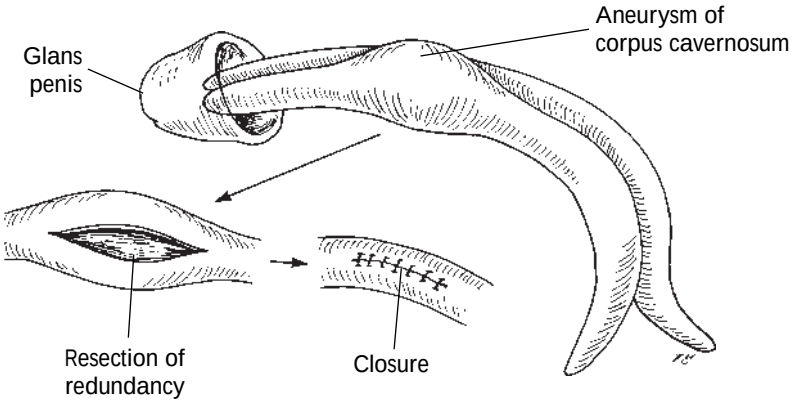

24-16

Buckling of Prosthesis

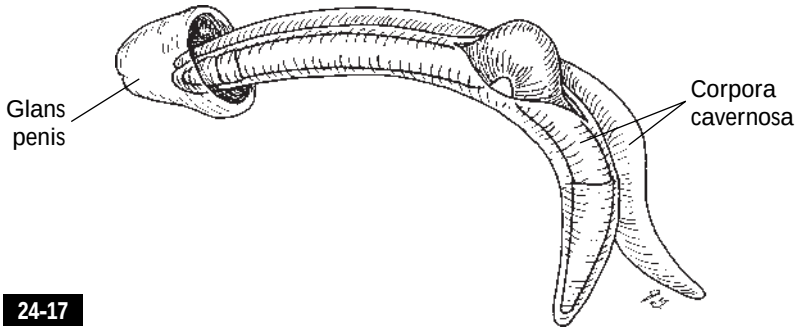

24-17

RESERVOIR PLACEMENT
Inguinal Approach

FIGS. 24-18 AND 24-19. If the patient is right-handed, the surgeon should approach the retropubic space through the right inguinal ring, applying traction on the right scrotum, testis, and spermatic cord laterally with the left hand. The surgeon inserts the right index finger adjacent to the spermatic cord through the external inguinal ring and to just lateral to the junction of the rectus abdominis muscle and the pubic bone.

FIGS. 24-20 AND 24-21. Once the surgeon has palpated the space, an 8 cm–long nasal speculum (Killian), with the handles facing up, is passed adjacent to the surgeon's index finger by the assistant.

Reservoir Placement

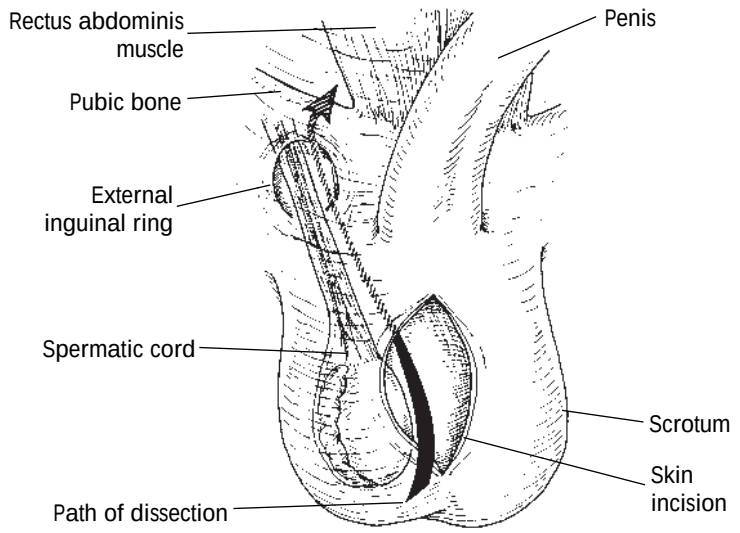

24-18

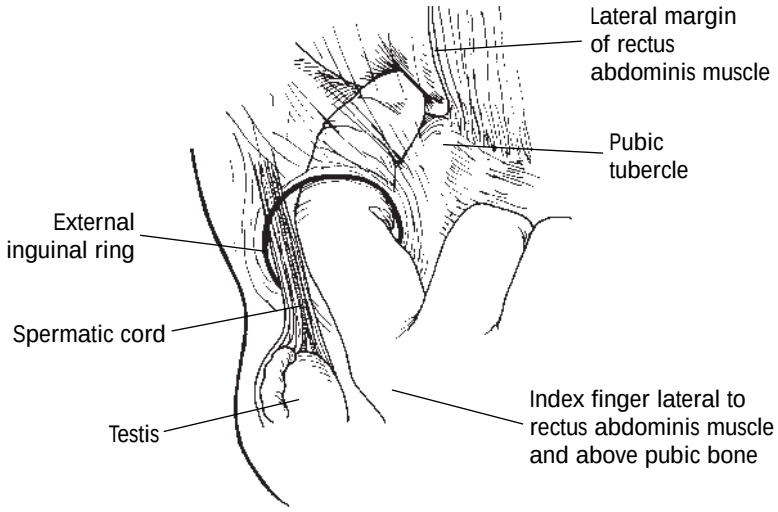

24-19

Long Nasal Speculum

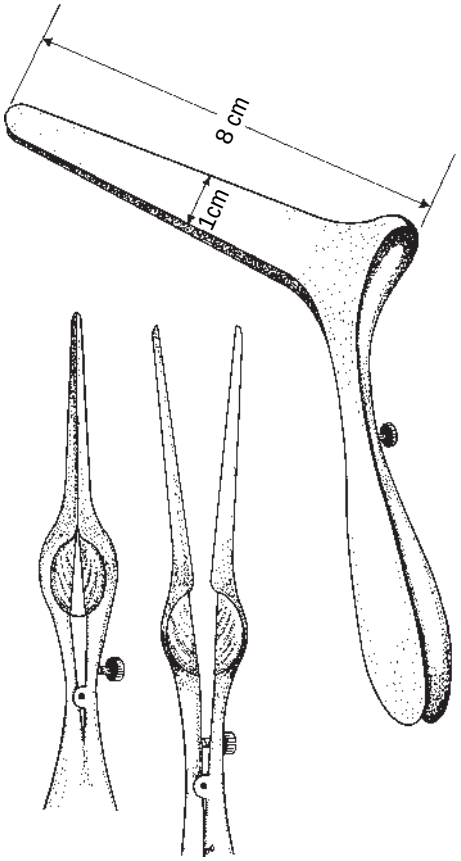

24-20

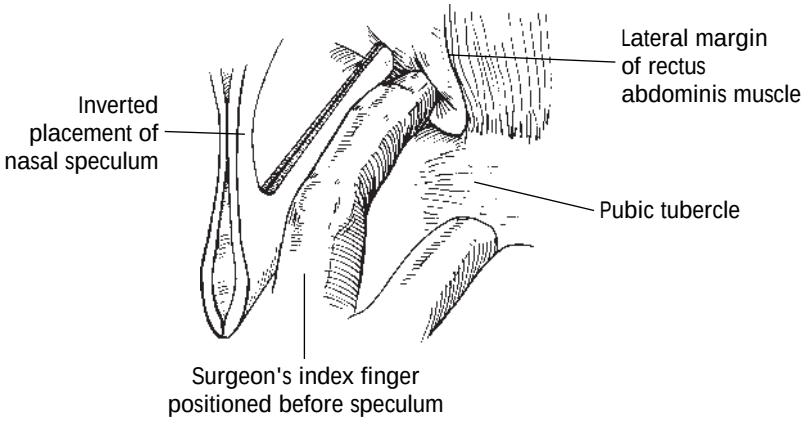

24-21

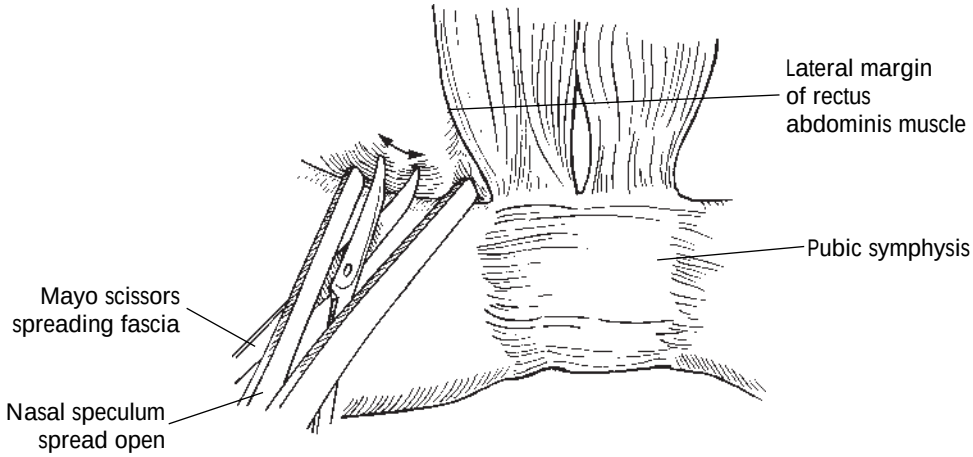

24-22

Dissection for Reservoir Placement

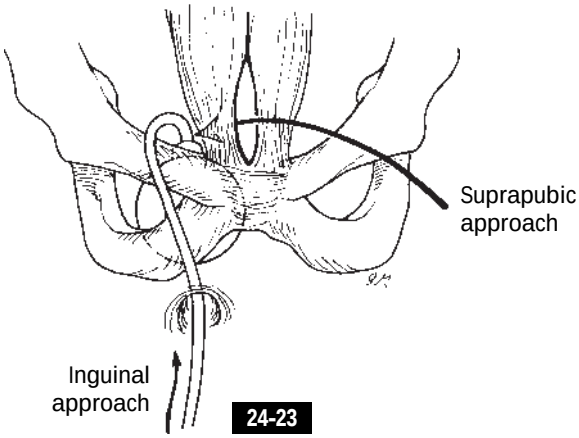

24-23

FIG. 24-22. After the speculum is spread by the assistant, the surgeon passes long Mayo scissors between the spread speculum wings and spreads these dense fascial layers to enter the retropubic space. The bladder should be drained before this maneuver.

Once the dense tissues are open, the surgeon reinserts the right-hand fingers and slides them into the retropubic space for reservoir placement.

After bluntly dissecting a space adjacent to the bladder with the fingers, the surgeon places the reservoir in the space (65 ml for 12 and 15 cm cylinders or 100 ml for 18 cm cylinders). If there is spontaneous efflux of saline solution into the syringe after initial inflation of the reservoir, then the space is too small and requires further blunt dissection.

Suprapubic Approach

FIG. 24-23. In patients who have had previous inguinal hernia surgery or who have a weakness of this area due to previous surgery, a suprapubic approach for reservoir placement, with the tubing coming over the pubis into the scrotum, is the safest method.

Previous radical retropubic prostatectomy or open prostatectomy with severe fibrosis may require that the reservoir be placed in the peritoneal cavity.

PUMP PLACEMENT

FIG. 24-24. The pump is placed in the scrotum with the reservoir tubing in a lateral position and the two cylinder tubings in a medial position. When the patient is standing, the pump should be in a vertical position. Excessive scrotal dissection sometimes leads to a horizontal and posterior placement of the pump. This horizontal pump placement makes it difficult for the patient to deflate the prosthesis.

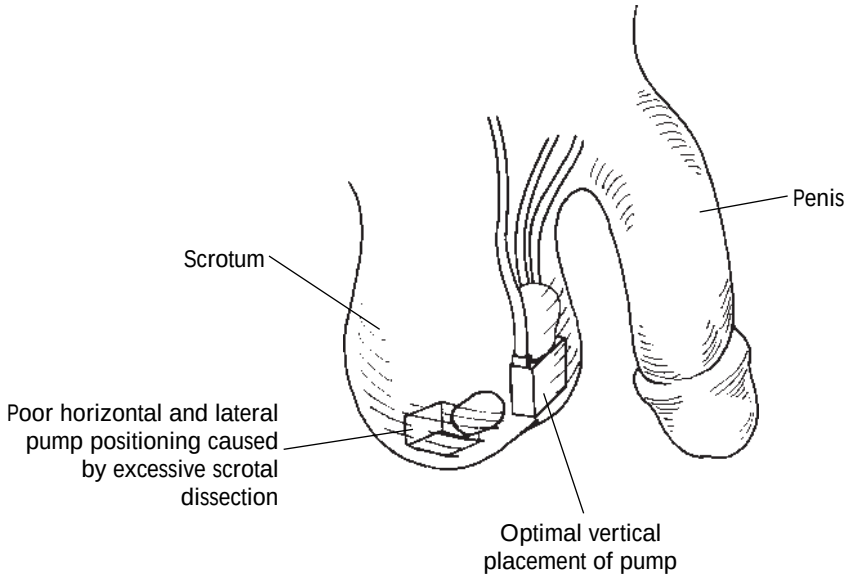

24-24

If the tubes are not already connected, the "quick-connect" system is used for the three components.

ANTIBIOTIC ADMINISTRATION AND DRAIN PLACEMENT

Bacterial infection is the worst complication with any kind of prosthetic surgery whether a penile prosthesis or an artificial knee. Aside from strict sterile technique and preferably an early morning case-scheduling, the surgeon should be generous with the use of antibiotic solutions for irrigation during the operation. A typical irrigating solution is 50,000 U bacitracin and 1 g neomycin or kanamycin in 1 L solution.

Preoperative and postoperative antibiotic administration is important for the assurance of a successful outcome. Antibiotic administration should be continued until after the drain and Foley catheter are removed.

A Jackson-Pratt or Blake suction drain can be left adjacent to the tubings for 24 hours postoperatively if the dissection has been extensive. A Foley catheter (16 Fr) is left in place for 24 to 48 hours postoperatively.

TROUBLESHOOTING AND REVISION OF THE MALFUNCTIONAL PROSTHESIS

Incision

A superficial penile-scrotal incision is made over the tubing of the prosthesis.

By using electrocautery to divide the scar tissues over the prosthesis, the surgeon will not injure the prosthetic material even when dividing tissues directly over the prosthesis.

A Van Buren sound (22 Fr) placed in the urethra gives the surgeon a palpable landmark to avoid while searching for the prosthetic tubing, thus preventing injury to the urethra.

The two tubings medial to the urethra are from the cylinders, and the single lateral tubing is from the reservoir.

Sequential Testing

FIG. 24-25. The surgeon first identifies the cylinder tubings because they are the most common site of leakage. When the scar tissue over the tubing is divided, a sudden release of prosthesis fluid should make the surgeon suspect a regional leak. The leaking can occur on either side of the tubing connection *(1)* or where there is excessive tubing redundancy.

If no leakage is identified, the surgeon should trace both tubings to the cylinders. By making a small corporotomy, the surgeon can examine another site of potential leakage. The sleeve around the tube protects it; however, if the placement of the tubing is in contact with the cylinders within the corporeal body, there is a potential for damage to the cylinder as well as to the tubing *(2)*. Although cylinders now have extra reinforcement, the long-term compression of the tubing against the cylinder may lead to erosion and laceration of the cylinder.

If the corporotomy does not reveal an obvious leak, the next step is to divide the reservoir tubing *(3)* and place a 60 ml syringe filled with saline solution to the pump end of the tubing.

By inflating the cylinders using the scrotal pump, the surgeon should be able to identify any malfunctions of either the cylinders or the pump. When the cylinders are deflated, the syringe should receive an equal volume of saline solution as used in the inflation.

If there is a malfunction detected by performing the above maneuver, the surgeon should divide the tubing to the cylinders *(4)* and connect two syringes filled with saline solution to each of the two tubes and inflate the cylinders. Malfunctions are more commonly found in the cylinders and are rarely found in the pump.

Depending on the findings, either the cylinders or the pump must be replaced *(5)*.

Reservoir

If the pump and cylinders plus tubings are all intact, the surgeon connects an empty large syringe to the reservoir.

The reservoir should return approximately 65 or 100 ml. Depending on the previous operative notes indicating the cylinder size, the surgeon should know whether it is a 65 or 100 ml reservoir.

By instilling either 65 or 100 ml, the surgeon should be able to draw back the exact same amount of fluid.

If the surgeon can instill the saline solution but there is a spontaneous efflux into the syringe, the fibrous capsule needs to be "recracked" and established by saline solution reinfusion.

FIG. 24-26. If there is a questionable malfunction, our preference has been to leave the reservoir and place another one from a suprapubic approach.

The removal of a reservoir not only is difficult but also requires excessive tissue dissection and is not worth the time spent. The inert empty reservoir will not cause any problems.

After the reservoir is emptied, the reservoir tubing is cut at the most distal end.

The new reservoir is placed in the perivesical or retropubic space via a separate suprapubic incision, and the tubing is placed over the pubic bone and tunneled through the subcutaneous tissues down into the scrotum.

Troubleshooting for Malfunctional Prosthesis

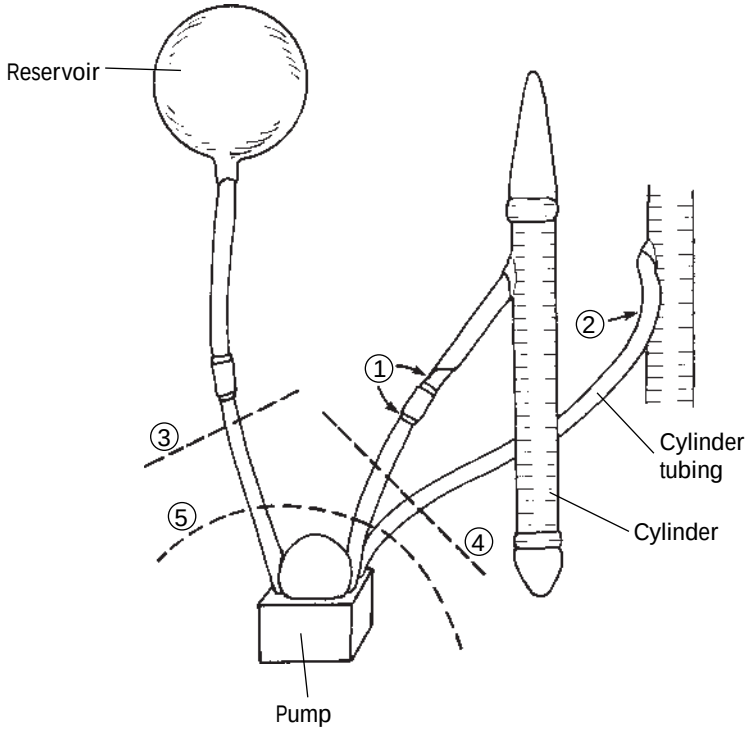

24-25

Suprapubic Placement of Reservoir (Lateral View)

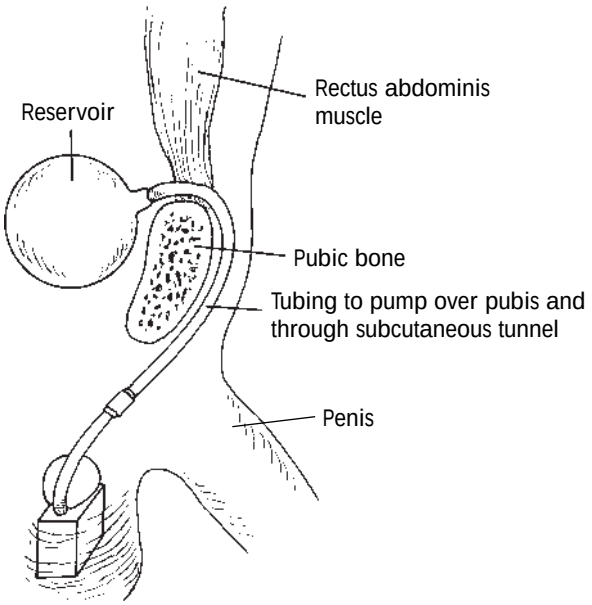

24-26

KEY POINTS

- Erection is induced to estimate erect penile size and evaluate for possible fibrosis.
- The urethra and corpora cavernosa are identified before the corporeal incisions are made. Traction stitches are placed and a 6-o'clock proximal incision between these stitches is ideal for cylinder placement.
- Lateral dissection between the corporeal tunica and sinuses is performed with Hegar size 7 to 13 dilators; the corporeal sinuses and the cavernosal artery are preserved.
- Cylinder size and corresponding reservoir are selected (12 and 15 cm cylinder, 65 ml reservoir; 18 cm cylinder, 100 ml reservoir). The shortest rear-tip extenders are placed first, next to the proximal cylinder.
- Fibrosis, if present, is corrected.
- An inguinal approach is used for the reservoir placement. In patients who have had previous hernia or organ surgery, a suprapubic approach is appropriate. The reservoir can be placed in the peritoneal cavity if scarring in the retropubic space is severe.
- The pump should be placed in the vertical position.
- The cylinders are inflated to 50%. The drain and Foley catheter are left in place for 24 hours postoperatively.

POTENTIAL PROBLEMS

- *Injury to urethra:* Place cylinder in unaffected side only → postpone cylinder placement in affected side
- *Atrophied crus:* Ligate crus and use cylinder without rear-tip extenders or select a shorter cylinder → alternatively, use a Gore-Tex or Dacron sleeve graft
- *Septal disruption:* Continue dilatation of corpora cavernosa
- *Improper cylinder inflation or buckling:* Check for improper cylinder length or diameter → check for fibrosis with a narrow corporeal diameter
- *Aneurysm of corpus cavernosum:* Correct the aneurysm and select a nonexpandable prosthesis
- *Bladder is punctured while creating reservoir:* Place reservoir in the peritoneal cavity

REFERENCES

1 Fishman IJ: Complicated implantation of inflatable penile prosthesis, *Urol Clin North Am* 14(1):217, 1987.

2 Palma PCR, Netto NR Jr: Ligation of crura penis for corporeal length adjustment in cases of short rod-like penile prosthesis, *J Urol* 143:764, 1990.

3 Mulcahy JJ: The management of complications of penile implants, *Prob Urol* 5(4):608-627, 1991.

SURGERY FOR PEYRONIE'S DISEASE

25

PEYRONIE'S DISEASE WITHOUT IMPOTENCE

Exposure and Mobilization of Dorsal Nerves and Vessels

FIG. 25-1. Most surgeons use a degloving procedure via a circumferential skin incision around the base of the glans penis for exposure. Although this technique is a convenient way to dissect the penile skin, some patients complain of decreased sensation after surgery despite the preservation of the dorsal nerves.

FIG. 25-2. An alternative is to use a vertical incision, which parallels the plaque from the base of the glans penis to the base of the penis, and to dissect only the skin sufficient for exposure of the nerves and plaque.

The dissection and mobilization of the dorsal nerves and vessels are much easier if the penis is erect. The tension of the corporeal bodies provides strong backing for a clear margin of dissection.

An artificial erection is induced either by a constant saline solution infusion into the corpora cavernosa or a prostaglandin E_1 injection (20 µg).

FIG. 25-3. The dorsal nerves are visible with the naked eye. The surgeon injects saline solution between the nerves and the erect corporeal bodies to facilitate the sharp dissection to separate the nerves from the adjacent tissues.

The surgeon uses a pair of tenotomy scissors and begins the dissection laterally, working from each side and connecting in the midline.

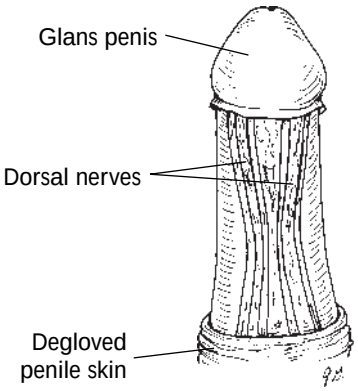

25-1

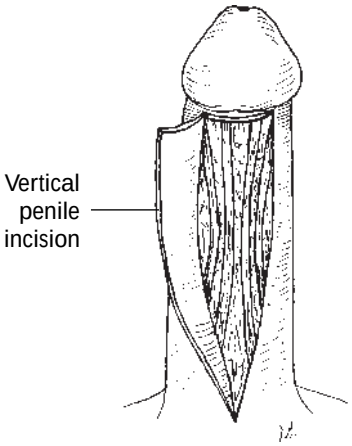

25-2

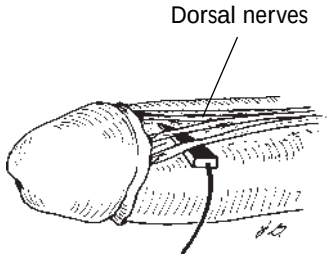

25-3

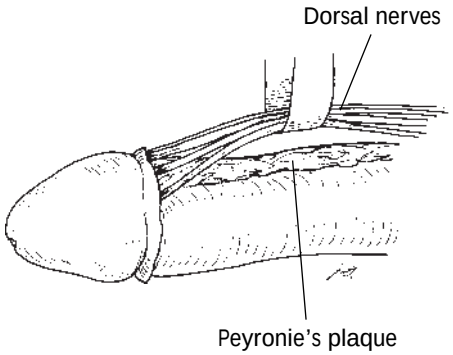

25-4

FIG. 25-4. The dorsal nerves can be retracted cephalad with a small Penrose drain while the surgeon continues the dissection distally and proximally.

FIG. 25-5. Often, after the dorsal nerves and tissues have been mobilized from the penile shaft, the plaque seems smaller than expected. By visual inspection and finger palpation of the erect penis, the surgeon can define the boundary of this fibrotic process.

FIG. 25-6. The surgeon's strategy is to perform the minimal amount of manipulation necessary to correct the fibrotic curvature. Although most patients require more intervention, there are times when a Nesbit plication stitch or a small incision with or without a graft replacement is sufficient to correct the problem.[1]

FIG. 25-7. In other patients in whom there is severe curvature with involvement of the midline septum, the surgeon must excise the plaque.

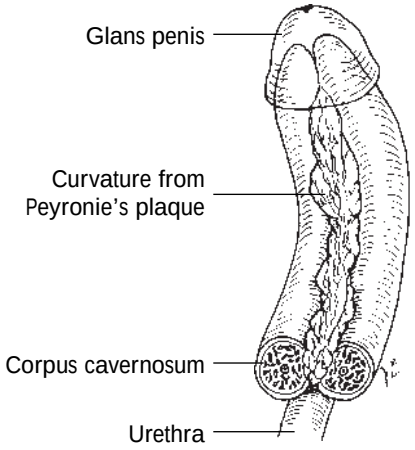

25-5

Correction of Curvature by Plication

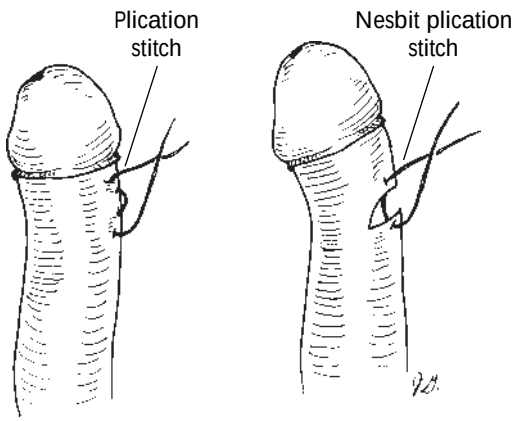

25-6

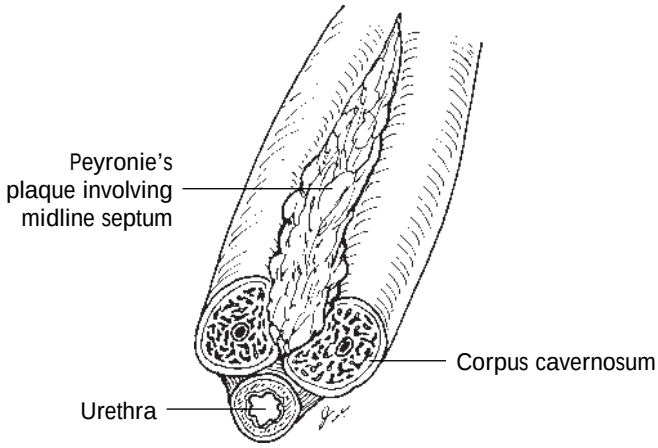

25-7

Primary Excision

A tightened tourniquet around the base of the penis will prevent excessive venous back-bleeding once the corporeal incision is made. Dabbing the corporeal sinuses with a sponge soaked in an epinephrine solution (1:100,000 dilution) will aid in maintaining a clear operative field.

With the combined use of a knife and tenotomy scissors, the surgeon first incises the lateral border of the plaque on one side.

With Allis clamps placed on the cut edge of the plaque, the surgeon can then free the sinus tissue from the plaque.

FIG. 25-8. When there is severe septal scarring, it is critical that the surgeon avoid any injury to the cavernosal arteries. By "hugging" the diseased tunica side with the scalpel during dissection, the surgeon shaves the sinus tissue off and preserves the maximal amount of the corporeal sinus tissue as well as the cavernosal artery.

If these two arteries are injured, the patient will be rendered impotent.

FIG. 25-9. Many variations of a Z-plasty reconstruction can be used to facilitate primary closure. A continuous stitch (3-0 or 4-0 PDS) is a watertight closure, and an interrupted stitch (2-0 PDS) at 2 cm intervals provides strength[2] **(A).**

At the completion of the primary corporeal closure, the girth of the penis is decreased. However, after replacing the bulk of the dorsal nerves and vessels and after reapproximating the penile skin, the narrowed girth will not be obvious. The functional result after surgery is quite satisfactory for most patients **(B).**

FIG. 25-10. If the plaque is superficial, in some cases a simple incision with graft replacement is sufficient to straighten the penis.[3]

Cross-sectional View

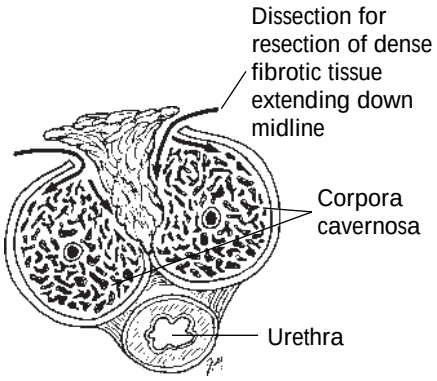

25-8

Excision with Primary Anastomosis (with Z-Plasty)

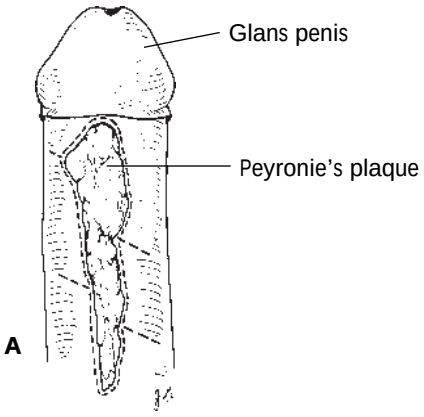

25-9

Primary Closure After Excision of Plaque

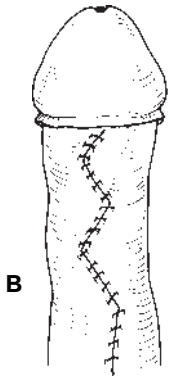

Incision with Graft Replacement

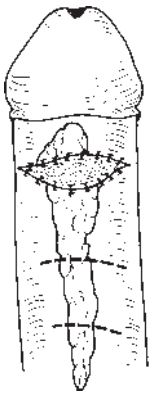

25-10

Excision with Graft Replacement

FIG. 25-11. If plaque excision leaves a large gap or even if an incision of the Peyronie's plaque results in a prominent gap, the surgeon has the option of using organic or inorganic graft substitutes:

Organic grafts, cadaveric dura[1,3-9]

1 Tunica albuginea
2 Dermis
3 Venous endothelium

Inorganic grafts

1 Dacron
2 Gore-Tex

The graft should first be approximated to one side of the penile defect and then the redundant area of the graft should be excised to create a good fit. Large grafts with redundancy can lead to aneurysm and impotence.

After completion of the graft interposition, the surgeon should infuse saline solution into the corporeal bodies to check for anastomotic suture line leakages. The dorsal nerves and vessels are replaced and the skin is reapproximated.

Placement of a Foley catheter (14 Fr) into the bladder avoids the discomfort of urinary difficulty. An ice pack over the penis and scrotum prevents excessive edema.

Terbutaline (5 mg) every 6 hours postoperatively prevents spontaneous nocturnal penile erection.

Graft Replacement

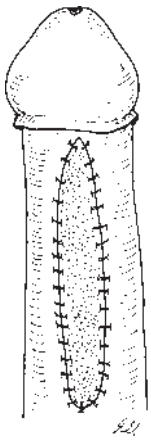

25-11

PEYRONIE'S DISEASE WITH IMPOTENCE

Placement of Semirigid Prosthesis

Each corpus cavernosum should be dilated with Hegar size 7 to 13 dilators.

While dilating the corporeal bodies, the surgeon may take this opportunity to not only create an open channel within each side but also disrupt the dense plaque on the tunica surface by a "cracking" manipulation.[10]

After placement of the correct semirigid prosthesis, the curvature is corrected in the majority of patients.

An additional plication stitch on the opposite side and/or an incision across the Peyronie's plaque may be necessary to eliminate the residual curvatures.[11]

Placement of Inflatable Penile Prosthesis

We prefer to use nonexpandable cylinders such as the CX model by American Medical Systems in cases of Peyronie's disease. Expandable cylinders conform to and even exaggerate the curvature.

After the cylinders are placed in the corpora cavernosa, the surgeon inflates the cylinders and inspects to see if the curvature is persistent. If it is, then electrocautery is used to incise across the Peyronie's plaque and expose part of the cylinder within.

FIG. 25-12. Incisions of 1 to 1.5 cm across the plaque are usually sufficient to correct the curvature[11,12] **(A).**

An alternative is to excise the plaque and replace the gap with a graft. Both organic and inorganic grafts are used, such as Gore-Tex, Dacron, Dexon mesh, tunica albuginea, cadaveric dura, and saphenous vein[1,3-9] **(B).**

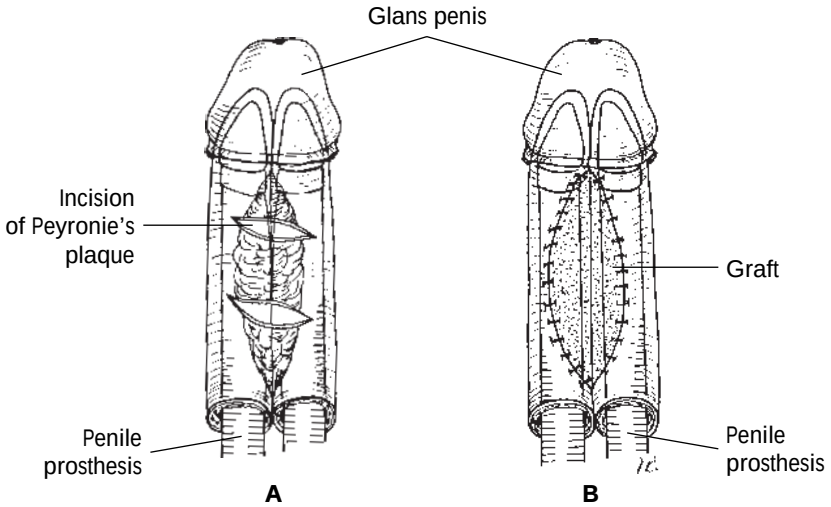

25-12

KEY POINTS

PEYRONIE'S DISEASE WITHOUT IMPOTENCE

- Exposure is gained via a circumferential or vertical incision.
- An artificial erection is induced.
- Saline solution is injected to separate the dorsal nerves from the corporeal bodies.
- The boundary of the plaque is identified and excised with maximal sinus preservation and preservation of the cavernosal artery.
- In cases of severe midline septal plaque formation, the surgeon must preserve the cavernosal artery within each corporeal body to preserve potency.
- Z-plasty closure of the residual corpus cavernosum is performed.
- If the excision or incision results in a defect that is too large for primary closure, a synthetic or organic graft should be used to cover it.
- Terbutaline is administered to prevent nocturnal erection and a Foley catheter is inserted to prevent urinary retention.
- An ice pack applied to the groin area reduces edema.

PEYRONIE'S DISEASE WITH IMPOTENCE

- Dilatation of the corporeal bodies with Hegar size 7 to 13 dilators with manipulation and "cracking" of the plaque is performed.
- The cylinders are placed. For a semirigid prosthesis, it may be necessary to take an additional plication stitch and/or incise across the plaque. For an inflatable prosthesis, we prefer the nonexpandable type of cylinders.
- If excision is necessary to remove dense fibrotic tissue, the gap may need to be replaced with either an inorganic or organic graft.

POTENTIAL PROBLEMS

- *The plaque is much larger than expected:* Consider plaque incision with a patch graft
- *Tear or division of some dorsal nerves:* Continue the procedure and preserve the rest of the dorsal nerves as much as possible
- *Plaque is higher than expected:* Divide plaque at the penis base
- *Injury of corporeal cavernosal arteries on one side:* Continue if the contralateral side is intact → consider prosthesis insertion if *permission* has been obtained
- *Urethral injury:* Close the urethral injury → continue the procedure with primary closure of the Peyronie's defect rather than the use of a replacement graft (especially an inorganic graft) → perform antibiotic irrigation of the surgical wound and administer intravenous antibiotics in the postoperative period

REFERENCES

1 Fishman IJ: Complicated implantations of inflatable penile prostheses, *Urol Clin North Am* 14(1):217, 1987.
2 Karacaoğlan N, Uysal A: The seven flap-plasty, *Br J Plast Surg* 47:372, 1994.
3 Carrier S, Lue TL: For Peyronie's disease, act conservatively, *Contemp Urol* 54, 1994.
4 Fallon B: Cadaveric dura mater graft for correction of penile curvature in Peyronie disease, *Urology* 35(2):127, 1990.
5 Devine CJ Jr, Horton CE: Surgical treatment of Peyronie's disease with a dermal graft, *J Urol* 111:44, 1974.
6 Horton CE, Sadove RC, Devine DR Jr: Peyronie's disease, *Ann Plast Surg* 18:122, 1987.
7 Essed E, Schroeder FH: New surgical treatment for Peyronie disease, *Urology* 25:582, 1985.
8 Gangai MP, Rivera LR, Spence CR: Peyronie's plaque: excision and graft versus incision and stent, *J Urol* 127:55, 1982.
9 Das S, Amar AD: Peyronie's disease: excisions of the plaque and grafting with tunica vaginalis, *Urol Clin North Am* 9(1):197, 1982.
10 Wilson SK, Delk JR II: A new treatment for Peyronie's disease: modeling the penis over an inflatable penile prosthesis, *J Urol* 152:1121, 1994.
11 Mulcahy JS: The management of complications of penile implants, *Prob Urol* 5(4):608, 1991.
12 Fishman IJ: Corporeal reconstruction procedures for complicated penile implants, *Urol Clin North Am* 16(1):73, 1989.

SUGGESTED READINGS

Cohen ES, Schmidt JD, Parsons CL: Peyronie's disease: surgical experience and presentation of a proximal approach, *J Urol* 142:740, 1989.

Malloy TR, Wein AJ, Carpiniello VL: Advanced Peyronie disease treated with the inflatable penile prosthesis, *J Urol* 125:327, 1981.

Miller HC, Ardizzone J: Peyronie disease treated with ultrasound and hydrocortisone, *Urology* 21(6):584, 1983.

ADDITIONAL PROCEDURES 26

RETROPERITONEAL FIBROSIS: INTERPOSITION OF PERITONEAL FLAP POSTERIOR TO URETER

To interpose peritoneum posterior to the ureter, we recommend creating two wide, large flaps of parietal peritoneum.

FIGS. 26-1 AND 26-2. Most surgical texts illustrate a neatly placed, slightly curved ureter lateral to the colon with the posterior parietal peritoneum interposed behind it. However, this procedure can actually be very difficult. The intraperitonealized ureters may be under such extreme stretch and tension with lateral deviation that there is potential for obstruction and ischemia.

Lysis of Fibrosis Around Ureter and Biopsy of Retroperitoneum

Cystoscopy for ureteral stent placement should be performed first. If not possible, the stents should be placed later when the ureter is exposed.

By dividing the lateral parietal peritoneum, the surgeon can locate the fibrosis around the ureter.

We prefer *not* to incise on the line of Toldt along the lateral border to the colon but to make an *exaggerated flap* from the anterior peritoneal surface all the way to the border of the colon. This technique is discussed later in this chapter because it facilitates flap interposition without excessive lateral stretching and angulation of the ureter.

The incision on the right side can be carried around the cecum and along the root of the mesentery to the ligament of Treitz. This incision provides access to the retroperitoneum by reflecting the right colon and small bowel medially and superiorly.

The surgeon should start the dissection in the area with the least fibrosis around the ureter and move toward the area of dense fibrosis.

Usually the most difficult area of dissection is the lower half of the ureter.

If the gonadal vessels are in the way of the dissection, they should be divided.

The fibrosis packs the great vessels and the ureter close together. Because of the density of the fibrosis, the surgeon may have difficulty estimating the depth of the great vessels.

The surgeon should be especially cautious during the biopsy of the retroperitoneum because inadvertent punctures of the vena cava and aorta can occur.

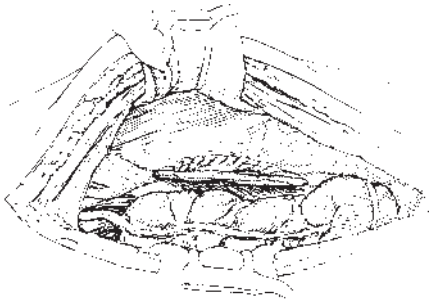

From Hinman F Jr, editor: *Atlas of urologic surgery,* Philadelphia, 1989, WB Saunders.

26-2

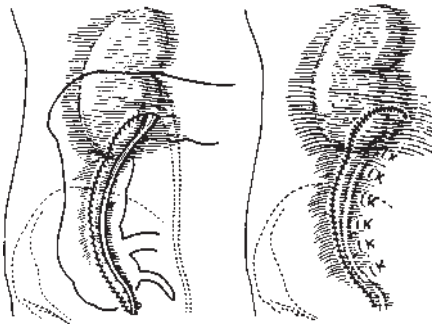

From Greenstein A, Smith MJV, Koontz WW Jr: Surgery of the ureter. In Walsh PC et al, editors: *Campbell's urology,* ed 6, Philadelphia, 1992, WB Saunders.

26-1

The surgeon should be mentally prepared to accept an indefinite diagnosis even after multiple biopsies and to proceed with surgery.

FIG. 26-3. We prefer to use a wide peritoneal flap of *anterior and posterior parietal peritoneum*. The cross-sectional view shows the incision of the anterior parietal peritoneum for the flap.

On the *right side,* the incision should extend from slightly below the level of the cecum up to the hepatic flexure of the transverse colon.

On the *left side,* the incision should extend from the level of the sigmoid colon up to the level of the splenic flexure.

This flap of anterior and posterior parietal peritoneum should be wider on the two ends since ureteral angulation is most prominent in the upper and lower segments.

When creating these two lateral flaps, the surgeon should maintain the full thickness of the peritoneum by preserving the adventitial tissue on the peritoneum.

It is better to take too much rather than too little of the anterior peritoneum for the flap.

As the surgeon places the peritoneal flap behind the ureters, it will become obvious that the maximal angulation and lateral deviation are at the uppermost and lowermost ureteral segments.

FIG. 26-4. With these wide peritoneal flaps, the surgeon can intraperitonealize the ureters without stretching them.

The ureter will be positioned toward the midline and even slightly behind the lateral border of the colon. With this maneuver one would still see residual lateral deviation on radiologic examination but without physiologic obstruction.

The incised parietal peritoneum from the cecum to the ligament of Treitz should be reapproximated, and the omentum should be placed anteriorly to cover the denuded peritoneal surface.

Cross-sectional View of Abdomen and Peritoneum

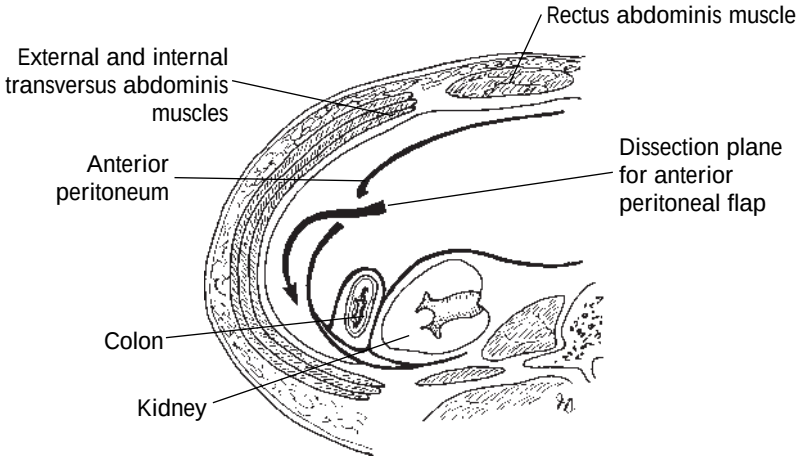

26-3

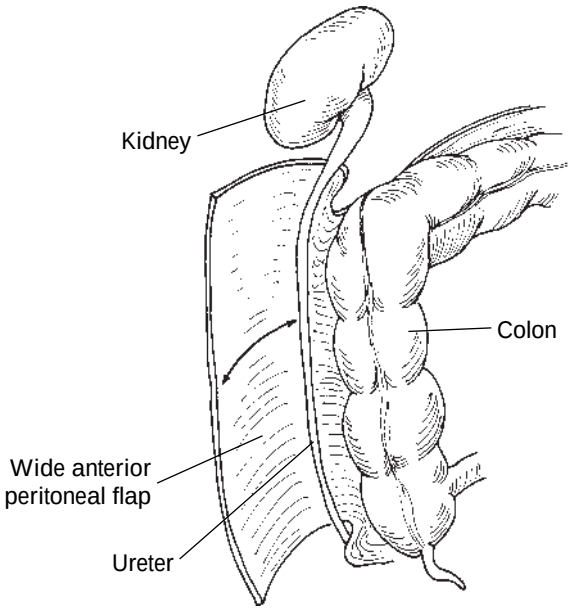

26-4

KEY POINTS

- An anterior flap incision is made in the parietal peritoneum.
- The fibrosis around the ureters is lysed and the ureters are mobilized as much as possible.
- If in the way, the gonadal vessels are divided.
- A biopsy of the retroperitoneum is obtained away from the vena cava.
- A flap or tongue of parietal peritoneum is placed posterior to the ureters as an interposition flap.
- The lowermost and uppermost parts of the ureter require the most redundancy of the flap in order to avoid severe angulation or lateral deviation of the ureter.
- Double-J stents or diversionary stents are placed in the ureters.

POTENTIAL PROBLEMS

- *Ureteral tear:* Place stents in the ureter and drain around the area
- *Vena cava puncture during biopsy of retroperitoneum:* Perform manual compression → apply Surgicel with Avitene sandwich and wait → use the Teflon felt pledget sandwiching technique (see p. 25)
- *Parietal peritoneal flap is insufficient in size, causing severe ureteral angulation:* Use alternative method of omental wrap around the ureter

VASOVASOSTOMY

The vas deferens is isolated and delivered out of the wound, and the obstruction site is identified and excised.

The surgeon must transect the healthy vas deferens in one smooth motion rather than a "sawing" motion, which results in a shingled surface. As much healthy vas deferens as possible is preserved.

We express fluid from the cut distal end of the vas deferens to check for patency. Since there are rarely any sperm at the proximal end, we do not perform a sperm analysis.

Probing the lumen only ensures patency and is not used for dilatation. The surgeon can usually pass the probe several centimeters into the distal end but only a few millimeters into the proximal end. Further proximal probing may increase the risk of injury due to the convolutions of the vas deferens and of perforation through the lumen.

Vas Deferens Anastomosis

Key is the use of one-layer, full-thickness, interrupted stitches (double-arm 7-0 ophthalmic polyglycolic acid sutures). Each needle is placed in the lumen and brought out the vas deferens no more than 1 mm from the cut edge. All stitches are tied with a double-throw surgeon's knot as the first throw. We place a total of 12 to 16 stitches.

For better visualization of the vas deferens lumen, the surgeon will find 2.0× to 4.5× magnification lenses to be helpful.

The free ends of the vas deferens are initially held by the surgeon's fingers rather than vas clamps. After the initial stitches are placed and tied, it may be convenient to rest the vas deferens on small felt arrowhead sponges. Fluid from the proximal vas deferens is carefully repeatedly blotted from the wound. No drains or reinforcing sutures are needed. Patients are sent home the same day, and sex is permitted after release from the hospital.

FIG. 26-5. The most important maneuver is for the stitch needle to enter the luminal side through the muscularis and exit only 1 mm from the edge of the cut surface. The first six stitches are placed as closely as possible. After the first few stitches are tied, the lumen of the vas deferens actually opens wider for the subsequent stitches until approximately half of the closure is completed.

Surgeon's knots are used and tied on the adventitial side. The first six stitches are tied as they are placed, and the rest of the stitches are placed but left untied and tagged with small bulldog clamps.

After the seventh to the twelfth stitches are placed, the surgeon ties all sutures circumferentially.

- The vas deferens anastomosis opens up after one or two sutures are placed and tied. The opening then starts to narrow after about half of the stitches have been placed and tied.
- Before visualization of the vas deferens walls and lumen is lost due to narrowing of the vas deferens opening, the remaining sutures are placed, tagged with small bulldog clamps, and then tied after all have been positioned.
- No reinforcing sutures or drains are needed. The procedure is performed as outpatient surgery. The patient is informed that sex is permitted after release from the hospital.

KEY POINTS

- Double-armed (needle on each end) 7-0 ophthalmic polyglycolic acid sutures are placed.
- For each stitch a double-throw surgeon's knot is used on the first throw.
- Vas clamps are not used because they injure the wall of the vas deferens.
- Each stitch is placed by passing the needle into the lumen and then rotating the needle out through the musculature no more than 1 mm away from the cut edge. The needle on the other end of the same stitch is passed into and through the other segment of the vas deferens in an identical fashion.

POTENTIAL PROBLEMS

- *Difficulty finding vasa deferentia:* Deliver the testis out of the wound
- *Gap between two ends is too wide:* Mobilize the testis to shorten the gap
- *Torn edges on suture line:* Recut for fresh, clean vas edges and restart the stitch placement
- *Crossed-up stitches:* Restart stitch placement after removing crossed stitches
- *Anastomosis closes too much and obscures rest of stitch placement:* Cut a few stitches out and replace without tying them until stitch placement is completed

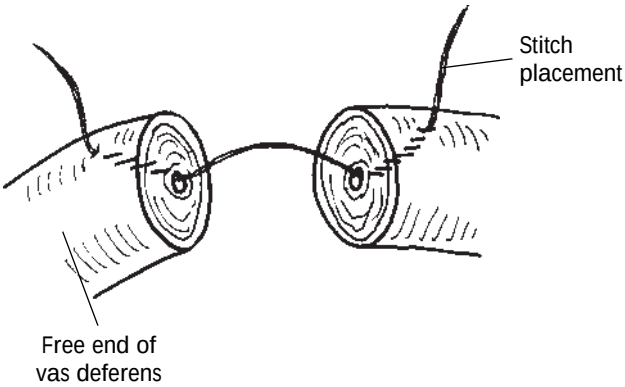

Cross Section of Completed Anastomosis

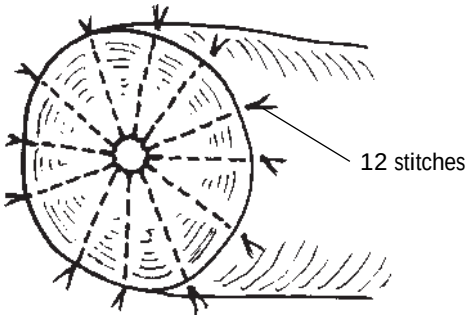

External View at Completion

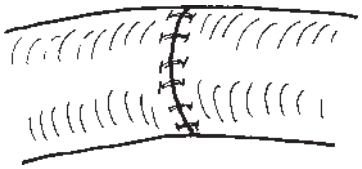

26-5

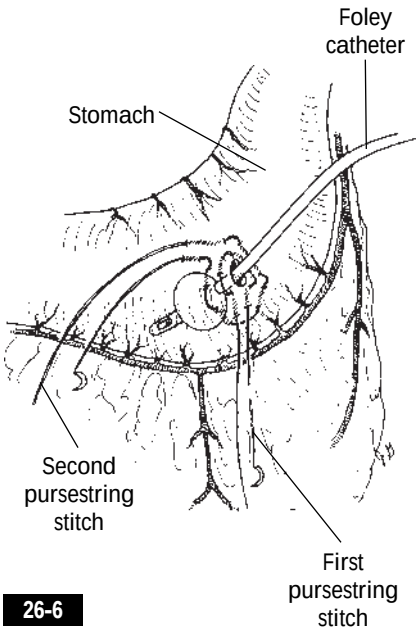

26-6

GASTROSTOMY TUBE PLACEMENT

Gastrostomy tube placement postoperatively is extremely useful for patients who have undergone extensive urologic surgery such as ileoneobladder or continent pouch with cystectomy. During the postoperative period of bowel ileus, the patients not only are more comfortable but also can perform pulmonary toilet more vigorously without a nasogastric tube.

The simplest technique is to pass a Foley catheter or Malecot catheter (22 to 24 Fr) from the desired skin position via a separate stab wound into the peritoneal cavity.

Two Babcock clamps are placed on the stomach, and a puncture is made in between for catheter insertion.

FIG. 26-6. The two rows of pursestring stitches (0 silk) are placed around the catheter and Babcock clamps. The clamps are removed and the pursestring stitches are tied with the needles left in place.

When the stomach is positioned close to the abdominal wall, the surgeon uses the same two stitches for fixation against the abdominal wall.

On the skin, another fixation stitch (0 silk) is placed adjacent to the catheter.

A nasogastric tube should be inserted and left in place for the first 24 hours postoperatively because the gastrostomy tube does not function well in the immediate postoperative period.

BLADDER DIVERTICULECTOMY

No matter how large the diverticulum, the intravesical approach for bladder diverticulectomy is the simplest and easiest approach.

FIG. 26-7. After the bladder is opened, traction stitches (0 silk) are placed around the lateral and inferior margins of the cystotomy **(A).**

Placement of a self-retaining retractor will keep the bladder incision wide open.

Four stitches (2-0 silk) are placed around the mouth of the diverticulum. These stitches should be well secured and be positioned 1 cm from the mouth.

With cephalad traction, an incision is made lateral to the traction stitches. With forceps countertraction by the assistant, the surgeon can now cut and spread the tissues to define the correct plane for the diverticulum.

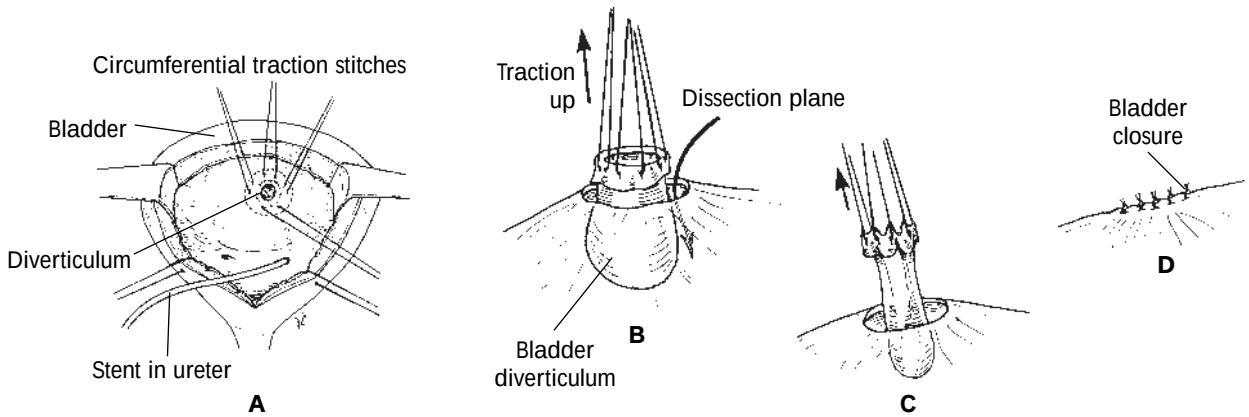

26-7

Once this plane is established, the use of blunt and sharp dissection with Kitners (tonsil clamp with ball of gauze) and scissors should easily separate the adventitia from the diverticulum (**B** and **C**).

If excising a Hutch diverticulum adjacent to the ureter, the surgeon can place a ureteral stent and palpate it as the dissection progresses.

After the diverticulum is completely excised and removed, reapproximation should be performed in two layers even if the wall is thin **(D).** Most of the time, it is difficult to find the muscularis layer around the edges of the diverticular mouth. However, by undermining the bladder wall, the surgeon will locate the muscularis for the two layers of closure. If the diverticulum is a Hutch diverticulum, the surgeon must not incorporate the ureter in the closure.

A Malecot catheter (22 Fr) is used as a suprapubic catheter and is brought out through a separate stab wound. A drain is left in the perivesical spaces.

With the patient in a supine position, dependent urine in the bladder may not be properly drained on the first postoperative night. Therefore a Foley catheter is left in place for 24 hours postoperatively.

KEY POINTS

- Exposure of the bladder is obtained with the placement of traction stitches and a Balfour retractor blade.
- Traction stitches are placed around the mouth of the diverticulum.
- In the case of a Hutch diverticulum, a stent is placed in the ipsilateral ureter.
- A circumferential incision is made lateral to the traction sutures.
- The dissection plane is defined with scissors (using more of a spreading than a cutting motion) while countertraction is applied on the bladder side.
- Once a dissection plane is established adjacent to the diverticulum, blunt dissection using Kitners is performed along the plane.
- The defect is closed in two layers.
- A suprapubic tube, drain, and Foley catheter are placed.

POTENTIAL PROBLEMS

- *Diverticular tear occurs during excision of diverticulum:* Place more traction stitches or apply an Allis clamp along the torn wall

INTRAVESICAL OR EXTRAVESICAL URETERAL DISSECTION

FIG. 26-8. Excellent exposure for ureteral dissection is obtained with the placement of a malleable blade fixed to a Balfour retractor cephalad over four sponges positioned within the bladder.

As for ureteral reimplantation for vesicoureteral reflux, the surgeon frees the ureter from the vesical wall. With a red rubber catheter (6 Fr) inserted 10 cm up into the ureter, the surgeon anchors the ureteral meatus to the catheter. The catheter will be used to apply traction cephalad.

FIG. 26-9. A 1 cm circumferential incision is made around the ureteral orifice **(A),** and the surgeon uses sharp dissection to define a plane between the ureter and the bladder wall.

With forceps countertraction applied by the assistant, the surgeon can circumferentially free the ureter **(B).** In a medial position to the ureter, the peritoneal reflection should be swept off using gentle blunt dissection with the Kitners **(C).**

Once the hiatus of the vesical wall is dissected from the ureter, the ureter can be passed external to the bladder wall.

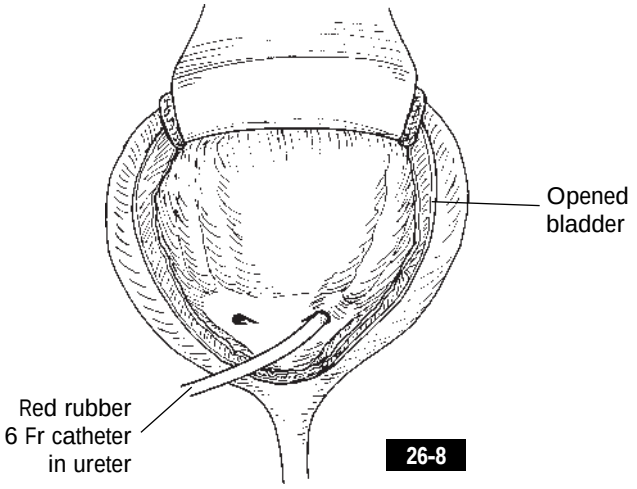

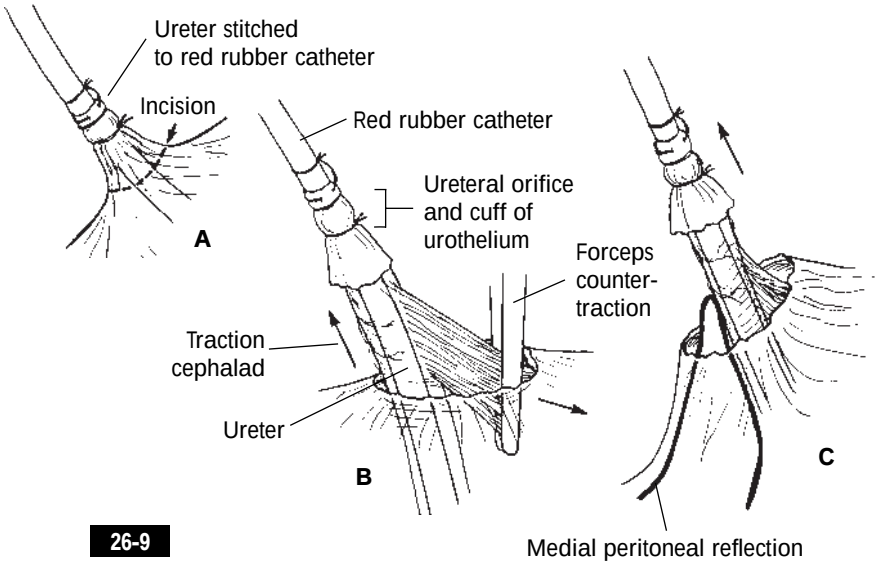

FIG. 26-10. The bladder defect is closed in the standard two-layer fashion with 2-0 absorbable stitches.

FIG. 26-11. Via the retroperitoneal pocket, the proximal ureter is isolated for the complete ureteral excision.

A web of tissues containing the complex of the obliterated umbilical artery and superior vesical artery separates the proximal ureter from the freed distal ureteral orifice.

Using sharp fine scissors, the surgeon can feel the red rubber catheter within the ureter and can dissect a plane to free the ureter all the way through the web of tissues. If the dissection is difficult, the surgeon can ligate and divide this web of tissues without the risk of additional complications.

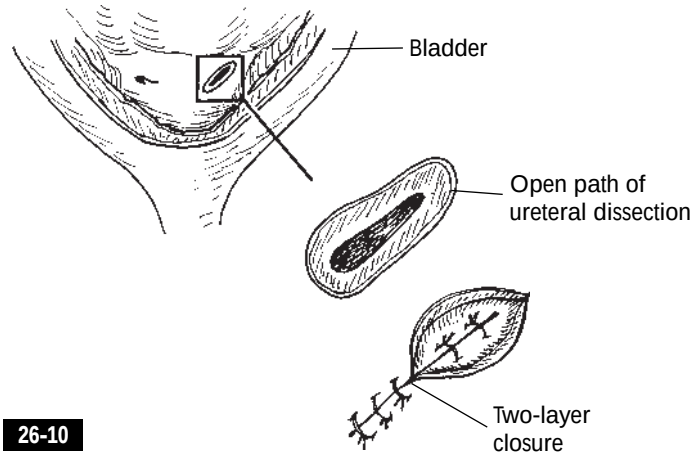

26-10

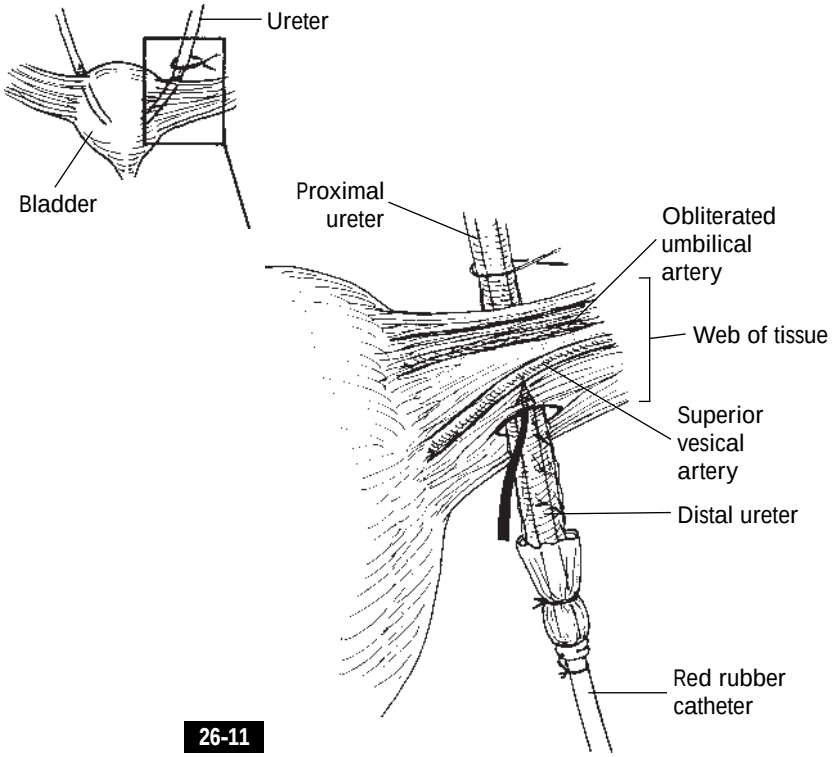

26-11

SUGGESTED READINGS

Greenstein A, Smith MJV, Koontz WW: Surgery of the ureter. In Walsh PC et al, editors: *Campbell's urology*, vol 3, ed 6, Philadelphia, WB Saunders, 1992, pp 2556-2557.

Hinman F Jr: Ureterolysis. In *Atlas of urologic surgery*, Philadelphia, WB Saunders, 1989, pp 677-678.